

ORIGINAL ARTICLES

FREQUENCY OF BONE EROSION ON COMPUTERIZED TOMOGRAPHY SCAN IN ALLERGIC FUNGAL RHINOSINUSITIS

Muhammad Ali, Saima Attiq*, Sayed Nusrat Raza*, Abdul Hakim, Shakeel Ahmed, Shaukat Ali, Farhan Akbar, Syed Waqar Abbas

Combined Military Hospital/National University of Medical Sciences (NUMS) Rawalpindi Pakistan, *Army Medical College/National University of Medical Sciences (NUMS) Rawalpindi Pakistan

ABSTRACT

Objective: To analyze the frequency and sites of bone erosion on computerized tomography scan in Allergic Fungal Rhinosinusitis in Pakistan.

Study Design: Retrospective observational study.

Place and Duration of Study: Department of ENT, Combined Military Hospital Lahore, Malir Karachi and Rawalpindi, from Jan 2010 to Dec 2019.

Methodology: Total 230 cases of Allergic Fungal Rhinosinusitis were screened, out of which 85 patients having bone erosions on computerized tomography scan were included in the study. Bone erosion in different paranasal sinuses and their sub sites were evaluated. Depending upon the number of bone erosion, patients were divided into three categories as mild, moderate and severe. Those having erosion at a single site were labelled as mild, those with two sub sites of erosion as moderate and those with more than two subsites of erosion were labelled as severe cases.

Results: Detailed evaluation of computerized tomography scan of paranasal sinuses revealed bone erosion in 85/230 (36.9%) cases. Mean affected age was 23.96 ± 12.71 years. There were 52 (61.1%) males and 33 (38.9%) females. Ethmoid sinus was the most commonly involved sinus to have bone erosions 55 (38.19%) followed by maxillary sinus 38 (26.38%) then sphenoid sinus 27 (18.75%) and lastly frontal sinus 24 (16.6%). Out of 85 patients 48 (56.1%) were having mild, 22 (25.8%) moderate and 15 (17.6%) had severe disease.

Conclusion: Allergic Fungal Rhinosinusitis has high frequency of bone erosion. Computerized tomography scan is an important and effective investigation in finding these bony erosions and ethmoid sinus is the commonest site of bone erosion among paranasal sinuses.

Keywords: Allergic bronchopulmonary, Aspergillosis, Bone erosion, Sinusitis.

How to Cite This Article: Ali M, Attiq S, Raza SN, Hakim A, Ahmed S, Ali S, Akbar F, Abbas SW. Frequency of Bone Erosion on Computerized Tomography Scan in Allergic Fungal Rhinosinusitis. *Pak Armed Forces Med J* 2021; 71 (Suppl-3): S428-431. Doi: <https://doi.org/10.51253/pafmj.v1i1.4159>

This is an Open Access article distributed under the terms of the Creative Commons Attribution License (<https://creativecommons.org/licenses/by-nc/4.0/>), which permits unrestricted use, distribution, and reproduction in any medium, provided the original work is properly cited.

INTRODUCTION

There are more than 400,000 known fungal species out of which approximately 400 are human pathogens.¹ The role of fungi in nose and paranasal sinuses is unclear. Although fungi can be cultured from the nasal secretions of even a healthy individual but certain forms of fungal infections in humans are associated with a high rate of mortality.²

Allergic Fungal Rhinosinusitis (AFRS) is a distinct type of chronic rhinosinusitis which affects immunocompetent hosts in contrast to invasive fungal infection. Majority of the patients have history of allergic rhinitis and it is believed to be an allergic reaction to aerosolized environmental fungi, usually of the dematiaceous species, bipolaris (*Curvularia*, *Alternaria*) and rarely *Aspergillus*.³ It is characterized by the formation of nasal polyps, accumulation of eosinophilic mucus and fungal hyphae within the nasal cavity and sinuses,

a Gell and Coombs type I hypersensitivity reaction to fungi are pathognomonic CT findings.

The pathogenesis starts when an atopic host typically inhales fungal allergens and an IgE-mediated response ensues with resultant sinonasal inflammation leading to oedema, sinus obstruction and stasis. The end stage of this chronic inflammation leads to formation of nasal polyp and mucus accumulation. Trapped fungi continue to stimulate the immune system and a vicious cycle is set up causing bone expansion/erosion with distortion of sinonasal anatomy.³

Presence of bone erosion in AFRS is a known entity and commonly involves the base of skull and the orbit. Its frequency varies from one geographical area to another ranging from 20-90%.^{4,7} Bone erosion is caused by bone remodeling and pressure necrosis.⁴

CT scan has an important role in its diagnosis. Non contrast CT scan demonstrates opacification of involved sinuses, with central hyperattenuation because of collection of certain metals like Iron, magnesium

Correspondence: Dr Muhammad Ali, Classified ENT Specialist, Combined Military Hospital Rawalpindi Pakistan

and manganese concentrated by fungal organism.¹ Moreover bone erosion, another feature currently incorporated in the minor criteria for the diagnosis is also transcendently detected by CT scan.^{5,8}

Our study was aimed to identify frequency of bone erosions of different sinuses and their subsites visible on CT scan in AFRS. Management of AFS is multipronged involving medical as well as surgical intervention. Functional endoscopic sinus surgery has potential life threatening complications especially when bony boundaries are dehiscent. Hence, a comprehensive study of CT scan by identifying areas of bone erosions and assessment of disease severity is an essential prerequisite for a safe and effective surgical treatment.

METHODOLOGY

It is a retrospective observational study carried out in Combined Military Hospitals of Lahore, Malir Karachi and Rawalpindi which was started in January 2010 to December 2019. After approval of hospital ethics committee vide approval no 04/04/60/20 dated 24th April 2020, total 230 patients of Allergic Fungal Rhinosinusitis meeting criteria of Bent and Swain were enrolled by convenience sampling and 85 patients who were having bone erosions on CT scan were included in this study. Patients of all age group and either gender were included in this study. Immunocompromised, patients with diabetics, those using drugs effecting immunity (antibiotics, steroids and immunospressive drugs) and patient of sinonasal tumours were excluded in this study.

All patients were investigated preoperatively by CT scan of paranasal sinuses without contrast. Three views of coronal, axial and sagittal sections were taken and interpreted by a qualified radiologist with special emphasis on areas of bone erosions and soft tissue extensions. All sinuses are further divided in to its subsites (Table-III). MRI was done in patients with doubtful diagnosis, soft tissue or intracranial extension or suspicion of tumor.

CT Scans were evaluated for its characteristic findings of AFRS having unilateral or bilateral opacification of multiple sinuses along with central hyperattenuation, double density shadows, sinus mucocole formation and expansion of sinuses. Intrasinus hyperattenuation is a characteristic of AFRS and is taken as its diagnostic criteria. Frequency of bone erosion of different sub sites of sinuses as well as commonest sinus effected was evaluated. Depending upon the number of bone erosions, patients were divided in to three categories as mild, moderate and severe. Those having

erosion at a single site were labelled as mild, those with two sub sites of erosion as moderate and those with more than two subsites of erosions were labelled as severe cases.

RESULTS

Out of 230 cases of AFRS, 85 patients having Allergic fungal rhinosinusitis with bone erosion on CT scan were selected in our study. Frequency of bone erosion was seen in 36.9% of cases of AFRS. In 85 patients mean age of disease with bone erosion was 23.96 ± SD 12.71 years. Out of 85 patients there were 52 (61.1%) male and 33 (38.9%) female patients. Bilateral disease was found in 74 (87%) patients and unilateral disease was seen in 11 (13%) cases. In unilateral cases 5 (5.88%) were having right sided while 6 (7.05%) had only left sided disease (Figure).

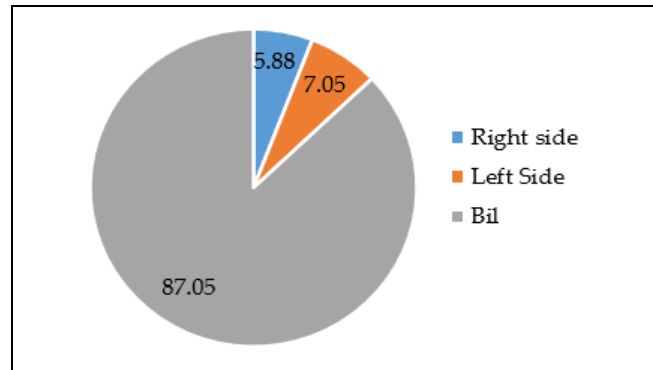


Figure: Laterality of the disease.

Out of 85 patients 48 (56.1%) patients were having bone erosion at one subsite of a sinus and labelled as having mild disease, while 22 (25.8%) were having bone erosions at two subsites of sinuses making them as cases of moderate disease. There were 15 (17.6%) patients who having severe disease because of bone erosions at more than two subsites. So a total 144 erosions were seen in these 85 patients (Table-I).

Table-I: Severity of disease based on number of bone erosions (n=85).

Severity	Frequency (n=85)	Cumulative No. of Bone Erosions
Mild (Only one subsite eroded)	48 (56.4%)	48
Moderate (Two Subsites eroded)	22 (25.8%)	44
Severe (More than two subsites eroded)	15 (17.6%)	52
Total	85	144

Out of 15 severe cases 10 (66.6%) were having bone erosions at three subsites while 03 (20%) patients were having at 04 subsites and 02 (13.3%) were having

bone erosions at 05 subsites of different sinuses (Table-II).

Table- II: Breakdown of cases with severe disease having multiple bone erosions (n=15).

No. of Cases	No. of Bone Erosion in Each Case	Total No. of Erosions (n=52)
10	3	30 (66.6%)
3	4	12 (20%)
2	5	10 (13.33%)

We also found that ethmoid sinus was commonest sinus 55 (38.19%) to have bone erosions In ethmoid sinus lamina paprycea had the highest frequency 35 (24.3%) of bone erosion. Maxillary sinus had 38 (26.38%) bone erosion and its roof was the commonest site with 12 (8.3%) of involvement in our study. Sphenoid sinus had 26 (18.75%) and frontal sinus 24 (16.6%) out of all bone erosions. Further breakdown of involvement of different subsites is mentioned in (Table-III).

Table-III: Bone erosion involving different site and subsites. Descriptive statistics (n=144).

Primary Site (Sinus)	Subsite	n (%)	Cumulative n (%)
Ethmoid Sinus	Lamina Paprycea	35 (24.30)	55 (38.19)
	Roof of Ethmoid	20 (13.88)	
Frontal Sinus	Ant Wall	4 (2.77)	24 (16.66)
	Post Wall	8 (5.55)	
	Floor	12 (8.33)	
Sphenoid Sinus	Planum	10 (6.94)	27 (18.75)
	Post Wall	06 (4.16)	
	Lat Wall	08 (5.55)	
	Clivus	03 (2.08)	
Maxillary Sinus	Roof	12 (8.33)	38 (26.38)
	Ant Wall	10 (6.94)	
	Post Wall	10 (6.94)	
	Lat Wall	6 (4.16)	

48 Patients had one subsite erosion, 22 Patients had two subsites erosion, 15 Patients had multiple erosions >2Subsites

DISCUSSION

Allergic fungal rhinosinusitis (AFS) is a different type of chronic rhinosinusitis which affects immunocompetent hosts as compared to invasive fungal infection. Most of the patients have allergic rhinitis but it is because of aerosolized fungi.⁶ It is characterized by the formation of nasal polyps, collection of eosinophilic mucin in involved sinus and almost pathognomonic CT findings.⁷ It is a disease of the young people with a mean affected age of 21.9 ± 10.6 years and both sex are equally affected.

Historically Bent and Kuhn in 1994 delineated the most widely accepted criteria for the diagnosis of AFS which included five common characteristics namely

Gell and Coombs type I (IgE-mediated) hypersensitivity to fungi, nasal polyposis, characteristic radiographic findings, eosinophilic mucin without fungal invasion into sinus tissue, and positive fungal stain of sinus contents removed at the time of surgery.^{1,15} Later in 2003 Swain modified this criteria dividing it into major and minor criteria for the diagnosis of AFRS.³

Presence of bone erosion in AFRS is a known entity and commonly involves the base of skull and the orbit. Its frequency varies from one geographical area to another ranging from 20-90%.⁵ Bone erosion is caused by bone remodeling and pressure necrosis.¹

High resolution CT scan without contrast is an investigation of choice in identification of bone erosions in paranasal sinuses and must be done in every case of AFRS. It not only identifies extent of disease but also helps in diagnosis of fungus by typical appearance of double density shadow in involved sinuses.^{8,9}

Treatment of this condition is medical as well as surgical. Corticosteroids are given preoperatively and postoperatively to reduce inflammatory/allergic response which in turn helps to control peroperative bleeding and recurrence.^{10,11} The goal of primary and revision surgery is the removal of mechanical obstruction, clearance of sinus contents and establishment of adequate outflow tracts while maintaining mucociliary function.¹²

Identification of areas of bone erosion through recognition of defects,¹² in base of the skull and orbit is very important prior to surgery in order to prevent serious complications. Hence the aim of our study was to have a detailed interpretation of CT scan along with evaluation of the frequency of bone erosion and its commonest site.

We screened 230 cases of AFRS and found that 85 (36.9%) patients had bone erosion on CT scan. According to Tanveer 13 its frequency varies from 20-90% and was about 40% in our country as per our study. AFRS is claimed to be a disease of hot and humid weather, but Mulhem¹⁴ from Saudia has documented only 20% frequency of bone erosion in AFRS.

As per our study the mean affected age was 23.9 ± 12.7 years which is comparable to other studies.¹⁵⁻¹⁷ Moreover our study revealed that bone erosion is mostly seen in males as out of the 85 affected patients there were 52 (61.1%) male and 33 (38.9%) female patients. Male predominance is published by Ghegan,¹⁸ who has documented 56% frequency of bone erosion in AFRS and African American males are found to be 15

times more affected than Caucasians and African American females combined.

In our study we found that ethmoid sinus was the most commonly involved sinus 38.19% followed by maxillary sinus (26.38%), then sphenoid sinus (18.75%) and last frontal sinus (16.6%). This is also comparable to other studies like the one conducted by Loftus and Wise,¹⁹ who document the frequency of bone erosion to be 77% in Ethmoid sinus, 68% in Maxillary Sinus, 58% in Sphenoid and 53% in frontal sinus.

We also found that in Ethmoid sinus lamina papyrcea was the commonest site of erosion (24.3%) attributed to its thin structure and narrow area which is akin to various other studies.²⁰⁻²²

Wise and Ghegan,²³ presented a CT scan based scoring system to objectively classify staging of disease but that also does not address the clinical course, propensity of recurrence and degree of systemic allergy. They proposed a,²⁴ point based criteria and designated a specific number to each sinus. Scoring is done depending upon the bone erosion and expansion. They also related severity of disease with the number of erosions and expansion. Radiological staging carries important implication for development of potential complications of surgery and disease progression if not treated.

No matter whichever technique and scoring system is adopted in the radiological assessment of disease it has a pivotal role as it can be used by the otolaryngologist as well as a radiologist to stratify disease severity in cases of AFRS and assists in preoperative planning and avoidance of complications.²⁴

CONCLUSION

Allergic Fungal Rhinosinusitis has high frequency of bone erosion and CT scan is an essential, effective and reliable method of its evaluation before undergoing any surgical intervention. Among paranasal sinuses ethmoid sinus in area of lamina papyrcea has the highest frequency of bone erosion followed by maxillary sinus, sphenoid sinus and frontal sinus respectively. Idea of bone erosions and dehiscent bony walls will help in prevention of life threatening complications while doing Functional Endoscopic Sinus Surgery.

Conflict of Interest: None.

Authors' Contribution

MA: Conceptualization and data collection, SA: Data analysis, SNR: Conceptualization and proof reading, AH: Data collection, MS: Writing, SA: Literature search, FA: Proof reading, SWA: Literature search.

REFERENCES

1. Mark S, Dykewicz, Jonathan MR, Raymond GS. Allergic fungal rhinosinusitis. *J Allergy Clin Immunol* 2018; 142(2): 341-351.

2. Tyler MA, Luong AU. Current understanding of allergic fungal rhinosinusitis. *World J Otorhinolaryngol Head Neck Surg*. 2018; 4(3): 179-185
3. Daniller T. Allergic fungal rhinosinusitis. *Current Aller Clin Immunol* 2013; 26(1): 20-24.
4. Bakshi SS. Image diagnosis: Allergic fungal sinusitis. *Perm J* 2018; 22(4): 17-230.
5. Berlucchi M, Pedruzzi B. Allergic fungal sinusitis in children. *J Aller Ther* 2012; 2(1): S5-S8.
6. Thakare S, Vaidya D, Chaudhary A, Hazirnis K, Bhondawe S. Aggressive allergic fungal sinusitis managed completely by endoscopy. *J Evid Based Med Health* 2014; 1(7): 489-496.
7. Katragkou A, Fisher BT, Groll AH, Roilides E, Walsh TJ. Diagnostic imaging and invasive fungal diseases in children. *J Pediatr Infect Dis Soc* 2017; 6(suppl-1): S22-S31.
8. Vatin L, Vitte J, Radulesco T, Morvan J, Grande J, Varoquaux A, et al. New tools for preoperative diagnosis of allergic fungal sinusitis? a prospective study about 71 patients. *Clin Otolaryngol* 2019; 44(1): 91-96.
9. Bhanu BB, Gil IJS, Singh T. The role of CT Scan and histopathology in diagnosis of allergic fungal sinusitis. *clinical rhinology: An Inter J* 2014; 7(3): 117-120.
10. Rupa V, Jacob M, Mathews MS, Seshadri MS. A prospective, randomised, placebo-controlled trial of postoperative oral steroid in allergic fungal sinusitis. *Eur Arch Otorhinolaryngol* 2010; 267(2): 233-238.
11. Alajmi S, Khartum RM, Khan Z, Ahmed S, Jergah A, Ibrahim H, et al. Allergic fungal sinusitis caused by *exserohilumrostratum* and literature review. *Mycopathol* 2019; 184(1): 89-96.
12. Zakirullah, Nawaz G. Presentation and diagnosis of Allergic Fungal Sinusitis. *J Ayub Med Coll Abbott* 2010; 22(1): 53-57.
13. Tanveer U, Gul A, Aqil S. Incidence and recurrence of allergic fungal sinusitis at tertiary care facility. *Ind J Otolaryngol Head Neck Surg* 2019; 71(Suppl-3): 1832-1836.
14. Mulhem N, Momen AA, Almolani F. The different clinical presentations of allergic fungal rhinosinusitis. *Otolaryngol Open Access J* 2018; 3(2): 000172.
15. Thorp BD, McKinney KA, Rose AS. Allergic fungal sinusitis in children. *Otolaryngol Clin North Am* 2012; 45(3): 631-642.
16. Rowan NR, Janz TA, Schiosser RJ, Soler ZM. Radiographic nuances in allergic fungal rhinosinusitis. *Am J Rhinol Allergy* 2019; 33(3): 310-316.
17. Raz E, Win E, Hagiwara M, Lui YW, Cohen B, Fatterpekar GM. Fungal Sinusitis. *Neuroim Clin N Am* 2015; 25(4): 569-576.
18. Ghegan M, Lee, F, Schlosser R. Incidence of skull base and orbital erosion in allergic fungal rhinosinusitis (AFRS) and non AFRS. *Otolaryngol Head Neck Surg* 2006; 134(4): 592-595.
19. Loftus PA. Allergic fungal rhinosinusitis: the latest in diagnosis and management. *Adv Otorhinolaryngol* 2016; 79(2): 13-20.
20. Chakarbarti A, Kaur H. Allergic aspergillus rhinosinusitis. *J Fungi* 2016; 2(4): 32-35.
21. Rowan NR, Janz TA, Schlosser RJ, Soler ZM. Radiographic nuances in allergic fungal rhinosinusitis. *Am J Rhinol Allergy* 2019; 33(3): 310-316.
22. Alaraj AM, Al-Faky YA. Ophthalmic manifestations of allergic fungal sinusitis. *Ophthal Plast Reconstr Surg* 2018; 20(20): 1-4.
23. Wise SK, Rogers GA, Ghegan MD, Harvey RJ, Delgado JM. Radiologic staging system for allergic fungal rhinosinusitis (AFRS). *Otolaryngol Head Neck Surg* 2009; 140(5): 735-740.
24. Deosthale NV, Khadakkar SR, Harkare VV, Dhoke KS, Soni AJ, Katke AB. Diagnostic accuracy of nasal endoscopy as compared to computed tomography in chronic rhinosinusitis. *Indian J Otolaryngol Head Neck Surg* 2017; 69(4): 494-499.