

## URINARY DIVERSION IN HYPOSPADIAS REPAIR: SUPRAPUBIC CYSTOSTOMY VERSUS TRANSURETHRAL CATHETERIZATION

Shahzad Ahmad Qamar, Mudassar Saeed Pansota, Mumtaz Rasool, Shafqat Ali Tabassum, Muhammad Shahzad Saleem

Quaid-i-Azam Medical College / Bahawal Victoria Hospital, Bahawalpur

### ABSTRACT

**Objective:** To compare the results of suprapubic with transurethral urinary diversion in hypospadias repair.

**Data Source:** Patients admitted to the Department of Urology and Renal Transplantation with distal or middle hypospadias.

**Design of Study:** Randomized Controlled Trials.

**Setting:** Department of Urology and Renal Transplantation, Quaid-I-Azam Medical College /Bahawal Victoria Hospital, Bahawalpur.

**Period:** From June 2010 to December 2011.

**Materials and Methods:** A total of sixty patients, 1 to 10 years of age with distal or middle hypospadias were included in the study. Patients with history of previous hypospadias repair were excluded. Patients were divided in two groups by using random numbers table, 30 patients in each group. Group I had suprapubic and Group II had transurethral urinary diversion. Tubularized Incised Plate urethroplasty and Mathieu's repair were commonly used techniques. Stent was kept for 7-14 days. Patient discharged from hospital at 72 hours post-operatively with urethral catheter or suprapubic cystostomy intact. Patients were followed for subsequent outcome. Follow up was initially fortnightly and then at 1 month intervals. Minimum follow up period was 3 months and maximum 18 months for these particular patients.

**Results:** Only two patients of Group I had complications as compared to seven patients of Group II. Moreover, patient discomfort and voiding problems was more with group II than group I. Nursing care was easy in group I patients. Complication rate was significantly 10 where in group I as compared to group II.

**Conclusion:** The overall complication rate and patient discomfort were significantly lower with suprapubic urinary diversion in hypospadias repair, which also had a better cosmetic outcome.

**Keywords:** Urinary diversion, Suprapubic Cystostomy, Transurethral catheterization, Hypospadias repair, Outcome.

### INTRODUCTION

Hypospadias is an abnormal opening of external urethral meatus in male child at birth, and can be anywhere along the ventral side of shaft of the penis or perineum<sup>1</sup>. It is one of the common congenital anomalies occurring in approximately 1 in 200- 300 male live births.<sup>2</sup> Hypospadias are classified into Anterior (distal), Middle and Posterior (proximal) according to site of native meatus.<sup>3</sup> There are many surgical procedures for repair, and none of them is superior to the others. There have probably been over 200 reported original

methods of urethral reconstruction and they continue as modification of modifications.<sup>4</sup>

Temporary urinary diversion is routinely employed after hypospadias repairs. There are many techniques for urine drainage and some of them require prolonged hospital stay with discomfort to the child.<sup>5</sup> The prevention of urine from making contact with the repair site remains a major challenge because of the toxic effect it has on exposed raw tissues which results in cells death and subsequent fistula formation or complete breakdown of the repair.<sup>6</sup>

Different methods of urinary diversion and their associated complications after hypospadias repair have been described.<sup>6,7</sup> Many Pediatric urologists use either supra pubic or transurethral drainage to prevent

**Correspondence:** Dr. Shahzad Ahmad Qamar, Medical Officer/Post Graduate Resident, Bahawal Victoria Hospital, Bahawalpur.

Email: [netygeulis749@hotmail.com](mailto:netygeulis749@hotmail.com)

Received: 08 June 2012; Accepted: 26 Nov 2012

complications from urine leakage at the suture line which results in urethral stenosis or complete breakdown of the repair.<sup>8</sup> However, these methods of urinary diversion itself have many complications which effect the desired results. This necessitates the need to get a method of diversion or stenting that would give satisfactory urinary diversion and minimal complications after hypospadias repair.<sup>6</sup>

The purpose of this study was to compare the patient comfort and results of suprapubic cystostomy versus urethral catheter used for urinary diversion after hypospadias repair.

### **PATIENTS AND METHODS**

These randomized controlled trials were conducted at the Department of Urology and Renal Transplantation, Bahawal Victoria Hospital/Quaid-e-Azam Medical College, Bahawalpur from June 2010 to December 2011. Patients admitted to Department of Urology with distal or middle hypospadias were included in this study. The patients with age of less than 1 year and more than 10 years were excluded from this study along with patients of proximal hypospadias and history of previous hypospadias repair. Investigations like complete blood count, urine routine examination, Ultrasonography abdomen were done. Detailed history asked about previous repair and its outcome for exclusion from this study.

A total of 60 patients were studied which were divided into two groups i.e. I and II with 30 patients in each group. In Group I, hypospadias repair was done over an improvised urethral stent distal to the external sphincter that did not extend to drain the urinary bladder. In these patients suprapubic cystostomy was used for urinary diversion. While in Group II, 8 Fr to 12 Fr Foley's catheter was used both for urinary diversion and urethral stenting which was anchored to the tip of the glans penis with a single non absorbable stitch to prevent its dislodgment.

All patients were operated under general anesthesia. A tourniquet was applied at base of penis to maintain a bloodless field for duration of about 40 minutes and released if more time

was required to complete repair. Tubularized incised plate urethroplasty and Mathieu's repair were commonly used techniques. All the patients were operated by the same team of surgeons. Sandwiched dressing was used which will be removed after 48 hours postoperatively.

All patients were maintained on antibiotic prophylaxis. Stent was kept for<sup>7-14</sup> days. Patient discharged from hospital at 72 hours post-operatively with urethral catheter or suprapubic cystostomy intact. Patients were followed for subsequent outcome. Follow up was initially fortnightly and then at 1 month intervals. Minimum follow up period was 3 months and maximum 18 months for these particular patients.

The collected data was analyzed by computer software SPSS version 16. Mean and standard deviation was calculated for age of patients. Frequency and percentage was calculated for qualitative variables. Chi Square was applied to compare the frequency of complications and cosmetic results. *P* value < 0.05 was considered as significant.

### **RESULTS**

A total of 60 patients were studied. In Group I (n=30) patients, suprapubic cystostomy was used for urinary diversion while in Group II (n=30) patients transurethral catheter was used for urinary diversion. Age range was from 1 year to 10 years with the mean of  $3\pm 0.75$  years. %age of patients according to age groups is shown in Table-1.

Tubularized incised plate urethroplasty and Mathieu's repair were the commonly used repairs for both groups as shown in Table-II. Painful trigone irritation was common and distressing in 12(40%) patients in group II which was treated by antispasmodics in 07 patients while in 05 patients it resulted in early catheter removal and subsequent development of urethrocutaneous fistula in 01 patient and meatal stenosis in 01 patient. The post-operative nursing care was easier in patients with suprapubic diversion as children with transurethral catheter tried to pull their catheter due to discomfort and straining on voiding

which resulted in repair disruption in 2 patients. Overall complication rate was 6.67% and 23.33% in group I and group II respectively ( $p < 0.001$ ). The type of repair performed and results of both groups were shown in Table-II.

**DISCUSSION**

Hypospadias surgery is challenging. The fact that there are wide variations in the presentation and extent of malformations as well as tissue characteristics make every hypospadias patient distinct. The proposal of a universal comprehensive algorithm for hypospadias repair is difficult.<sup>2</sup>

There is a great controversy about urinary diversion after hypospadias repair. In all the cases except for the most minor defects, some form of urinary diversion (using an indwelling catheter or suprapubic cystostomy) is employed for 1-2 weeks at the time of operation. This is to enable the reconstructed tissue to remain dry

during the critical period of healing, thus

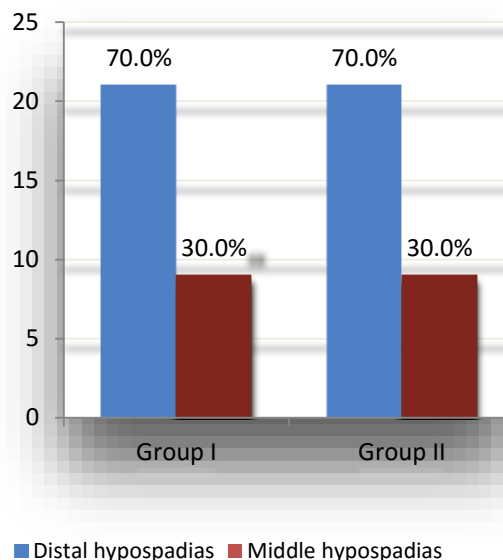


Figure: Percentage of patients with Type of Hypospadias. ( $p=1.000$ ).

Table I: Percentage of patients according to age groups.

Age (years)	Group I		Group II	
	No.	%age	No.	%age
1-5 years	21	70.0	21	70.0
6-10 years	09	30.0	09	30.0

$p=1.000$

The %age of patients according to type of hypospadias in both groups are shown in Figure-I.

Table-2: Type of Repair and Results of both groups.

	Group I (n=30) Suprapubic cystostomy	Group II (n=30) Transurethral Catheter	P-Value
<b>Type of Repair</b>			
TIP	15(50%)	18(60%)	0.022
Mathieu's	12(40%)	09(30%)	
Others	03(10%)	03(10%)	
<b>Easy Nursing Care</b>	27(90%)	04(13.33%)	<0.0001
<b>Straining on Voiding</b>	06(20%)	15(50%)	0.0149
<b>Accidental Dislodgment</b>	02(6.67%)	0(0%)	0.1503
<b>Complications</b>			
Painful Trigone Irritation	02(6.67%)	12(40%)	0.0023
Urethrocutaneous	01(3.33%)	02(6.67%)	0.554
Fistula	00(0%)	02(6.67%)	0.150
Meatal Stenosis	01(3.33%)	01(3.33%)	1.000
Urethral Stricture	00(0%)	02(6.67%)	0.1503
Repair Disruption			
<b>Satisfactory Cosmetic Results</b>	27(90%)	21(70%)	0.053

preventing infection, wound breakdown and other problems.<sup>5,6,8</sup>

Germiyanoglu C et al<sup>9</sup> and Sigumonrong YH et al<sup>10</sup> reported that urinary diversion after hypospadias repair has no proven beneficial effect on surgical outcome. Joshi A et al<sup>11</sup> and Almodhen F et al<sup>12</sup> have reported excellent results with stent free Mathieu's repair and tubularized incised plate urethroplasty respectively. De Badiola F et al<sup>13</sup> have reported that urethral drainage by catheter or stent does not reduce the risk of complications after hypospadias repair. While Zhang J et al<sup>14</sup> reported that urinary diversion after one stage hypospadias repair is helpful for spontaneous healing of small fistulae and also useful in reducing the incidence of fistula formation.

Any type of urinary diversion used whether suprapubic cystostomy or transurethral stenting has certain advantages and disadvantages, one over the other, irrespective of the outcome of repair. Transurethral catheterization has the most common complication of bladder spasm owing to irritation of the detrusor muscle by the tip of the catheter.<sup>15</sup> Transurethral stenting led to significant patient irritability with voiding problems and high possibility of stent dislodgment either accidental or during voiding.<sup>7</sup> Osifo OD et al<sup>16</sup> have reported prolonged hospital stay with suprapubic urinary diversion as compared to transurethral stenting. In this study, we have found that patients with transurethral catheterization have faced bladder irritability and voiding problems more than suprapubic cystostomy while no difference was noted for the duration of hospitalization.

In the early postoperative period following hypospadias repair, the management of patient should encompass control of pain, care of the urinary catheter and wound dressing. These are particularly important to reduce the stress to patient and for improved outcome.<sup>17</sup> Our study showed that post operative nursing care was more demanding in patients with transurethral catheterization because the children has to be restricted to bed to avoid any pull on the catheter. This was also required to prevent

children from pulling the catheter due to bladder irritation and voiding difficulties which resulted in repair disruption in 2 of our patient. While in suprapubic cystostomy, no special care of the suprapubic tube was required as observed by Osifo OD et al<sup>16</sup> and Oesterling J et al.<sup>6</sup>

Demirbilek et al<sup>18</sup> reported incidence of urethrocutaneous fistula in hypospadias repair, 7.14% in patients with suprapubic urinary diversion and 14.28% in patients with transurethral catheter used for urinary drainage. Radwan MH et al<sup>19</sup> reported this difference as 2.0% and 11.0% respectively. We have come across this difference as 3.33% in suprapubic diversion and 6.67% in patients with transurethral catheterization. Incidence of Meatal Stenosis was 0-6% for suprapubic diversion and 2-12% for transurethral diversion in many previous studies<sup>6,8,16,18,19</sup> while in our study meatal stenosis was 0% and 6.67% respectively. In a study, Osifo OD et al<sup>16</sup> observed complete repair disruption 1.4% for suprapubic diversion and 2.4% for transurethral diversion and Radwan MH et al<sup>19</sup> reported 0% and 5.0% respectively. While in our study, complete repair disruption occurred in 0% and 6.67% respectively. Many previous studies showed that different types of urinary diversion used in hypospadias repair does not effect the incidence of urethral stricture, similarly was observed in our study.<sup>16,18,19</sup>

In our study, cosmetic results were similar with both the methods.

## CONCLUSION

This study concludes that suprapubic urinary diversion is more effective and favored means of diversion than transurethral catheter in hypospadias repair because of its lower complication rate, less bladder irritability and patient discomfort. However, cosmetic appearance of the external urethral meatus almost similar with both the methods.

## REFERENCES

1. Djakovic N, Nayarangi-Dix J, Ozturk A, Hohenfellner M. Hypospadias. *Adv Urol*. 2008;6:501-35.
2. Moriquand PDE, Mure PY. Hypospadias. *Pediatric Urology*. Saunders, Philadelphia. 2009; pp 713-28.
3. Wein JA, Kavoussi LR, Novick AC, Partin AW, Peters CA. *Campbell-Wash Urology*. 9th ed. Philadelphia: Saunders Elsevier. 2008.

4. Rasool M, Sheikh AH, Tabassum SA, Amin M. Hypospadias repair. *Professional Med J*. Dec 2007;14(4):677-84.
  5. Chandrasekharam VVS. Day care hypospadias surgery: single surgeon experience. *J Indian Assoc Pediatr Surg*. 2007;12(4):206-8.
  6. Oesterling J, Gearhart J, Jeffs R. Urinary diversion in hypospadias surgery. *Urology*. 2009; 29:513-16.
  7. Arda IS, Mahmutoglu M. Urethral catheterization in hypospadias surgery: should the device enter the bladder or be made a urethral stent? *J Pediatr Surg*. 2001; 36:1829-31.
  8. Saleh AM, Wesam A, Amr A, Salah M. Urinary drainage after hypospadias repair: urethral stent or bladder catheter. *Annals of Pediatr Surg*. 2009; 5(2):101-3.
  9. Germiyanoglu C, Nohuglu B, Ayyildiz A, Akgul KT. Investigation of factors affecting result of distal hypospadias repair: comparison of two techniques. *Urology*. 2006; 68(1):182-5.
  10. Sigumonrong YH, Santoso A, Tarmono, Widodo JP. Perbedaan angka kejadian fistel uretrotokutan pada penggunaan kateter uretra dan kateter suprapubik dengan stent setelah operasi hipospadia. *Indonesian J of Urol*. 2011; <http://juri.urologi.or.id>.
  11. Joshi A, Surana RS. Prospective randomized study of stented versus unstented Mathieu's repair of hypospadias. *The Internet J of Urology*. 2006; 3 (2):1-3.
  12. Almodhen F, Alzahrani A, Jednak R, Capolicchio JP et al. Nonstented tubularized incised plate urethroplasty with Y-to-I spongioplasty in non-toilet trained children. *CUAJ*. 2008; 2(2):110-4.
  13. De Badiola F, Anderson K, Gonzatez R. Hypospadias repair in an outpatient setting without proximal urinary diversion. Experience with 113 uretheroplasties. *J Pediatr Surg*. 1991; 26:461-4.
  14. Zhang J, Li S, Chen X. Urinary diversion in the one stage hypospadias repair. *Zhonghua Zheng Xing Shao Shang Wai Ke Za Zhi*. 1999; 15(2):140-1.
  15. Nazarko L. Bladder pain from indwelling urinary catheterization: Case study. *Br J Nurs*. 2007; 16:511-14.
  16. Osifo OD, Azeez AL. Outcome of transurethral and suprapubic urinary diversion following hypospadias repair in children. *Pak J Med Sci*. 2010; 26(2):329-34.
  17. Okoro PE, Tsang T. Short hospital stay versus day-care Mathieu's hypospadias repair. *Afr J Pediatr Surg*. 2008; 5:29-31.
  18. Demirbilek S, Atayurt HF. One-stage hypospadias repair with stent or suprapubic diversion: which is better? *J Pediatr Surg*. 1997; 32(12):1711-2.
  19. Radwan MH, Soliman G, Elgamal A, Ghalwash A, Elashry M. Diversion Effect Results? *Eur Urol Suppl*. 2011; 10(2):87.
  20. Joseph E, Oesterling J, John P, Gearhart J, Robert D, Jeffs R. Urinary diversion in hypospadias surgery. *Urology*. 1987; 29(5):513-16.
- .....