

## ADULT OSTEOPETROSIS

Shahab Ahmed, Khurshid Uttra

Combined Military Hospital, Hyderabad

### INTRODUCTION

Osteopetrosis, also called marble bone disease, was first described by Heinrich Albers-Schonberg in 1904 which is a rare hereditary bone disease of heterogeneous pathophysiology in which failure of osteoclastic bone resorption leads to increased bone mass. The primary underlying defect in all types of osteopetrosis is failure of the osteoclasts to reabsorb bone resulting in thickened sclerotic bones, which have poor mechanical properties. Increased bone fragility results from a failure of the collagen fibers to connect osteons properly and from defective remodeling of woven bone to compact bone [1]. This leads to generalized sclerosis of bone with an increased skeletal mass due to abnormally dense bone.

### CASE REPORT

A 32 years old soldier who was being treated for pulmonary tuberculosis his chest X-ray (Fig-1) revealed an incidental finding of end-plate sclerosis of thoracic vertebral bodies "rigger-jersey" spine. In view of that he was investigated further. His X-ray lumbar spine (Fig-2) showed similar changes of end-plate sclerosis. X-ray pelvis (Fig-3) showed increased bone density of the iliac crests, sacro-iliac joints, symphysis pubis, ischael tuberosities and acetabulum, more pronounced on the right side (endobones) and X-ray skull (Fig-4) showed sclerosis of the skull base. All these features are diagnostic of Adult Osteopetrosis Type II. Further investigations revealed raised serum alkaline phosphatase.

### DISCUSSION

Generalized osteosclerosis is apparent radio graphically, often with a "bone within a bone" appearance [2].

**Correspondence:** Lt Col Shahab Ahmed, Radiologist, CMH, Hyderabad  
Email: memon18pak@yahoo.com

Received 16 Dec 2006; Accepted 12 Dec 2008

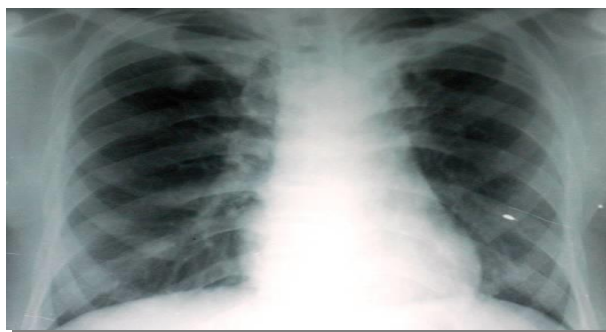


Fig-1: Pulmonary tuberculosis and end-plate sclerosis of thoracic vertebral bodies rigger-jersey spine




Fig-2: Rigger-jersey spine (lumbar region)

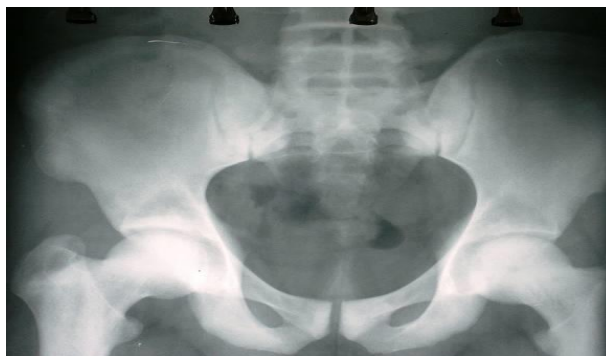

Fig-3: Increased bone density of the iliac crests, sacro-iliac joints, symphysis pubis, ischael tuberosities and acetabulum, more pronounced on the right side (endobones).

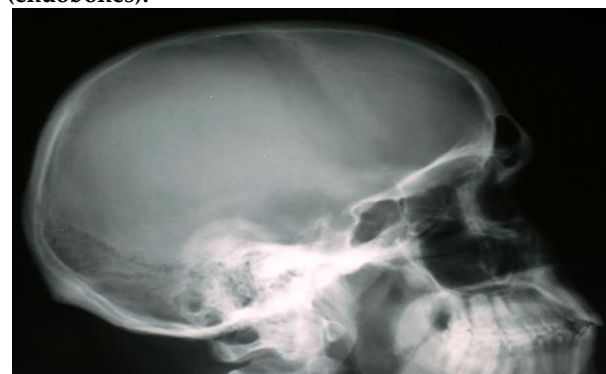

Fig-4: Sclerosis of the skull base

**Table-1: Types of Osteopetrosis**

Characteristics	Adult onset	Infantile	Intermediate
Inheritance	Autosomal dominant	Autosomal recessive	Autosomal recessive
Bone marrow failure	None	Severe	None
Prognosis	Good	Poor	Poor
Diagnosis	Incidentally	Before age of 1 yr	

**Table-2: Types of adult osteopetrosis**

Characteristics	Type I	Type II
Skull Sclerosis	Marked sclerosis mainly of the vault	Sclerosis mainly of the base
Spine	Does not show much sclerosis	"Rugger jersey" appearance
Pelvis	No endobones	Shows endobones in the pelvis
Risk of fracture	Low	High
Acid phosphatase	Normal	Very high

Osteopetrosis varies in severity depending on the time of recognition and is classified on the basis of the clinical aspects of the three primary types: (table 1) infantile or "malignant" osteopetrosis, inherited in an autosomal recessive inheritance pattern; "intermediate" autosomal recessive osteopetrosis; and autosomal dominant osteopetrosis [3]. Recently a case has been described with abnormal bone modeling and increased bone density with histological features of osteopetrosis associated with extended bisphosphonate therapy in a 12-year-old boy. This case suggests that agents that inhibit the recruitment and function of osteoclasts, when given over an extended period of time, may cause a clinical picture comparable to heritable osteopetrosis and has been designated as acquired osteopetrosis [4].

Overall the incidence of the disease is estimated at 1 in 100,000-500,000. However, the actual incidence is unknown because no large epidemiological studies have been conducted so far[5].The incidence of autosomal recessive osteopetrosis is approximately 1 in 300,000 births but is almost 10 times higher in Costa Rica [6].

Infantile osteopetrosis is diagnosed early in life. Failure to thrive and growth retardation are early symptoms. Cranial nerve entrapment neuropathies occur due to failure of the foramina in the skull to widen completely. Manifestations include deafness, proptosis, and hydrocephalus. Osteomyelitis of the mandible is common due to an abnormal blood supply. Bones are fragile and

can fracture easily. Defective osseous tissue tends to replace bone marrow, which can cause bone marrow failure with resultant pancytopenia.

Extramedullary haematopoiesis might occur with resultant hepatosplenomegaly, hypersplenism, and haemolysis [7]. Parathyroid hormone is raised due to secondary hyperparathyroidism and acid phosphatase and creatinine kinase (isoform BB) are elevated due to release from defective osteoclast [5].

Adult osteopetrosis is caused by heterozygous mutations in the chloride channel 7 (CLCN7) gene [8]. Approximately one half of the patients are asymptomatic, and the diagnosis is made incidentally or is based on family history. Two distinct types have been described (type I and type II) based on radiographic, biochemical, and clinical features [5]. In type I disease sclerosis of the skull mainly affects the vault with marked thickening. The spine does not show much sclerosis whereas in type II disease sclerosis is found mainly in the base of the skull. The spine always shows the rugger jersey appearance, and the pelvis always shows subcrystal sclerosis. Transverse banding of metaphyses is commonly seen in patients with type II disease, but not in patients with type I disease. Their presence confirms type II disease, but their absence does not necessarily indicate type I disease. Other patients might present with osteomyelitis or fractures as bones are brittle and fragile and approximately 40% of patients have recurrent fractures. Bony defects are common and

include cranial nerve entrapment neuropathies (e.g., with deafness, facial palsy, carpal tunnel syndrome, and osteoarthritis). Other manifestations include visual impairment due to retinal degeneration and psychomotor retardation [9].

Radiological features usually are diagnostic. Bones may be uniformly sclerotic, but alternating sclerotic and lucent bands may be noted in iliac wings and near ends of long bones. The bones might appear club like or show an appearance of a "bone within bone". The entire skull is thickened and dense, especially at the base. Sinuses are small and underpneumatized. Vertebrae are extremely radio dense. They may show alternating bands, known as the "rugger-jersey" sign [10]. Typing patients might be important to predict a fracture pattern because type II patients appear to be at higher risk of fracture (Table-2) [11].

Infantile osteopetrosis warrants treatment due to the adverse outcome associated with the disease. Calcitriol appears to help by stimulating dormant osteoclasts and, thus, stimulating bone resorption. Usually, it only produces a modest clinical improvement, which is not sustained after discontinuation of therapy [12]. Erythropoietin can be used to correct anemia. Bone marrow transplant remarkably has been shown to improve osteopetrosis in some cases. It can cure both bone marrow failure and metabolic abnormalities [13]. Adult osteopetrosis requires no treatment by itself though complications of the disease might require intervention. No specific medical treatment exists for the adult type. In adult osteopetrosis, surgical treatment may be needed for aesthetic reasons (in patients with significant facial deformity) or functional reasons (for multiple fractures with deformity and loss of function).

## REFERENCES

1. Sutton D. Textbook of radiology and imaging. 7th ed. Edinburgh: Churchill Livingstone 2003;2: 1126-9.
2. Loria-Cortes R, Quesada-Calvo E, Cordero-Chaverri C. Osteopetrosis in children: a report of 26 cases. *J Pediatr* 1977; 91: 43-7.
3. Shapiro F. Osteopetrosis: current clinical considerations. *Clin Orthop* 1993;34-44.
4. Whyte MP, Wenkert D, Clements KL, McAlister WH, Mumm S. Bisphosphonate-induced osteopetrosis. *N Engl J Med* 2003; 349:457-63.
5. Chapman S, Nakielny R. Aids to radiological differential diagnosis. 4th ed. Edinburgh. Saunders 2003:577-8.
6. Fasth A, Porras O. Human malignant osteopetrosis: pathophysiology, management and the role of bone marrow transplantation. *Pediatr Transplant* 1999; 3: 102-7.
7. Gerritsen EJ, Vossen JM, van Loo IH. Autosomal recessive osteopetrosis: variability of findings at diagnosis and during the natural course. *Pediatrics* 1994; 93: 247-53.
8. Waguespack SG, Koller DL, White KE. Chloride channel 7 (CLCN7) gene mutations and autosomal dominant osteopetrosis, type II. *J Bone Miner Res* 2003; 18: 1513-8.
9. Waguespack SG, Hui SL, Dimeglio LA, Econs MJ. Autosomal dominant osteopetrosis: clinical severity and natural history of 94 subjects with a chloride channel 7 gene mutation. *J Clin Endocrinol Metab*. 2007; 92 (3):771-8.
10. Carolino J, Peraz JA, Popa A. Osteopetrosis. *Am Fam Phy* 1998;57:6.
11. Bénichou OD, Laredo JD, de Vernejoul MC. Type II autosomal dominant osteopetrosis (Albers-Schönberg disease): clinical and radiological manifestations in 42 patients. *Bone*. 2000; 26 (1): 87-93.
12. Key LL, Carnes D, Cole S, et al. Treatment of congenital osteopetrosis with high-dose calcitriol. *N Engl J Med* 1984; 310: 409-15.
13. Coccia PF, Krivit W, Cervenka J. Successful bone-marrow transplant for infantile malignant osteopetrosis. *N Engl J Med* 1980; 302: 701-8.