

## EFFECT OF ACETYLSALICYLIC ACID ON SPERMATOGENESIS IN ADULT ALBINO MICE

Muhammad Kamran Ameer, Mohammad Tahir

University of Health Sciences Lahore

### ABSTRACT

**Objective:** To Observe the histological and morphological effects of acetylsalicylic acid (ASA) on spermatogenesis in male albino mice.

**Study Design:** Laboratory based randomized controlled trial.

**Place and Duration of Study:** Department of Anatomy University of Health Sciences, Lahore from Apr, 2012 to Dec, 2012.

**Material and Methods:** Thirty nine male albino mice, 6-8 weeks old weighing  $30 \pm 5$  gm, were used; these were randomly divided into three groups having thirteen mice in each using random numbers table. Group A served as a control and was given distilled water orally via oral gavage 10 ml per kg for 30 days. Group B was given acetylsalicylic acid 100 mg/kg dissolved in 10 ml distilled orally for a period of 30 days. Group C was given acetylsalicylic acid 25 mg/kg dissolved in 2.5 ml distilled orally for a period of 30 days. Animals were sacrificed 24 hours after the last dose and the testes were removed, fixed in Bouin's fixative for 48 hours. Five microns thick sections of processed tissue were stained with H&E and PAS for calculation of Johnsen score and diameter of seminiferous tubules. Serum testosterone level was measured by testosterone enzyme immunoassay test kits.

**Results:** Microscopic examination demonstrated that ASA treatment lead to statistically significant increase in the mean Johnsen score and mean diameter of seminiferous tubules.

**Conclusion:** It was concluded from the current study that ASA treatment enhances spermatogenesis.

**Keywords:** Acetylsalicylic acid (ASA), Mice, Spermatogenesis, Testes.

### INTRODUCTION

Acetylsalicylic acid is one of the widely used drugs world over. For many decades it has been used to treat arthritis. It has now become the mainstay of prevention of ischemic heart disease and stroke<sup>1</sup>. Its most common side effects are gastrointestinal which include dyspepsia and peptic ulcers with bleeding and perforation<sup>2</sup>.

Its effects on the male reproductive system have been a major concern since very long and so far many studies have been conducted on this aspect. Boyd<sup>3</sup> commented that prolonged daily intake of large doses of acetylsalicylic acid may impair spermatogenesis in male patients and he demonstrated the histological changes in animal study. It had also been reported that Acetylsalicylic acid causes significant decrease

in the weight of testis and number of spermatids at a dose of 5mg/100gm body weight/day in rats<sup>4</sup> when given for 30 days. Acetylsalicylic acid causes antiandrogenic and catabolic effects and decreases the weight of testis, caudal epididymis, seminal vesicles and vas deferens at a dose of 800 $\mu$ g/day for 7 days<sup>5</sup>. Machlin et al<sup>6</sup> demonstrated that aspirin exacerbates testicular degeneration in vitamin E-deficient rats, possibly because both aspirin and vitamin E deficiency decreases seminal prostaglandins.

Abbateillo et al<sup>7</sup> demonstrated that spermatogenesis in mice is increased by prolonged treatment with acetylsalicylic acid. Cenedella and Crouthamel<sup>8</sup> reported that oral administration of aspirin (50 mg/kg twice daily for 12 days) did not affect fertility. Significant increase was observed by Tanyildizi and Bozkurt<sup>9</sup> in the percentage of sperm motilities of rams after treatment with acetylsalicylic acid and metamizol.

Acetylsalicylic acid irreversibly inhibits cyclooxygenase enzyme and decreases the synthesis of prostaglandins in various body

**Correspondence:** Prof Muhammad Tahir, Anatomy Dept, University of Health Sciences, Lahore, Pakistan

Email: msaleo@yahoo.com

Received: 19 Sep 2013; revised received: 22 April 2014; accepted: 29 Sep 2014

tissues including testis. In rabbits the fertility of ejaculates significantly reduced by inactivation of prostaglandins<sup>10</sup>. Whereas Locher and Balazaki<sup>11</sup> reported that reduction of seminal prostaglandins in male rats by acetylsalicylic acid does not affect fertility.

Due to the controversial and limited data on effects of ASA on spermatogenesis, the present study is aimed to investigate whether ASA enhances or suppresses spermatogenesis by using Johnsen method of scoring; the serum testosterone levels were measured to evaluate the functional impacts.

### **MATERIAL AND METHODS**

These laboratory based randomized controlled trials were conducted at Department of Anatomy University Of Health Sciences, Lahore from Apr, 2012 to Dec, 2012.

Aspirin in powder form was obtained from BDH Limited Poole England. The dosage of aspirin was determined by Human Equivalence dose (HED). The HED of aspirin calculated was 100 mg/kg/day for high dose<sup>4</sup> and 25 mg/kg/day for low dose of aspirin<sup>12</sup> respectively. Stock solution of acetylsalicylic acid was prepared by dissolving 1gm of drug in 100ml of distilled water.

Thirty nine male albino mice of 6-8 weeks old weighing  $30 \pm 5$ g were used; these were kept under controlled environment (temperature  $23 \pm 2^\circ\text{C}$ , humidity  $55 \pm 5\%$ ) and light and dark cycle of 12 hours each. They were fed on standard pellet rodent diet and tap water ad libitum.

The animals were randomly divided into three groups having 13 mice each using random numbers table. Group A served as control and received 10ml/kg of distilled water, group B was given acetylsalicylic acid at a dose of 100mg/kg dissolved in 10 ml distilled water, group C was given acetylsalicylic acid at a dose of 25 mg/kg dissolved in 2.5 ml distilled water in all groups, the intervention was via oral gavage for a period of 30 days respectively.

On 31st day of the experiment each animal was anaesthetized with chloroform and blood samples were drawn by cardiac puncture and centrifuged. The clear serum was collected and

stored at  $-20^\circ\text{C}$  for biochemical estimation. A vertical midline incision was given extending from xiphoid process to the pubic symphysis. The testes were pushed into the body cavity and removed by pulling the tail of epididymis.

Spermatogenesis was assessed by "Johnsen Scoring Method" which is a convenient, accurate and useful method of measuring spermatogenesis and assessment of infertility<sup>13,14</sup>. This method includes scores from 1-10 as follows<sup>15</sup>:

10. Complete spermatogenesis with many spermatozoa; germinal epithelium organized in a regular thickness.
9. Many spermatozoa present but germinal epithelium disorganized.
8. Only a few spermatozoa.
7. No spermatozoa but many spermatids
6. No spermatozoa but few (<5) spermatids.
5. No spermatozoa or spermatids but many spermatocytes
4. No spermatozoa or spermatids but few (<5) spermatocytes
3. Spermatogonia are the only germ cell present.
2. No germ cells but sertoli cells are present.
1. No cells in tubule section.

Testosterone enzyme immunoassay test kits were used for the estimation of serum testosterone levels.

### **Statistical Analysis**

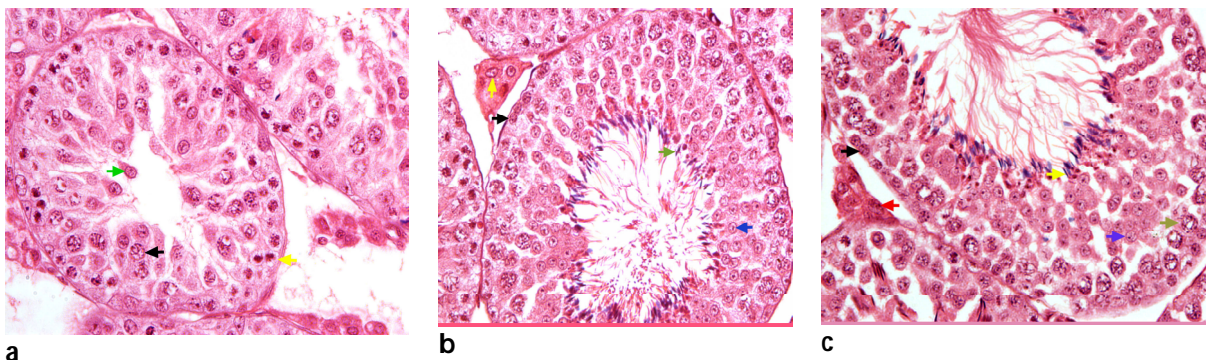
Data had been analyzed using SPSS version 18. Mean and standard deviation was calculated for quantitative variables. One way ANOVA was applied to compare variables followed by post Hoc Tukey Test. The p value < 0.05 was considered as statistically significant.

### **RESULTS**

Ten seminiferous tubules from three H & E stained slides were used in each mouse for calculating the mean tubular diameter. Mean diameter was significantly increased in ASA

treated Groups (B & C) as compared with the control (p-value = 0.05) (Table).

Mean Johnsen score of ASA treated groups



**Figure:** a). Photomicrograph of testes from group A illustrating a seminiferous tubule which contains spermatogonia (yellow arrow), primary spermatocytes (black arrow) and a few round spermatids (green arrow). Spermatozoa are not seen so the spermatogenesis is incomplete. H & E stain X400. b). Photomicrograph of testes from group B illustrating a seminiferous tubule, with complete spermatogenesis, which contains spermatogonia (black arrow) at periphery, round spermatids (blue arrow) and mature spermatozoa (green arrow) towards its lumen. Lyedig cells (yellow arrow) present outside the tubule. H & E stain X400. c). Photomicrograph of testes from group C illustrating a seminiferous tubule with complete spermatogenesis which contains spermatogonia (black arrow), primary spermatocytes (green arrow), round spermatid (blue arrow) and mature spermatozoa (yellow arrow). Lyedig cells (red arrow) present outside the tubule. H & E stain X400.

**Table-: Comparison of parameters between groups A, B & C.**

| Parameter                             | Group A (n=13)        | Group B (n=13)        | Group C(n=13)         | p-value |
|---------------------------------------|-----------------------|-----------------------|-----------------------|---------|
| Mean Johnsen Score                    | Mean+SD<br>8.4±.478   | Mean+SD<br>8.84±.202  | Mean+SD<br>9.00±.167  | 0.001   |
| Mean tubular diameter (µm)            | Mean+SD<br>169.4±14.1 | Mean+SD<br>188.0±20.1 | Mean+SD<br>187.9±17.9 | 0.05    |
| Mean serum testosterone level (ng/ml) | Mean+SD<br>7.16±2.55  | Mean+SD<br>9.66±2.87  | Mean+SD<br>9.31±3.79  | 0.100   |

\*p value ≤ 0.05 is statistically significant.

(B & C) was significantly higher than the control group A (p-value <0.001). Mean Johnsen score of Group C was higher than that of group B but it was statistically insignificant (p-value=0.123) (Table-1). Seminiferous tubules of group A mice mostly showed incomplete spermatogenesis containing spermatogonia, primary spermatocytes and a few round spermatids (fig-a). Seminiferous tubules of group B & C mice mostly showed complete spermatogenesis containing spermatogonia, primary spermatocytes, round spermatid and mature spermatozoa organized regularly around basement membrane (fig b, & c). Mean serum testosterone levels in ASA treated groups was higher than the control group A but the difference was statistically insignificant (p = 0.100) (Table).

## DISCUSSION

Mean tubular diameter of ASA treated mice was greater than the control group mice

that is indirect evidence that ASA treatment had promoted spermatogenesis. Bustos-Obregon et al<sup>16</sup> described that increase in the tubular diameter was associated with an increase in their diameter on account of hypertrophy and an increase spermatogenic activity. In contrast to our findings Chalooob et al<sup>17</sup> described that ASA treatment reduced the tubular diameter in albino mice. The reason for this difference is explained by the difference in doses, current investigations used 100 and 25mg/kg of ASA given to the mice respectively as compared to small oral dose of 10mg/kg of ASA given to mice by Chalooob.

Spermatogenesis is regarded adequate when the Johnsen score is equal to or more than eight and it is regarded impaired at Johnsen score less than eight; it is also postulated that

there are less chances of pregnancy when the score is below eight<sup>13,14</sup>.

None of the study group had impaired spermatogenesis<sup>13</sup> but ASA treated groups had a significantly higher Johnsen score meaning that ASA treatment had enhanced spermatogenesis. During microscopic study of sections of testes from group 'A', most frequent Johnsen score was 6 and 7 while it was 8, 9 and 10 among animals of groups B and C.

Our findings are in agreement with Cenedella and Crouthamel<sup>8</sup> who reported that acetylsalicylic acid increases the level of fertility in subfertile mice by inhibiting PGF<sub>2</sub> $\alpha$ , production which is responsible for decreased steroidogenesis. Abbatiello et al<sup>7</sup> studied the effects of both NSAIDs (aspirin and indomethacin) and prostaglandins (PGE1 and PGE2) on mice spermatogenesis and concluded that NSAIDs increase spermatogenesis and testicular weight while PGs decrease spermatogenesis and testicular weight. In contrast to our findings Didolkar et al<sup>4</sup> stated that ASA administration to rats decreases the number of spermatids.

Consistent with our findings Loscher et al<sup>18</sup> in their study on rabbits concluded that inhibition of seminal prostaglandins, PGE2 and PGF<sub>2</sub> $\alpha$ , by NSAIDs lead to increased semen volume, sperm output, sperm motility and fertility although reduction of seminal PGs was significant. PGs concentration affects fertility depending upon the site of its action; increase in PGs concentration in testes or its decrease in seminal PGs leads to infertility<sup>11,19</sup>.

Chinoy et al<sup>20</sup> observed a decline in the fertility rate and testicular weight in adult rats when subcutaneous injections of PGF<sub>2</sub> $\alpha$  and PGE1 were given. They explained that PGs either decrease target organ response to androgens or inhibit conversion of testosterone to its active metabolites (dihydrotestosterone and estradiol). In humans, its high sperm density is associated with a low concentration of testicular PGs, especially PGE<sup>21</sup>. Hence, it is suggested that PGs inhibits the testosterone as a feedback mechanism and male fertility is 'down-regulated' by endogenous PGs present in the testes. ASA inhibits intratesticular PGs

production and spermatogenesis will not be inhibited.

## CONCLUSION

The results of present study suggest that ASA enhances spermatogenesis as evident by increased Johnsen Score, tubular diameter and serum testosterone levels upon treatment with ASA.

**CONFLICT OF INTEREST:** This study has no conflict of interest to declare by any author.

## REFERENCES

- Hennekens CH, Dyken ML, Fuster V. Aspirin as a therapeutic agent in cardiovascular disease. *Circulation*. 1997; 96: 2751-3.
- Sorensen HT, Mellemkjoer L, Blot WJ. Risk of upper gastrointestinal bleeding associated with use of low-dose aspirin. *Am J Gastroenterol* 2000; 95(9): 2218-22.
- Boyd EM. Testicular Atrophy from Analgesic Drugs. *J Din Pharmacol* 1970; 10: 222-27.
- Didolkar AK, Patel PB, Roychowdhury D. Effect of aspirin on spermatogenesis in mature and immature Rats. *Int J Androl* 1980; 3: 585-93.
- Kumar RA, Chinoy NJ. Effects of acetylsalicylic acid on reproductive organs of adolescent male rats. *Endocrinol Exp* 1988; 22:187-95.
- Machlin LJ, Gabriel E, Horn LR, Woo D, Filipiski R, Brin M, et al. Effects of aspirin and related drugs in vitamin E-deficient rats. *J Nutr* 1980; 110: 1958-64.
- Abbatiello ER, Kaminsky M, Weisbroth S. The effect of prostaglandin inhibitors on spermatogenesis. *Int J Fertil* 1975; 20(3): 177-82.
- Cenedella RJ, Crouthamel WG. Effect of aspirin upon male mouse fertility. *Prostaglandins* 1973; 4: 285-90.
- Tanyildizi S, Bozkurt T. Effects of acetylsalicylic acid and metamizol on hyaluronidase activity and sperm characteristics in rams. *Anim Reprod Sci* 2003;76: 195-204.
- Schlegel W, Fischer B, Beier HM, Schneider HPG. Effects on fertilization of rabbits of insemination with ejaculates treated with PG-dehydrogenase and antisera to PGE-2 and PGF-2 $\alpha$ . *J Reprod Fert* 1983; 68: 45-50.
- Loscher W, Blazaki D. Effect of non-steroidal anti-inflammatory drugs on fertility of male rats. *J Reprod Fert* 1986; 76: 65-73.
- Patrono C, Rodriguez LAG, Landolfi R, Baigent C. Low-dose aspirin for the prevention of atherothrombosis. *N Engl J Med* 2005; 353: 2373-83.
- Aafjes JH, Vijver JCM, Schenck PE. Value of a testicular biopsy rating for prognosis in oligozoospermia. *BM J* 1978; 1: 289-90.
- Pierik FH, Vreeburg JTM, Stijnen T, De Jong FH, Weber RFA. Serum Inhibin B as a marker of spermatogenesis. *J Clin Endocrinol Metab* 1998; 83: 3110-4.
- Johnsen SG. Testicular biopsy score count – A method for registration of spermatogenesis in human testes: normal values and results in 335 hypogonadal males. *Hormones* 1970;1: 2-25.
- Bustos-Obregon E, Carvallo M, Hartley-Belmar R, Sarabia L, Ponce C. Histopathological and histometrical assessment of boron exposure effects on mouse spermatogenesis. *Int J Morphol* 2007; 25: 919-25.
- Chalooob AK, Qasim HM, Gassim MH. The effects of aspirin and fenugreek seed on the testes of white mice. *J Fac Med Baghdad* 2009; 52: 349-51.
- Loscher W, Luttgenau H, Schlegel W, Krluger S. Pharmacokinetics of non-steroidal anti-inflammatory drugs in male rabbits after acute and chronic administration and effect of chronic treatment on seminal prostaglandins, sperm quality and fertility. *J Reprod Fert* 1988;82: 353-64.
- Cooper TG. Sperm maturation in the epididymis: a new look at an old problem. *Asian J Androl* 2007; 9: 533-9.
- Chinoy NJ, Sharma JD, Seethalakshmi L, Sanjeevan AG. Effect of prostaglandins on histopathology of male reproductive organs and fertility in rats. *Int J Fertil* 1980; 25: 267-74.
- Kelly RW, Cooper I, Templeton AA. Reduced prostaglandin levels in the semen of men with very high sperm concentrations. *J Reprod Fert* 1979; 56: 195-9.