

Late Post-Operative Complete Heart Block after Ventricular Septal Defect Repair Procedure

Sana Imtiaz, Khurram Akhtar, Amjad Mehmood, Hajira Akbar, Nadeem Sadiq, Andaleeb Ara

Armed Forces Institute of Cardiology/National Institute of Heart Diseases (AFIC/NIHD)/National University of Medical Sciences (NUMS) Rawalpindi Pakistan

ABSTRACT

In congenital cardiac surgery, intracardiac repair procedures like ventricular septal defect (VSD), atrioventricular septal defect and tetralogy of fallot (TOF) are associated with conduction system injury. Fewer cases are reported describing life threatening complication of late post-operative complete heart block. We are reporting 2 patients who presented with late complete heart block after ventricular septal defect repair and managed by permanent pacemaker placement in AFIC Cath lab.

Keywords: Complete heart block, Permanent pacemaker, Ventricular septal defect.

How to Cite This Article: Imtiaz S, Akhtar K, Mehmood A, Akbar H, Sadiq N, Ara A. Late Post-Operative Complete Heart Block after Ventricular Septal Defect Repair Procedure. *Pak Armed Forces Med J* 2022; 72(Suppl-3): S635-637. DOI: <https://doi.org/10.51253/pafmj.v72iSUPPL-3.9569>

This is an Open Access article distributed under the terms of the Creative Commons Attribution License (<https://creativecommons.org/licenses/by-nc/4.0/>), which permits unrestricted use, distribution, and reproduction in any medium, provided the original work is properly cited.

INTRODUCTION

In congenital cardiac surgery, intracardiac repair procedures like VSD, atrioventricular septal defect,¹ and TOF,² are associated with conduction system injury leading to complete heart blocks. Its incidence ranges between 1% to 3%.^{3,4} Direct injury to atrioventricular node, local edema or inflammation leading to fibrosis may subsequently lead to complete heart block (CHB) which is an important cause of long term morbidity. It usually manifests during or immediately after surgery. Mostly postoperative complete heart blocks are transient in nature and resolve within 2 to 3 weeks. But few patients can present late either with symptoms like dyspnea, exercise intolerance, syncope or diagnosed incidentally at routine follow up visit. There are few reported cases of late presentation of CHB after cardiac surgery either with initial normal postoperative course or transient heart block resolved with conservative management. Incidence of late post-operative heart block is about 0.3 to 0.7%.⁵ Herein we report 2 cases of post operative complete heart block with late presentation which were managed by PPM placement in Arm For Institute of Cardiology cath lab.

CASE REPORT

Case No-1 is a 9 years old male, operated for perimembranous VSD at the age of 18 months, presented about 7 and half year after surgery with history of breathlessness (NYHA class III) for past 2 weeks. Mother reported development of heart block post-operatively for which child remained dependent on

temporary pacemaker (TPM) for 2 weeks. Temporary pacing was discontinued after recovery of sinus rhythm. On general physical examination, his pulse rate was 49/min. Blood pressure was 90/60 mmHg, respiratory rate 24/min and SO₂ recorded as 98% in air. Precordial examination revealed a midline scar extending from suprasternal notch to the xyphoid, an apex beat located in left fifth intercostal space medial to midclavicular line, normal first and second heart sounds with no murmur. His ECG showed complete heart block with a ventricular rate of 49/min (Figure-1).

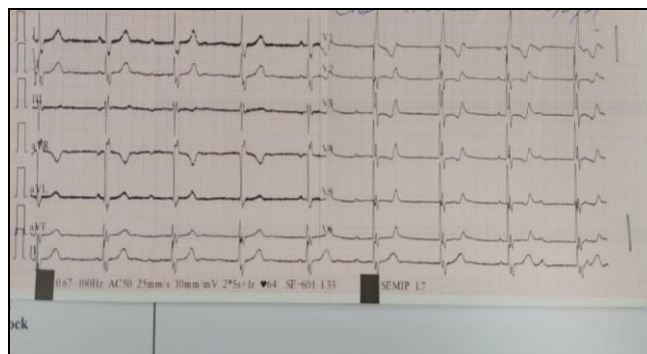


Figure-1: ECG showing complete Heart Block

Echocardiography showed stable VSD patch with good left ventricular function and ejection fraction of 60%. An emergency TPM was implanted via right trans femoral route in view of symptomatic CHB.

PPM placement was then planned in cath lab Armed Force Institute of Cardiology. Under strict aseptic measures, a transvenous single chamber PPM (ST JUDES) lead passed via left subclavian vein and stabilized in right ventricular apex by paediatric cardiology team (Figure-2).

Correspondence: Dr Sana Imtiaz, Department of Paeds Cardiology, Armed Forces Institute of Cardiology/National Institute of Heart Diseases (AFIC/NIHD), Rawalpindi Pakistan

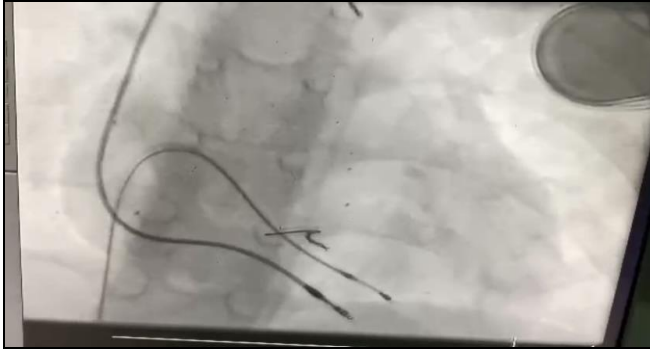


Figure-2: PPM Lead Fixed in RV apex

Functionality of pacemaker lead was assessed by Electrophysiology team followed by battery placement in left infraclavicular subpectoralis region by cardiac surgeon in the cath lab. The patient was discharged home in a hemodynamically stable condition on the 5th day (Figure-3).

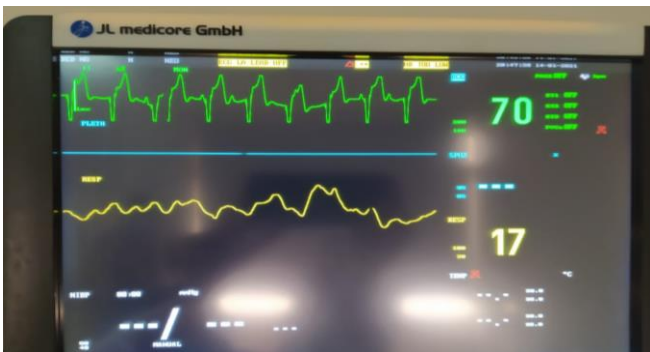

Figure-3: Post Pacemaker Implantation Rhythm and Rate

Case No-2 is a 13 years old male, operated for moderate size perimembranous VSD 1 year back presented to outpatient department for routine follow up and echocardiography. His post-operative recovery was smooth and uneventful, with no symptoms like dyspnea or syncope reported in last 1 year. He was found to have bradycardia (heart rate 52/min) on echocardiography. ECG revealed complete heart block. 24 hours holter monitoring was advised and patient was planned for transvenous PPM placement after electrophysiologist consultation.

DISCUSSION

Bradyarrhythmia is a common complication associated with surgical repair of congenital heart disease.⁶ Post-operative complete heart block may present late after months or years of intracardiac repair. Late presentation is defined as heart block which occurs 30 days after surgery.⁷ Most of the patients who present with late CHB have history of early transient block

which then recovers but with impermanent sinus rhythm.⁸ After recovery from early transient block, ECG findings which subsequently lead to complete heart block include residual bundle branch block, bifascicular block, change of QRS axis, prolonged PR interval, different *p*-wave morphology and asymptomatic 2nd degree heart block.⁹ Progressive fibrosis and sclerosis are the underlying causes for late post operative CHB.¹⁰ These patients may be diagnosed on routine follow up when bradycardia is observed on examination and echocardiography and ECG is suggestive of CHB or they can present with history of syncope, dyspnea, dizziness, heart failure or even sudden cardiac death. It is of utmost importance to keep a close follow up of patients who undergo intra-cardiac repair surgery and specially those who experience early transient post-operative CHB. These cases highlight the fact that patients with perimembranous VSD patch plasty may remain asymptomatic after developing late postoperative heart block and undetected on follow up visits. It may be diagnosed for the first time when they present with CHB warranting immediate pacemaker implantation. Our patient didn't have any follow up visit in past 6 years until he presented with symptomatic CHB. Moreover, conduction system injury is not only a complication of VSD surgical repair but also observed after perimembranous VSD device closure and rarely seen after aortic valve replacement.¹¹

CONCLUSION

Considering late post-operative heart block as a life threatening complication, regular follow up and high index of suspicion is required by primary health care provider and cardiologist for timely detection and management.

ACKNOWLEDGEMENT

I am deeply grateful to my supervisor for his guidance, patience and support who provided insight and expertise that greatly assisted my research project. I also want to share my gratitude for Comdt Exec Dir AFIC/NIHD and HOD R&D for their support and contribution in completion of the research paper

Conflict of Interest: None.

Author's Contribution

Following authors have made substantial contributions to the manuscript as under:

- SI: Manuscript writing, concept and editing
- KA: Intellectual contribution, concept and final approval
- AM: Final approval, proof reading and critical review
- HA: Review of article, formatting and critical review
- NS: Intellectual contribution, concept and final approval
- AA: Final approval, proof reading and critical review

Late Post-Operative Complete Heart Block

Authors agree to be accountable for all aspects of the work in ensuring that questions related to the accuracy or integrity of any part of the work are appropriately investigated and resolved.

REFERENCES

1. Di Mambro C, Calvieri C, Silvetti MS. Bradyarrhythmias in Repaired Atrioventricular Septal Defects: Single-Center Experience Based on 34 Years of Follow-Up of 522 Patients. *Pediatr Cardiol* 2018; 39(1): 1590-1597
2. Hejazi R, Balubaid M, Alata J, Waggass R. Late complete heart block post-tetralogy of Fallot repair: a possible new predicting, precipitating factor and review of related cases. *BMJ Case Rep* 2019; 4(1): 12-14.
3. Bonatti V, Agnetti A, Squarcia U. Early and late postoperative complete heart block in pediatric patients submitted to open-heart surgery for congenital heart disease. *Pediatr Med Chir* 1998; 20(1): 181-186.
4. Liberman L, Silver ES, Chai PJ, Anderson BR. Incidence and characteristics of heart block after heart surgery in pediatric patients: a multicenter study. *J Thorac Cardiovasc Surg* 2016; 152(1): 197-202.
5. Nasser BA, Mesned AR, Mohamad T, Kabbani MS. Late-presenting complete heart block after pediatric cardiac surgery. *J Saudi Heart Assoc* 2016; 28(1): 59-62.
6. Niu MC, Dickerson HA, Moore JA et al. Heterotaxy syndrome and associated arrhythmias in pediatric patients. *Heart Rhythm* 2018; 15(1): 548-554
7. Lin A, Mahle WT, Frias PA, et al. Early and delayed atrioventricular conduction block after routine surgery for congenital heart disease. *J Thorac Cardiovasc Surg* 2010; 140(1): 158-160.
8. Gross GJ, Chiu CC, Hamilton RM. Natural history of postoperative heart block in congenital heart disease: Implications for pacing intervention. *Heart Rhythm* 2006; 3(1): 601-604.
9. Hayan A, Mohamed SK, Omar H, Hussam MH, Saleh AG. Late presenting complete heart block after surgical repair of ventricular septal defect. *Egyptian Heart J* 2018; 70(1): 455-459.
10. Villain E, Ouarda F, Beyler C. Predictive factors for late complete atrio-ventricular block after surgical treatment for congenital cardiopathy. *Arch Mal Coeur Vaiss* 2003; 96(1): 495-498.
11. Chopra N, Tong MS, Yakubov SJ: Very late occurrence of complete heart block without preexisting atrioventricular conduction abnormalities: a rare complication after transaortic valvular replacement. *Heart Rhythm* 2018; 4(1): 77-81.