

Surgical Revascularization of the Dual Left Anterior Descending Coronary Artery; A Case Report

Imtiaz Ahmed Chaudhry, Mehwish Naseer*, Fakhar-e-Fayyaz*, Muhammad Adnan Akram, Rehana Javaid

Armed Forces Institute of Cardiology/National Institute of Heart Diseases (AFIC/NIHD)/National University of Medical Sciences (NUMS) Rawalpindi Pakistan,
*Army Cardiac Center, Lahore Pakistan

ABSTRACT

Although dual left anterior descending arteries are found in about 1% of the population, identification and localization of these coronaries remains a challenge for cardiac surgeons throughout coronary artery bypass graft surgery. We present a case of dual left anterior descending (LAD) coronary artery disease and highlight the techniques used for identifying these vessels.

Keywords: Coronary artery, Dual LAD, Intramyocardial, Revascularization.

How to Cite This Article: Chaudhry IA, Naseer M, Fayyaz F, Akram MA, Javaid R. Surgical Revascularization of the Dual Left Anterior Descending Coronary Artery; A Case Report. *Pak Armed Forces Med J* 2022; 72(Suppl-3): S604-606. DOI: <https://doi.org/10.51253/pafmj.v72iSUPPL-3.9558>

This is an Open Access article distributed under the terms of the Creative Commons Attribution License (<https://creativecommons.org/licenses/by-nc/4.0/>), which permits unrestricted use, distribution, and reproduction in any medium, provided the original work is properly cited.

INTRODUCTION

Heart being one of the most vital organ pumps blood to the whole body. However, vitality of the heart depends on patent coronary arteries. Coronary arteries in general run a subepicardial course and become epicardial in the distal part of their course. Dual LAD coronary artery is an uncommon congenital anomaly. In various coronary angiographic studies, the reported incidence of dual LAD is 0.64–1.3%.^{1,2} Accurate localization of coronaries in CABG surgery is imperative for identification and revascularization of the coronary arteries.

CASE REPORT

A 61-year-old diabetic and hypertensive patient presented to the cardiology outpatient department with effort angina. On ECG there was T-wave inversion in the anterior chest leads. His transthoracic echocardiography revealed a good left ventricular systolic function. He undertook coronary angiography which discovered a type-I dual LAD system with acute lesions in both the small and long LADs, critical lesion in the right coronary artery and the left circumflex coronary artery. CABG surgery was scheduled for the patient. On pump coronary artery bypass graft surgery (CABG) was performed (Figure-1).

The short LAD which was the artery supplying all the septal perforators was identified by meticulous dissection in the the anterior interventricular groove (Figure-2) over the proximal anterior inter ventricular septum (AIVS) lying adjacent to the long LAD and medial to the great cardiac vein; The short LAD was anastomosed with the left internal mammary artery,

the saphenous vein graft to the long LAD, the obtuse marginal artery, and the distal right coronary artery were all anastomosed. The patient recovered normally and was discharged on the fifth post-operative day. The patient has consented to publication of this report.

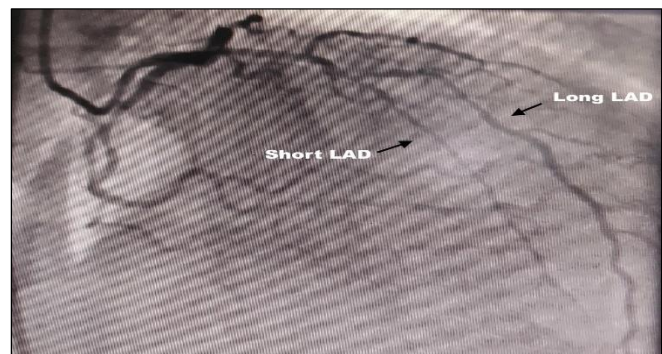


Figure-1: Dual LAD on Coronary Angiogram

DISCUSSION

The antroseptal and anterior lateral wall of the left ventricle are supplied by the left anterior descending coronary artery, which is the most important vessel to be grafted in coronary artery bypass graft surgery (CABG).³ The anatomy of the LAD differs in several ways. The LAD in a dual LAD system divides into two branches, the short and long LADs, in its proximal course. The short LAD does not reach the apex of the heart and instead runs in the proximal part of the anterior interventricular sulcus (AIVS), where it is the primary source of septal perforators. The long LAD has a variable course and it reaches the apex of the heart. Spindola-Franco and co-authors,⁴ identified four different angiographic variants of the dual LAD.

The presence on an intramyocardial LAD complicates the surgical process in CABG surgery, firstly

Correspondence: Dr Imtiaz Ahmed Chaudhry, Adult Cardiac Surgery Department, Armed Forces Institute of Cardiology, National Institute of Heart Diseases (AFIC/NIHD) Rawalpindi, Pakistan

identifying the exact location of the LAD at times can be time consuming and frustrating, increasing both the ischemic time and bypass times and the dissection process may be associated with damage to the LAD, diagonals the great cardiac vein and inadvertent entry into the right ventricle.⁵ Localization of the intramyocardial part also identifies the coronary artery where atheromatous process is less likely to affect the coronary artery.⁶

Performing a distal arteriotomy over the epicardial portion of a coronary and passing a fine malleable probe gently proximally has been adopted for more than half a century as a reliable method of identifying the proximal intramyocardial LAD.⁷ This technique is criticized as being crude and prone to inadvertent endothelial trauma. However it is reproducible, reliable and easy to teach to the newer generation of surgeons. In dual LAD system the short LAD is intramyocardial and never resurfaces, this technique becomes inapplicable here.

There are two commonly used clues that are followed for identification of the intramyocardial LAD, the "Groove sign" and the "Vein sign". The groove sign is the presence of a groove over the epicardial fat that overlies the intramyocardial LAD. As there are at times several epicardial grooves on the anterior surface of the heart, identifying the correct groove needs correlation with the alignment taking into consideration the imaginary line from the lateral border of the pulmonary trunk to the visible distal epicardial part of the LAD.⁸ The vein sign implies the intramyocardial LAD lies immediately to the right or at times beneath the great cardiac vein in the proximal part of its course,⁹ (Figure-2).

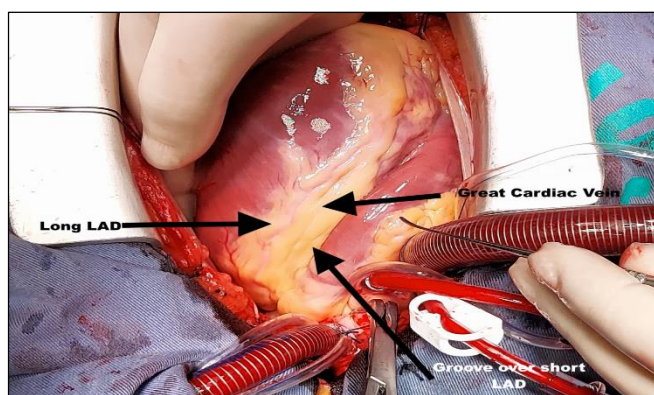


Figure-2: Identification of the Dual LAD system on the heart intraoperatively. (Seen from the head end of the operating table)

In dual LAD system, identification of the small LAD, which provides the septal perforators is more challenging than the IMLAD as the medial branch (small LAD) of the dual LAD divides high up near the origin from the left main stem, and dips down into the intraventricular septum giving septal perforators along its course. Furthermore the small LAD never becomes epicardial and ends near the mid point of the septum & so the traditional methods employed identifying a intramyocardial LAD are not applicable here.

One of the advantages of the dual LAD system is that, in the case of severe atherosclerotic disease, the binary blood flow distribution may limit the extent of ischemic insult to the myocardium.¹⁰

Before performing any intervention, a surgeon must understand the exact coronary anatomy, especially when considering the origin and course of an anomalous LAD and the variants of a dual LAD system. Inadequate revascularization with postoperative angina and ischemia may result from a lack of this knowledge. The presence of a short LAD may be misinterpreted as total mid-LAD occlusion. If both the short and long LADs are critically diseased, a graft to both vessels is required to revascularize the heart's anterolateral wall, interventricular septum, & apex.¹¹⁻¹²

CONCLUSION

Intraoperative identification of the dual LAD system is essential for complete revascularization in patients undergoing CABG surgery with this anatomic variant of coronary blood supply.

ACKNOWLEDGEMENT

I also want to share my gratitude for Comdt Exec Dir AFIC/NIHD for his support and contribution in completion of the research paper.

Conflict of Interest: None.

Author's Contribution

Following authors have made substantial contributions to the manuscript as under:

IAC: Concept, manuscript writing, proof reading

MN: Manuscript writing, idea, intellectual contribution

FEF: Intellectual contribution, critical review, proof reading

MAA: Intellectual contribution, referencing, review

RJ: Editing, review, referencing

Authors agree to be accountable for all aspects of the work in ensuring that questions related to the accuracy or integrity of any part of the work are appropriately investigated and resolved.

REFERENCES

1. Mansoor M, Khan W, Abbas F, Kumari U. A Rare Case of a Type IV Dual Left Anterior Descending Artery and Ectopic Left Anterior Descending and Circumflex Arteries Requiring Surgery. *The Journal of Tehran University Heart Center* 2022; 17(2): 71-74
2. Angelini P, Velasco JA, Flamm S. Coronary anomalies: Incidence, pathophysiology, and clinical relevance. *Circulation* 2002; 105: 2449-2454
3. Kirklin JW, Subcommittee on Coronary Artery Bypass Graft Surgery. Guidelines and indications for coronary artery bypass graft surgery. A report of the American College of Cardiology/American Heart Association Task Force on Assessment of Diagnostic and Therapeutic Cardiovascular Procedures J. *Am Coll Cardiol* 1991; 17(1): 543-589.
4. Spindola-Franco H, Grose R, Solomon N. Dual left anterior descending coronary artery: angiographic description of important variants & surgical implications. *Am Heart J* 1983; 105(2); 445-55.
5. Nedumaran B, Krishnasamy A, Ramasamy M, Kaliaperumal N, Balakrishnan R. Surgical revascularization of a rare type IV dual left anterior descending artery-a case report. *The Cardiothoracic Surgeon* 2022; 30: 3. <https://doi.org/10.1186/s43057-021-00062-3>
6. Trivellato M, Angelini P, Leachman RD. Variations in coronary anatomy: Normal versus abnormal. *Cardiovascular Diseases, Bulletin of the Texas Heart Institute* 1980; 7(4): 357-370.
7. Polacek P. Relation of myocardial bridges and loops on the coronary arteries to coronary occlusions. *Am Heart* 1961; 61(1): 44-52.
8. Robinson G: Location of the proximal left anterior descending coronary artery. *Ann Thorac Surg* 1973; 15(2): 299.
9. Vanker EA, Ajayi NO, Lazarus L, Satyapal KS. The intramyocardial left anterior descending artery: Prevalence and surgical considerations in coronary artery bypass grafting. *S Afr J Surg* 2014; 52(1): 18-21.
10. Mehmet C. Oz, MD, Matthew M. Cooper, MD. Hickey, PA, and Eric A. Rose, MD: Exposure of the Intramyocardial Left Anterior Descending Artery. *Ann Thorac Surg* 1994; 58(1): 1194-1195.
11. Ghosh P, Liew CK and Chauhan A. A Rare Coronary Anatomy Comprising Dual (Type IV) Left Anterior Descending Arteries and an Anomalous Left Circumflex Artery from the Right Coronary Artery. Ghosh P, Liew CK and Chauhan A. *J Invasive Cardiol* 2011; 23(2): 126-127.
12. Iqbal H, Chaudhry IA, Asghar MI: Dual Left Anterior Descending Coronary Artery - A Rare Congenital Anomaly. *Pak Armed Forces Med J* 2018; 68(Suppl-1): S212-S14.

.....