

Five Year Experience of Mitral Valve Repair Surgery at Armed Force Institute of Cardiology

Nasir Ali, Rehan Masroor, Muhammad Afsheen Iqbal, Syed Muzaffar Hasan Kirmani, Hannah Khurshid*, Muhammad Adnan Akram

Armed Forces Institute of Cardiology/National Institute of Heart Diseases (AFIC/NIHD)/National University of Medical Sciences (NUMS) Rawalpindi Pakistan, *Hamid Latif Hospital, Lahore Pakistan

ABSTRACT

Objective: Experience of the conventional and a de novo Mitral repair techniques for the treatment of Severe Mitral Regurgitation (MR) in a Tertiary Care Cardiac Hospital of Pakistan.

Study Design: Descriptive cross sectional.

Place and Duration of Study: Cardiac Surgical Division, Armed Forces Institute of Cardiology and National Institute of Heart Diseases, Rawalpindi, Pakistan

Methodology: This was a cross sectional study conducted over a period of 5 years from 2016 to 2020, which included Seventy-Five (n=75) patients in the trial, 55 females and 20 males. The mean age was 23±9.5 years (range from 16 to 52 years). Amongst all cases of mitral regurgitation (MR) were five (6%) myxomatous degenerative changes, three (4%) ischemic MR & Sixty-seven (91%) patients had rheumatic aetiology. Five (05) patients with myxomatous diseases required only ring annuloplasty. In patients with ischemic MR, two required chordal shortening for anterior leaflet resuspension, and one required quadrangular resection of the posterior leaflet. Restrictive annuloplasty±Coronary Artery Bypass Grafting (CABG) was also performed as part of the procedures. Sixty-seven (91%) patients having severe Mitral Regurgitation with rheumatic aetiology, required a myriad of procedures; including neo-chordae suspension for anterior & posterior mitral leaflets, quadrangular resection & reattachment of the posterior mitral leaflet. A novel innovative procedure, "Posterior annulus-sliding-plasty" (Nasir's Technique) was adopted in patients with relatively fixed posterior mitral leaflet. Semi-rigid rings (Carbomedics® or Medtronic CG future®) were used in all the patients to stabilize our repair.

Results: There was no operative mortality. Patients were followed up for 01-year. Most of the patients have been found to have adequate intact Mitral Valve Repair. Only 01 patient developed Grade-II MR after 06 months (ischemic aetiology). This patient is being followed up at 06 monthly intervals with transthoracic echo and is being treated as per guideline-directed medical therapy (GMDT) for functional MR.

Conclusion: Mitral Valve Repair in the carefully selected subset of patients with severe MR, irrespective of aetiology can effectively be treated with satisfactory short-term and medium-term results.

Keywords: Mitral valve annuloplasty, Mitral regurgitation, Rheumatic mitral valve disease, Mitral valve repair.

How to Cite This Article: Ali N, Masroor R, Iqbal MA, Hassan SM, Khurshid H, Akram MA. Five Year Experience of in Mitral Valve Repair Surgery at Armed Force Institute of Cardiology. Pak Armed Forces Med J 2022; 72(Suppl-3): S556-560. DOI: <https://doi.org/10.51253/pafmj.v72iSUPPL-3.9552>

This is an Open Access article distributed under the terms of the Creative Commons Attribution License (<https://creativecommons.org/licenses/by-nc/4.0/>), which permits unrestricted use, distribution, and reproduction in any medium, provided the original work is properly cited.

INTRODUCTION

If technically possible mitral valve repair has become the "Gold Standard Treatment" in patients with mitral regurgitation of virtually all etiologies.¹ In the past few decades, there has been a paradigm shift in the management of regurgitant mitral valves. "Earlier the Better" is a new concept in treating asymptomatic severe regurgitation as well as symptomatic patients with preserved LV function.^{2,3} In patients with moderate to severe MR and moderately decreased ventricular function (Ejection Fraction (EF) <60%), the concept that repair of mitral regurgitation might serve to further damage a weakened left ventricle (LV) by eliminating the "pop-off" mechanism has largely changed.^{3,4}

Repair in this is much more urgent because severe decompensation can occur in a matter of months as left ventricular function begins to deteriorate.^{5,6} Mitral valve repair, as opposed to replacement, is now considered the superior treatment.⁷ Better survival, enhanced preservation of Valvular structure & thus LV function, freedom from the hazards associated with anticoagulation therapy, fewer thromboembolic complications,⁸ and minimal risk of endocarditis are distinct advantages of mitral valve repair over mitral valve replacement.⁹⁻¹² The Mitral valve repair program was started in Armed Force Institute of Cardiology/National Institute of Heart Disease in 2011. A UK-based cardiac surgery team headed by Dr Hasnat Khan, a UK-based cardiothoracic surgeon visited AFIC on multiple occasions. Their primary focus was to repair the mitral valve in rheumatic mitral valve disease. A total number of 28 patients were operated on during 04 visits. Early failure (within six months) occurred

Correspondence: Dr Rehan Masroor, Department of Cardiac Surgery and Anaesthesia, Armed Forces Institute of Cardiology/National Institute of Heart Diseases (AFIC/NIHD), Rawalpindi, Pakistan

in 04 patients, who later underwent mitral valve replacement.

METHODOLOGY

The study protocol was presented to the Institutional Ethical Review Board (IERB) Ltr#(9/2/R&D/2022/183) and after discussion, the protocol was approved as there were no ethical or procedural issues identified. After our initial experience and working with foreign faculty a core team including surgeons, anaesthetists and intensive care specialists was formed.

Sample Size: Seventy-Five (n=75) patients were included in the trial, 55 females and 20 males with prevalence of 5.1%.¹²

Inclusion Criteria: Patients with severe mitral regurgitation including myxomatous, ischemic and rheumatic diseases were included in the repair program.

Exclusion Criteria: Patients with multiple valve diseases and those having mixed mitral valve disease - Mitral stenosis (MS)/ Mitral Regurgitation (MR), who are critically ill and the patients who refused to be the part of the study were excluded from the study.

Additional procedures such as Left Atrial (LA) reduction-plasty with an aim to restore sinus rhythm were also carried out in some patients.

Pre-Operative Assessment: Pre-operative assessment with transthoracic and trans-oesophageal echocardiography (TOE) was done by our cardiac anaesthetists, who have a special interest in structural valve pathologies and valve repair surgery. Usually used criterion for acceptability of valve repair includes Moderate to Severe MR or Severe MR (Carpentier’s I/II/IIIa/IIIb), Pathology in A2-P2 Scallop area, Coaptation length of more than 2mm, Coaptation depth less than 1.1cm, Flail gap less than 10mm, Absence of annular calcification, Flail width less than 15mm, Mitral Valve orifice area of more than 3.0 cm², Mobile Leaflet length of more than 1cm, identification of exact scallop of leaflet prolapse or flail, and leaflet thickness. Other findings such as Commissural lesions, Severe Asymmetric tethering, Short Posterior Leaflet, Calcification in the grasping area, Big Clefts, Severe Left Ventricular remodelling, Large (more than 50%) inter-commissural extension of the regurgitant jet, Severe myxomatous degeneration with multi-scallop prolapsed, extensive leaflet and annular calcification, leaflet thickness more than 5mm and small Mitral valve orifice with any element of stenosis were considered unfavorable for valve repair.¹² Table-I shows the key anatomic Eligibility Criterion and unfavorable anatomical

conditions for attempting the Mitral Valve repair or otherwise.

Surgical Technique: A conventional median sternotomy approach was used for initiating cardiopulmonary bypass using central aortic & bi-caval cannulation with exposure to moderate hypothermic (32°C). Antegrade cold blood cardioplegia was used for myocardial protection. The Mitral valve was approached through a superior septal or transeptal approach. A careful examination of the mitral apparatus was carried out. A variety of repair procedures were carried out according to the underlying causative pathology, which included anterior leaflet repair with cusp shortening and re-suspension (either by PTFE Neo-chordae or chordae transfer), posterior leaflet repair with quadrangular resection & leaflet sliding-plasty,⁽¹⁴⁻¹⁶⁾ Figure-1.

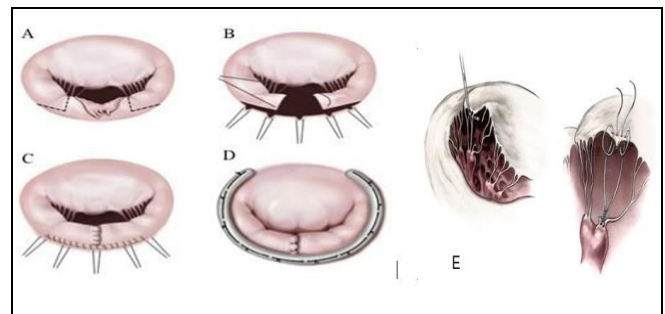


Figure-1: Different Techniques of Mitral Valve Repair: A-D: Steps of Posterior Leaflet Repair: Quadrangular Resection and Sliding Plasty E: Anterior Leaflet Repair Using PTFE suture as Neo-chordae

An additional novel procedure of “posterior annulus-sliding-plasty” (Nasir’s Technique) greatly facilitated repair with a relatively fixed posterior leaflet (Figure-2).

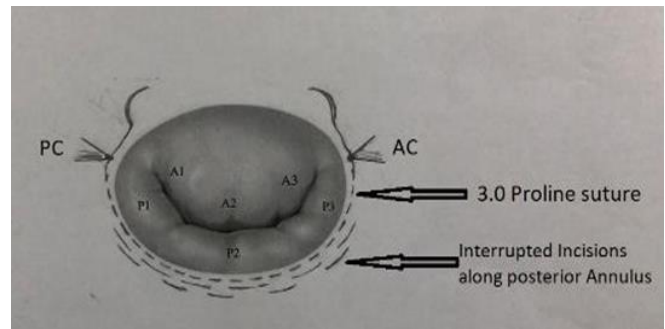


Figure-2: Posterior Annulus-Sliding-Plasty (Nasir’s Technique): The posterior leaflet is used as a trap door against which the Anterior Leaflet abuts forming a new zone of coaptation. The repair was facilitated with Semi-rigid rings used to give stability to our repair

The posterior leaflet was repaired in a way that it will act to stay behind the tip of the anterior leaflet and the anterior leaflet will abut against it. The posterior leaflet is used as a trap-door against which the anterior leaflet abuts forming a new zone of coaptation. Semi-rigid annuloplasty rings were used to give stability to our repair.¹⁷

show any further deterioration in his clinical condition, was managed with anti-failure treatment (goal-directed management) and was advised evaluation by periodic echocardiogram. All other patients showed satisfactory outcomes. Low dose warfarin (INR 1.5-2) was discontinued after six months in a patient with sinus rhythm (n=69). Only six patients required

Table-I: Criterion for eligibility for Mitral Valve repair versus Unfavorable Anatomical conditions prohibiting Mitral Repair

Key Anatomic Eligibility Criterion	Unfavourable Anatomical Conditions
Moderate to Severe MR or Severe MR	Commissural Lesions
Pathology in A2-P2 Region	Short Posterior Leaflet
Coaptation length of more than 2 mm	Severe Asymmetric tethering
Coaptation depth less than 1.1cm	Calcification in the grasping area
Flail gap less than 10 mm	Severe annular calcification
Flail width less than 15mm	Clefts
Mitral Valve orifice area of more than 3.0cm ²	Severe Left Ventricular remodelling
Mobile Leaflet length of more than 1 cm	Large (more than 50%) inter-commissural extension of the regurgitant jet
	Severe myxomatous degeneration with multi-scallop prolapse

RESULTS

Out of the 75 patients included in the study, 55 were females and 20 were male patients. The mean age of the patients was 34±6.5 years. There was no immediate procedure-related mortality recorded. Mean aortic cross-clamp time was (46.5±12.8m) (range 28–72min). The mean cardiopulmonary bypass time was (47.5±14.4 min) (36 to 90min). Patients were ventilated for a period of 6 to 24 hours (Median 12 hours) and the mean stay in the hospital after surgery was 7±2 days. TOE performed after coming off from Cardiopulmonary Bypass (CBP) confirmed the success of the repair. Only Five (n=5,6.6%) patients needed to go back on CBP to address moderate MR, which was corrected satisfactorily.

During the Early post-operative period, there was no early death. Three patients were readmitted within ten days from discharge with one of them requiring pericardial drainage and the other two patients developed left-sided pleural collection requiring pleural aspiration.

The patients were followed up for 01-year post-Mitral Valve Repair. Transthoracic Echocardiography was performed at the time of discharge for every patient and the Mitral Valve Area by Planimetry as well as Continuity Equation (VTi) method, Mean PG as well as the presence of any residual MR were documented. Afterwards, follow-up was performed at 03 months, 06 months and 01-year intervals after surgery and all the above-mentioned parameters were recorded. One patient with ischemic MR developed moderate MR (MR II) after six months. He did not

warfarin in therapeutic dose (INR 2.5-3.5) due to persistent or intermittent atrial fibrillation.

DISCUSSION

The history of mitral valve repair goes back as early as the 1st quarter of the 20th century. It is recorded that Dr. Elliot Carr Custler, performed 1st mitral valve repair at Brigham Hospital Boston as early as 1923.¹ He performed a trans-ventricular mitral valve commissurotomy with a neurosurgical tenotomy knife on a critically ill 12-year-old girl. It was considered a great success at that time.

Mitral valve repair is now considered a Gold Standard Surgical technique in patients with degenerative mitral valve diseases with significant MR. Society of Thoracic Surgeons’ database interrogation indicates that the success of mitral valve repair in degenerative disease is as high as 75% interior word.⁶ In patients with rheumatic heart disease, however, mitral valve replacement has been traditionally considered the preferred procedure.¹⁸ In the past two decades, there has been a considerable improvement in the success rate of initial repair in RHD, i.e. from 25% in experienced centres to 69%.¹⁹⁻²¹ Intra-operative transoesophageal echocardiography has actually revolutionized mitral valve surgery. More and more cardiac anaesthetists have now been trained to conduct TOR intra-op.²² The availability of TOE monitoring pre and post-repair in an operation theatre has contributed to the great success we have had over a period of last 5 years or so. A number of procedures which were carried out in the past where no TOE was used, the success rate was found to be less. However, after the

ADULT CARDIAC SURGERY/
ANAESTHESIA

introduction of the Intra op TOE, now we can assess the exact pathology and quantify the severity, and after the repair correct any residual MR if necessary.

The Mitral valve repair program started at AFIC/NIHD in 2012, with facilitation by a UK-based team led by Mr. Hasnat Khan (Consultant Cardio-thoracic Surgeon, currently Head of Cardio-Thoracic Surgery at King Faisal Heart centre).

We have performed 28 repair procedures in one year's time. All the patients were having rheumatic valve diseases and the surgery was performed by the local surgeons using the above-mentioned techniques with a very good success rate.

Our experience and expectations in mitral valve repair grew with time. A core team including a surgeon, and a cardiac anaesthetist with a special interest in valve repair & echocardiography was formed. Initial, early & later failures leading to redo valve replacement surgeries lead to a deep insight into our case selection criteria & surgical technique in the initial period of 4-5years time. Our confidence in valve repair surgery grew gradually, as we developed our institutional guidelines and a few innovations for a sustained & predictable valve repair surgery in the rheumatic population.

LIMITATIONS OF STUDY

Our experience of Mitral valve repair surgery especially in Rheumatic Mitral Valve disease is satisfactory, However, further studies and follow-up are required to ascertain the long-term freedom from recurrent MR and reoperation, particularly for those with rheumatic valvular lesions.

CONCLUSION

Mitral valve repair for the regurgitant valve has now been recognized as the "Procedure of Choice" for mitral valve pathology of virtually all etiologies. A dedicated team consisting of the surgeon and cardiac anaesthetist with a special interest in valve repair and echocardiography is highly recommended. Early results of mitral valve repair surgery in mitral regurgitation due to rheumatic heart disease at our institution are encouraging.

ACKNOWLEDGEMENT

I am grateful to my friends and family who supported me throughout this project. I also want to share my gratitude towards Comdt/Executive Director AFIC and HoD R&D for their support. I am thankful to R&D Department for guiding me.

Conflict of Interest: None.

Author's Contribution

Following authors have made substantial contributions to the manuscript as under:

NA: Concept, study design, data collection

RM: Manuscript writing, statistical analysis & interpretation

MAI: Critical review, intellectual contribution and final approval

SMH: Critical revision, statistical analysis and interpretation

HK: Statistical analysis and Manuscript writing, and interpretation

MAA: Data collection, analysis and critical review

Authors agree to be accountable for all aspects of the work in ensuring that questions related to the accuracy or integrity of any part of the work are appropriately investigated and resolved.

REFERENCES

1. Lawrance H, David C, Adams H. Cardiac surgery in the Adults. McGraw-Hill publication 2018; 35(5): 797-800.
2. Kang DH, Kim JH, Rim JH. Comparison of early surgery versus conventional treatment in asymptomatic severe mitral regurgitation. *Circulation* 2019; 119(1): 797-800.
3. Enriquez-Sarano M, Nkomo V, Mohty D, Avierios JE, Chalili H. Mitral regurgitation; predictors of outcome and natural history. *Adv Cardiol* 2002; 39(1): 133-143.
4. Harky A, Hof A, Garner M, Froghi S. Mitral valve repair or replacement in native valve endocarditis? Systematic review and meta-analysis. *Journal of Cardiac Surgery* 2018; 33(1): 364-371.
5. Tribouilloy C, Rusinaru D, Grigioni F. Long term mortality associated with left ventricular dysfunction in mitral regurgitation due to flail leaflets; a multicenter analysis. *Circ Cardiovascular Imaging* 2014; 7(2): 363-370.
6. Lawrance H, Cohan, David H Adams, Cardiac surgery in the Adults. McGraw-Hill publication 2018; 35(5): 801.
7. Enriquez-Sarano M, Nkomo V, Mohty D, Avierios JE, Chalili H. Mitral regurgitation; predictors of outcome and natural history. *Adv Cardiol* 2002; 39(1): 133-143.
8. Akins CW, Hilgenberg AD, Buckley MJ, Vlahakes GJ, Torchiana DF, Daggett WM, et al. Valve reconstruction versus replacement for degenerative or ischemic mitral regurgitation. *Ann of Thoracic Surg* 1994; 58(1): 668-676.
9. Russo A, Grigioni F, Avierios JF. Thromboembolic complications after surgical correction of mitral regurgitation incidence, predictions, and clinical implications; *J Am Coll Cardiol* 25 2008; 51(12): 1203-1211.
10. Ling LH, Enriquez-Sarano M. Clinical outcome of mitral regurgitation due to flail leaflet. *N Engl J Med* 1996; 335(1): 1417
11. Tribouilloy C, Rusinaru D, Grigioni F. Long-term mortality associated with left ventricular dysfunction in mitral regurgitation due to flail leaflets: a multicenter analysis. *Circulation Cardiovascular Imaging* 2014; 7(2): 363-370.
12. Antunes MJ. Repair of rheumatic mitral valve regurgitation; how far can we go? *Eur J Cardio Surg* 2013; 44(4): 689-691.
13. Kongsarepong V, Shiota M. Echocardiographic predictors of successful versus unsuccessful mitral valve repair in ischemic mitral regurgitation. *Am J Cardiology* 2006; 98(4): 504-508.
14. David TE, David CM, Tsang W, Lafreniere-Roula M, Manlhiot C. Long-term results of mitral valve repair for regurgitation due to leaflet prolapse. *Journal of the American College of Cardiology* 2019; 74(8): 1044-1053.
15. Perier P, Clausnizer B, Mistras K. Carpentires "sliding leaflet" technique for repair of mitral valve. Early results, *Ann of thoracic surgery* 1994; 57(1): 383.

Experience of Mitral Valve Repair Surgery

16. David TE, Armstrong S, Ivanov J; Chordal replacement with PTFE sutures for mitral valve repair; a 25 year experience. *J Thoracic Cardiovascular Surg* 2013; 145(6): 1563-1569.
 17. Gillino AM, Tanti wong kosrik, Blackstone etal; Is Prosthetic annuloplasty necessary for durable mitral valve repair. *Ann Thoracic surg* 2009; 88(1): 76
 18. Lawrance H Cohon, David H Adams, *Cardiac surgery in the Adults*. McGraw-Hill publication 2018; 36(5): 823.
 19. Deferm S, Bertrand PB, Verhaert D, Dauw J, Van Keer JM, Van De Bruaene A, et al. Outcome and durability of mitral valve annuloplasty in atrial secondary mitral regurgitation. *Heart* 2021; 107(18): 1503-1509.
 20. Kumar AS, Talwar S, Saxana A, Sinc R, Velyoudam D. Results of mitral valve repair in rheumatic mitral regurgitation. *Interact Cardiovas Thoracic Surg* 2006; 5(4): 356-336
 21. Enriquez-Sarano M, Nkomo V, Mohty D, Aviernos JE, Chalili H: Mitral regurgitation; predictors of outcome and natural history. *Adv Cardiol* 2002; 39(1); 133-143.
 22. Kasegawa H, Shimizu A, Fukui T, Takanashi S, Shimokawa T. Mitral valve repair for extreme billowing and prolapsing valve. *JTCVS Open* 2022; 10: 169-175.
-