

Effects of Vitamin D on the Histomorphology of Norethisterone-Induced Hepatosteatosi s in Female Rats

Asima Tabassum, Muhammad Rizwan Bashir Kiani, Aqsa Zahid, Saadia Rashid*, Faiza Umbreen, Irum Zakria**

Army Medical College/National University of Medical Science (NUMS) Rawalpindi Pakistan, *Foundation University Medical College Islamabad Pakistan, **Heavy Industries Taxila Education City, Institute of Medical Sciences (HITEC-IMS) Taxila/National University of Medical Science (NUMS) Pakistan

ABSTRACT

Objective: To evaluate the histomorphological effects of Vitamin D on Norethisterone-induced hepatosteatosi s in female rats.

Study Design: Laboratory-based experimental study.

Place and Duration of Study: Department of Anatomy, Army Medical College/National University of Medical Sciences Rawalpindi in collaboration with the National Institute of Health (NIH), Pathology Laboratory Pak Emirates Military hospital, and Armed Forces Institute of Pathology, (AFIP) Rawalpindi Pakistan, from Aug to Nov 2021.

Methodology: Thirty female Sprague Dawley rats weighing 250-300 gm were randomly divided into three groups (10 for each group). Group-A served as control. For eight weeks, Group-B was given Norethisterone 4.55 mg/kg/day by oral gavage. Group-C was given 1000 IU/kg/day of Vitamin D by intraperitoneal injection for five consecutive days/week, along with Norethisterone for eight weeks. All the animals were sacrificed at the end of the experiment. The colour and consistency of the liver specimen were noted. Liver specimens were processed and staining was done with H & E stains. Histologically steatosi s in the specimen was assessed.

Results: The results were compared among the groups. Experimental Group-B, when compared with Control Group-A, showed a significant change in the colour (p -value 0.033) and consistency of the liver (p -value 0.033) along with marked steatosi s (p -value 0.001). There was a significant improvement in hepatosteatosi s (p -value 0.001), which led to improved colour (p -value 0.029) and consistency of the liver (p -value 0.029) in Experimental Group-C when compared with Experimental Group-B.

Conclusion: Vitamin D ameliorates hepatosteatosi s induced by Norethisterone in the female rat.

Keywords: Hepatosteatosi s, Hepatotoxicity, Norethisterone, Vitamin D.

How to Cite This Article: Tabassum A, Kiani MRB, Zahid A, Rashid S, Umbreen F, Zakria I. Effects of Vitamin D on the Histomorphology of Norethisterone-Induced Hepatosteatosi s in Female Rats. *Pak Armed Forces Med J* 2022; 72(5): 1816-1820. DOI: <https://doi.org/10.51253/pafmj.v72i5.8658>

This is an Open Access article distributed under the terms of the Creative Commons Attribution License (<https://creativecommons.org/licenses/by-nc/4.0/>), which permits unrestricted use, distribution, and reproduction in any medium, provided the original work is properly cited.

INTRODUCTION

Sex hormones strongly affect vital organs of the human body, such as the liver, which is the main organ responsible for maintaining the body's internal environment,¹ through their receptors expressed in the liver.² In the last 30 years, there has been much development in using different formulations of synthetic steroid sex hormones for many endocrinologic and gynecologic problems.³ Norethisterone is a first-generation synthetic progestin registered for treating many such disorders as contraception, dysfunctional uterine bleeding, menorrhagia, breast cancer, menstrual postponement, ovarian cysts, and adenomyosis.⁴ Although the use of these sex hormones has tremendously reduced the incidence of health-related issues like unsafe abortions and maternal deaths, there is still a need to look into the long-term effects of these steroid sex hormones on vital organs of the human body, such

as the liver.¹

The predominant cause of different public health issues globally is liver disease. According to WHO, Pakistan has the highest rate of steatohepatitis after Egypt.⁵ Currently, more than a hundred medications, including synthetic steroid sex hormones, are known to cause fatty change impairments of the liver. While immunosuppressant drugs and liver transplantation are presently available as therapeutic options for hepatitis, they are not considered optimal.⁶ These findings illustrate the basic requirement for understanding pathophysiological changes in hepatic damage and the need to establish an effective therapy for liver impairments caused by hepatotoxic agents.⁷

Thus, demonstrating a more effective and safe natural compound to protect against liver injuries induced by steroid sex hormones, including Norethisterone, is a promising area for research. Furthermore, the molecular mechanism of the protective effect of Vitamin D may involve the prevention of increased levels of highly damaging mediators of oxidative

Correspondence: Dr Asima Tabassum, Department of Anatomy Army, Medical College, Rawalpindi, Pakistan

Received: 09 May 2022; revision received: 27 Jul 2022; accepted: 29 Jul 2022

Histomorphology of Norethisterone-Induced

stress.⁸ Experimental studies have also shown that Vitamin D supplementation produces hepato-protective effects in drug-induced steatohepatitis by increasing the endogenous levels of antioxidants and anti-inflammatory molecules.⁹ Many studies have recently been conducted in which Vitamin D was used as a protective agent against drug toxicity in various organs, including the liver.¹⁰ However, the synthetic steroid sex hormone, Norethisterone, and Vitamin D as protective agents against steatohepatitis have not been studied. Therefore, the current study sought to assess the protective effects of Vitamin D on hepatosteatosis caused by synthetic steroid sex hormones such as Norethisterone.

METHODOLOGY

This was a laboratory-based experiment study conducted at the Department of Anatomy, Army Medical College/National University of Medical Sciences Rawalpindi in collaboration with the National Institute of Health (NIH), Pathology Laboratory Pak Emirates Military hospital, and Armed Forces Institute of Pathology (AFIP) Rawalpindi Pakistan, from August to November 2021. All animal care and handling procedures were performed after getting approval from the Ethics Committee of Army Medical College/National University of Medical Sciences, Rawalpindi (Letter no. ERC/ID/130).

Inclusion criteria: Thirty female Sprague Dawley rats, 2-3 months of age, weighing 250-300gm, obtained from NIH Islamabad, were included consecutively in the study.

Exclusion criteria: Female rats with obvious deformities and male rats were not included in the study.

Rats (10 per cage) were kept at the animal house under standard laboratory conditions with a temperature of 21±2 C and a 12-hour light/dark cycle. The animals were fed on standard laboratory rat chow and water *ad libitum*. Rats were randomly divided into three groups, each having ten rats. In Group-A (Control Group), no intervention was done in this group. Group-B (Experimental Group) received Norethisterone 4.55 mg/kg/day by oral gavage for eight weeks. Group-C (Experimental Group) received Norethisterone 4.55 mg/kg/day by oral gavage for eight weeks, along with the intraperitoneal injection of Vitamin D 1000 IU/kg/day for five consecutive days/week for eight weeks.

At the end of the experiment (8 weeks), all the animals were euthanized. Then dissection was done to

remove the liver from the abdominal cavity. The colour and consistency of the fresh liver specimen were noted. The entire liver was placed in a 10% formalin solution. Transverse liver sections of 5-micrometre thickness were obtained using a rotary microtome. Sections were then stained with H & E stains for the detection of steatosis in the liver specimens. Steatosis was observed in four randomly selected fields under the 40X objective in each slide. Grading was done as: 0 = Absent or <5% hepatocytes with lipid vacuoles, 1 = Mild (lipid vacuoles are present in 5%-30% of hepatocytes), 2 = Moderate (lipid vacuoles are present in 31%-60% of hepatocytes), 3 = Marked (lipid vacuoles are present in more than 60% of hepatocytes).

Data were analyzed using Statistical Package for Social Sciences version 22. Qualitative variables were presented by frequency and percentage. The chisquare test, and fisher's exact test, were applied to compare qualitative variables. The *p*-value ≤0.05 was considered significant.

RESULTS

Immediately after the dissection of rats, fresh liver specimens were observed for the colour of the liver. In all 10(100%) animals belonging to Control Group- A, the colour of the liver was normal, reddish brown. In Experimental Group-B, 5(50%) livers were reddish brown, and 5(50%) were pale brown. In Experimental Group-C, 8(80%) livers were reddish brown, and 2 (20%) were pale brown, as shown in Table-I. Intergroup comparison showed significant results when Group-C and Group-A were compared with Group-B with *p*-values of 0.029 and 0.033, respectively. However, the result was statistically insignificant when Group-C was compared with Group- A (*p*-value 0.474).

Table- I: Intergroup comparison for colour of liver in control Group-A and Experimental Groups B and C

Parameters	Gross Findings	Group-A (n =10)	Group-B (n =10)	Group-C (n =10)
Colour of Liver	Reddish Brown	10(100%)	5(50%)	8(80%)
	Pale Brown	-	5(50%)	2(20%)
Parameters	C vs A	C vs B	A vs B	
Colour of liver (<i>p</i> -value)	0.474	0.029*	0.033*	

After the dissection of rats, the consistency of fresh liver specimens was also observed. It was noted that the liver of all 10(100%) animals in Control Group-A were soft in consistency. While in Experimental Group-B, 5(50%) livers were soft, and 5(50%) were relatively harder in consistency. In Experimental

Histomorphology of Norethisterone-Induced

Group-C, 8(80%) livers were soft, and 2(20%) were relatively harder in consistency, as shown in Table-II. Intergroup comparison showed significant results only when Group-C and Group-A were compared with group B with *p*-values of 0.029 and 0.033, respectively. The comparison between Group-C and Group-A showed an insignificant result (*p*-value 0.474).

Table- II: Intergroup comparison for consistency of liver in Control Group-A and Experimental Groups B and C

Parameters	Gross Findings	Group-A (n =10)	Group-B (n =10)	Group-C (n =10)
Consistency of liver	Soft	10(100%)	5(50%)	8(80%)
	Relatively harder	-	5(50%)	2(20%)
	Nodular	-	-	-
Parameter	C vs A	C vs B	A vs B	
Consistency of liver (<i>p</i> -value)	0.474	0.029*	0.033*	

Fat deposition (steatosis) in the liver was also established in the study. The H & E staining demonstrated this fat deposition as vacuolation of hepatocytes. The grading of hepatosteatosis was analyzed (Figure). Control Group-A showed all 10(100%) normal liver specimens with no steatosis. In Experimental Group- B, 2(20%) liver specimens were normal, 3(30%) revealed Grade-1 (mild) steatosis and 5(50%) showed Grade-2 (moderate) steatosis. On the other hand,

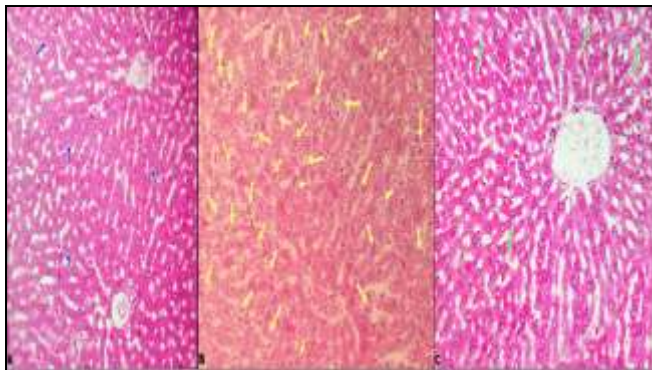


Figure: Photomicrograph Showing Comparison of Hepatic Steatosis in Control Group-A and Experimental Groups B and C. H & E stain. X400

- Liver section of Control Group-A (animal A2) showing hepatocytes with central nucleus and normal cytoplasm with absent lipid vacuoles (blue arrows).
- Liver section of Experimental Group-B (animal B1) showing moderate steatosis with increased number of hepatocytes having lipid vacuoles (yellow arrows).
- Liver section of Group-C (animal C8) showing marked reduction in steatosis with only a few hepatocytes having lipid vacuoles (green arrows)

Experimental Group-C showed 8(80%) normal specimens and only 2(20%) liver specimens with Grade-1 (mild) steatosis, as shown in Table-III. Multiple group comparisons yielded highly significant results (*p*-value 0.001) when the comparison between Groups C and B was made. At the same time, there was a statistically insignificant difference between Groups C and A (*p*-value 0.474).

Table-III: Intergroup Comparison for Steatosis of Liver in Control Group-A and Experimental Groups B and C

Parameters	Histological Findings	Group-A (n =10)	Group-B (n =10)	Group-C (n =10)
Steatosis	Grade 0	10(100%)	2(20%)	8(80%)
	Grade 1	-	3(30%)	2(20%)
	Grade 2	-	5(50%)	-
Parameters	C vs A	C vs B	A vs B	
Steatosis (<i>p</i> -value)	0.474	0.001**	0.001**	

DISCUSSION

Synthetic steroid sex hormones greatly affect the quality of life among females by disrupting body weight regulation,^{11,12} glucose metabolism, and general homeostatic regulations due to their effects on the liver.^{13,14} Now there are insinuations that many women have stopped using these synthetic sex hormones, including Norethisterone, due to their effects on the liver and many other side effects on their health.¹⁵⁻¹⁷ So there is a need to find an effective and safe natural compound that can be used as a supplement along with these synthetic steroid sex hormones to undo their hepatotoxic effects. Vitamin D can be used as a supplement due to its anti-inflammatory and anti-steatotic effects on several body organs.¹⁸ In the present study, female rats were injected with Vitamin D to evaluate its effects on the liver.

In the current study, regarding the gross appearance, livers belonging to Control Group-A were reddish brown and soft in consistency, reflecting features of a normal liver.¹⁹ Contrary to this, Experimental Group-B showed a significant change in colour and consistency. In Experimental Group-B, steatosis in the liver changes its colour from reddish brown to pale brown due to retained carotenes.²⁰ The change in consistency from soft to relatively harder was also due to lipid accumulation in the liver parenchyma. This was in accordance with a study conducted by Wang and his colleagues.⁹ On the other hand, when Vitamin D was given along with Norethisterone in Experimental Group-C, there was a significant improvement

in the colour and consistency of the liver. In Experimental Group-C, Vitamin D mainly reduced the incidence of fatty change in the liver, reflected in a soft liver with a reddish brown colour.²¹ Mazzone and his fellows also studied the same effects of Vitamin D on the liver,²² in their research on rats taking a western diet which leads to fatty infiltration in the liver. They also observed that more livers were soft and reddish brown due to Vitamin D supplementation. Nevertheless, their study results were not statistically analysed; they were just macroscopically observed. In the present study, we statistically evaluated the marked improvement in colour and consistency of the liver due to intraperitoneal injection of Vitamin D in Experimental Group-C animals.

Histologically a highly significant steatotic change was also observed in Experimental Group-B. Prolonged use of Norethisterone, as in the present study, mainly through interaction with progesterin receptors, leads to impaired lipid metabolism,²³ increased bile acid production, cholestasis, and impaired antioxidant defences.²⁴ The resultant oxidative stress leads to cellular damage via lipid peroxidation and causes steatotic change within hepatocytes.⁹

On the other hand, there was a marked reduction in the development of steatotic change in the liver of Experimental Group-C. This showed the preventive role of Vitamin D in the establishment of steatohepatitis. This effect of Vitamin D was in accordance with a study,²⁰ in which the Vitamin D preventive group showed a significant reduction in hepatic steatosis in mice on the highfat diet. Vitamin D was given for a short period, twice a week.

However, the present study showed a highly significant reduction in steatosis in Experimental Group-C either due to prolonged use of Vitamin D along with Norethisterone or its daily dosage. Secondly, this study also showed the preventive role of Vitamin D against drugs, specifically sex hormone-induced steatohepatitis, which was not previously observed.

CONCLUSION

The present study concluded that the synthetic steroid sex hormone, Norethisterone affects the histomorphology of the liver, causing marked steatotic change, which makes the liver pale brown and relatively harder. Supplementation with Vitamin D had marked ameliorative effects on these parameters. Thus, this study supports that Vitamin D has a hepatoprotective effect against Norethisterone-induced fatty change in the liver.

ACKNOWLEDGEMENT

The authors are highly thankful to the officers and staff at NIH and AMC (NUMS) for their facilitation and support. We are highly indebted to the National University of Medical Science for providing a grant for this project.

Conflict of Interest: None.

Author's Contribution

Following authors have made substantial contributions to the manuscript as under:

AT: Conception, Study design, drafting the manuscript, approval of the final version to be published.

MRBK: Critical review, drafting the manuscript, approval of the final version to be published.

AZ & SR: Data acquisition, data analysis, critical review, approval of the final version to be published.

FU & IZ: Drafting the manuscript, data interpretation, critical review, approval of the final version to be published.

Authors agree to be accountable for all aspects of the work in ensuring that questions related to the accuracy or integrity of any part of the work are appropriately investigated and resolved.

REFERENCES

1. Huvinen E, Holopainen E, Heikinheimo O. Norethisterone and its acetate-what's so special about them? *BMJ Sex Reprod Health* 2021; 47(2): 102-109. doi: 10.1136/bmjsex-2020-200619.
2. Soria-Jasso LE, Cariño-Cortés R, Muñoz-Pérez VM, Pérez-Hernández E, Pérez-Hernández N. Beneficial and Deleterious Effects of Female Sex Hormones, Oral Contraceptives, and Phytoestrogens by Immunomodulation on the Liver. *Int J Mol Sci* 2019; 20(19): 4694. doi: 10.3390/ijms20194694.
3. Martin U, Foreman MA, Travis JC, Casson D, Coleman JJ. Use of ACE inhibitors and ARBs in hypertensive women of child-bearing age. *J Clin Pharm Ther* 2008; 33(5): 507-511.
4. Pool ER, Bolache S, Wood C. A rare case of norethisterone-related drug-induced liver injury. *Br J Hosp Med (Lond)* 2019; 80(8): 476-477. doi: 10.12968/hmed.2019.80.8.476.
5. Bick AJ, Louw-du Toit R, Skosana SB, Africander D, Hapgood JP. Pharmacokinetics, metabolism and serum concentrations of progestins used in contraception. *Pharmacol Ther* 2021; 222(1): 107789. doi: 10.1016/j.pharmthera.2020.107789.
6. Fernández-Martínez E. Cholestasis, Contraceptives, and Free Radicals. *Liver Pathophysiology*: Elsevier; 2017, Available at: https://www.researchgate.net/publication/312447721-Cholestasis_contraceptives_and_free_radicals_In_Liver_Pathophysiology_Therapies_and_Antioxidants_Editor_Pablo_Academic_Press
7. Konings G, Brentjens L, Delvoux B, Linnanen T. Intracrine Regulation of Estrogen and Other Sex Steroid Levels in Endometrium and Non-gynecological Tissues; Pathology, Physiology, and Drug Discovery. *Front Pharmacol* 2018; 9(1): 940-945.
8. Mushtaq A, Aslam B, Muhammad F, Khan JAJPVJ. Hepatoprotective Activity of *Nigella sativa* and *Piper nigrum* against Concanavalin A-Induced Acute Liver Injury in Mouse Model. *Pak Veterinary J* 2021; 41(1). doi:10.29261/PAKVEIJ/2020.076
9. Wang X, Tan Z, Chen S, Gui L, Li X, Ke D, et al. Norethindrone causes cellular and hepatic injury in zebrafish by compromising the metabolic processes associated with antioxidant defence: Insights from metabolomics. *Chemosphere* 2021; 275(1): 130049.

Histomorphology of Norethisterone-Induced

10. Abid A, Subhani F, Kayani F, Awan S, Abid S. Drug induced liver injury is associated with high mortality-A study from a tertiary care hospital in Pakistan. *PLoS One* 2020; 15(4): e0231398. doi: 10.1371/journal.pone.0231398.
11. Sucher E, Sucher R, Gradistanac T, Brandacher G, Schneeberger S, Berg T. Autoimmune Hepatitis-Immunologically Triggered Liver Pathogenesis-Diagnostic and Therapeutic Strategies. *J Immunol Res* 2019; 2019: 9437043. doi: 10.1155/2019/9437043.
12. Sepidarkish M, Farsi F, Akbari-Fakhrabadi M, Namazi N, Almasi-Hashiani A, Maleki Hagiagha A, et al. The effect of vitamin D supplementation on oxidative stress parameters: A systematic review and meta-analysis of clinical trials. *Pharmacol Res* 2019; 139: 141-152. doi: 10.1016/j.phrs.2018.11.011.
13. El-Boshy M, BaSalamah MA, Ahmad J, Idris S, Mahbub A, Abdelghany AH, et al. Vitamin D protects against oxidative stress, inflammation and hepatorenal damage induced by acute paracetamol toxicity in rat. *Free Radic Biol Med* 2019; 141: 310-321. doi: 10.1016/j.freeradbiomed.2019.06.030.
14. Deb S, Reeves AA, Lafortune S. Simulation of Physicochemical and Pharmacokinetic Properties of Vitamin D3 and Its Natural Derivatives. *Pharmaceuticals (Basel)* 2020; 13(8): 160. doi: 10.3390/ph13080160.
15. Gambineri A, Pelusi C. Sex hormones, obesity and type 2 diabetes: is there a link? *Endocr Connect* 2019;8(1):R1-R9. doi: 10.1530/EC-18-0450.
16. Kowalska K, Ściskalska M, Bizoń A, Śliwińska-Mossoń M, Milnerowicz H. Influence of oral contraceptives on lipid profile and paraoxonase and commonly hepatic enzymes activities. *J Clin Lab Anal* 2018; 32(1): e22194. doi: 10.1002/jcla.22194.
17. Afolabi SO, Folahan J, Agede O, Olorundare O. Combined Intranasal Insulin/Saxagliptin/Metformin Therapies Ameliorate the Effect of Combined Oral Contraceptive- (COC-) Induced Metabolic Syndrome (MetS) with a Major Target on Glucose Metabolism in Adult Female Wistar Rats. *Int J Reprod Med* 2021; 2021: 9693171. doi: 10.1155/2021/9693171.
18. Dong B, Zhou Y, Wang W, Scott J, Kim K, Sun Z, et al. Vitamin D Receptor Activation in Liver Macrophages Ameliorates Hepatic Inflammation, Steatosis, and Insulin Resistance in Mice. *Hepatology* 2020; 71(5): 1559-1574. doi: 10.1002/hep.30937.
19. Eliassen K, Patursson EJ, McAdam BJ, Pino E, Morro B, Betancor M, et al. Liver colour scoring index, carotenoids and lipid content assessment as a proxy for lumpfish (*Cyclopterus lumpus* L.) health and welfare condition. *Sci Rep* 2020; 10(1): 8927.
20. Clugston RD. Carotenoids and fatty liver disease: Current knowledge and research gaps. *Biochim Biophys Acta Mol Cell Biol Lipids* 2020; 1865(11): 158597. doi: 10.1016/j.bbalip.2019.158597.
21. Derakhshanian H, Djalali M, Mohammad Hassan MH, Alvandi E, Eshraghian MR, Mirshafiey A, et al. Vitamin D suppresses cellular pathways of diabetes complication in liver. *Iran J Basic Med Sci* 2019; 22(6): 690-694.
22. Mazzone G, Morisco C, Lembo V, D'Argenio G. Dietary supplementation of vitamin D prevents the development of western diet-induced metabolic, hepatic and cardiovascular abnormalities in rats. *United European Gastroenterol J* 2018; 6(7): 1056-1064. doi: 10.1177/2050640618774140.
23. Jiang Y, Tian W. The effects of progesterones on blood lipids in hormone replacement therapy. *Lipids Health Dis* 2017; 16(1): 219. doi: 10.1186/s12944-017-0612-5.
24. Jahn D, Dorbath D, Kircher S, Nier A, Bergheim I, Lenaerts K, et al. Beneficial Effects of Vitamin D Treatment in an Obese Mouse Model of Non-Alcoholic Steatohepatitis. *Nutrients* 2019; 11(1): 77. doi: 10.3390/nu11010077.