

## Histopathological Outcome of Oral Lesions in Pakistani Population with Special Emphasis on Oral Cancer

Amna Waheed, Tariq Sarfraz, Fatima Kaleem, Rubina Riaz

Foundation University Medical College, Islamabad Pakistan

### ABSTRACT

**Objective:** To evaluate varying histopathological outcomes of oral lesions in different age groups and locations of the lesions, with special emphasis on oral cancer.

**Study Design:** Cross-sectional study.

**Place and Duration of Study:** Histopathology Department, Foundation University Medical College Islamabad Pakistan, from May 2019 to May 2021.

**Methodology:** A total of 99 cases of oral lesions which were biopsied and were adequate in size were included in the study. Biopsies were evaluated histologically for non-neoplastic, neoplastic and premalignant lesions about age, nature and location of the lesions. Data collection was through Medix Online Histopathology Reporting System (MOHRS).

**Results:** A total of 99 cases were included in the study, out of which 41 cases (41.4%) were non-neoplastic, 56 cases (56.6%) were neoplastic, and 2 cases (2.0%) were premalignant lesions. Out of 41 non-neoplastic lesions, the majority were inflammatory (14 cases), followed by fibroepithelial polyps (5 cases), pyogenic granulomas (4 cases), and hyperplasia (3 cases). Out of 56 neoplastic lesions, 39 (69.6%) were confirmed as carcinomas, squamous cell carcinoma being the most common malignancy in 29 cases (74.3%), followed by verrucous carcinoma in 5 cases (12.8%). In addition, there were two cases (11.7%) of potentially premalignant lesions. Buccal mucosa and tongue were more predominant sites of oral pathologies than other sites.

**Conclusion:** In our setup, most of the oral lesions evaluated histologically turn out to be neoplastic and that too malignant, mostly squamous cell carcinomas. Most of the oral lesions occur in the fifth and sixth decade. Buccal mucosa and tongue are the most sites of oral lesions. Therefore, the biopsy is a useful tool in diagnosing suspicious lesions.

**Keywords:** Biopsy, Histopathology, Non-neoplastic, Neoplastic, Oral lesions, Premalignant, Squamous cell carcinoma.

**How to Cite This Article:** Waheed A, Sarfraz T, Kaleem F, Riaz R. Histopathological Outcome of Oral Lesions in Pakistani Population with Special Emphasis on Oral Cancer. *Pak Armed Forces Med J* 2022; 72(4): 1433-1438. DOI: <https://doi.org/10.51253/pafmj.v72i4.8577>

---

This is an Open Access article distributed under the terms of the Creative Commons Attribution License (<https://creativecommons.org/licenses/by-nc/4.0/>), which permits unrestricted use, distribution, and reproduction in any medium, provided the original work is properly cited.

---

### INTRODUCTION

Oral cancer is one of the ten most common malignancies worldwide. The most prevalent type, according to histopathology, is Oral Squamous Cell Carcinoma.<sup>1</sup> There were 53,000 newly diagnosed cases and 10,860 deaths owing to oral and pharyngeal cancer in the United States of America, recorded by the National Cancer Institute's Surveillance, Epidemiology and End Results (SEER) program in 2019.<sup>2</sup> Most malignant lesions are diagnosed at a later stage with complications and/or metastasis, leading to a poor prognosis. The five-year survival rate, when diagnosed at an earlier stage (stage I and II), is 84%, which drops down to 45% and 32% when diagnosed at a later stage (stage III and IV, respectively), which is the most common stage at which oral and pharyngeal cancer is diagnosed.<sup>2,3</sup>

Mitigation of cancerous lesions of the oral cavity depends largely on the identification of various pre-

malignant conditions that can proceed to squamous cell carcinoma. Decreasing the risk involves prompt diagnosis and management of potentially malignant disorders, which is how oral cancer can be prevented.<sup>4</sup> Premalignant or potentially premalignant oral epithelial lesions encompass all those oral lesions with a high propensity to be malignant from both clinical and histopathological perspectives. These include oral epithelial dysplasia, leukoplakia, erythroleukoplakia, oral submucous fibrosis and lichen planus.<sup>5</sup> Clinically, many oral mucosal lesions, including benign, premalignant, and malignant, present in the form of a white patch (leukoplakia) with or without redness (erythroleukoplakia). Lesions clinically visible as areas of redness only (erythroplakia) speckled or homogenous have an increased chance of becoming malignant after some time. Oral mucosal lesions may follow different series of changes. They may decrease or increase in size, arise in a different oral cavity location, or resolve completely. It depends on various factors, like age, associated risk factors and habits. It has been seen that lesions in patients over 50 years of age, having an

---

**Correspondence:** Dr Tariq Sarfraz, Head of Histopathology Dept, Foundation University Medical College, Islamabad, Pakistan  
Received: 18 Apr 2022; revision received: 04 Jul 2022; accepted: 06 Jul 2022

additional risk factor of smoking, have more chances of developing malignancy. The histological presence of epithelial dysplasia has a strong predisposition toward oral cancer. Similarly, lesions on the mouth and tongue floor also increase the chance of being malignant.<sup>6</sup>

History and a thorough clinical examination of any oral mucosal lesion are necessary to identify an oral lesion. However, it does not specifically recognize it as dysplastic, carcinoma in situ or invasive oral cancer, nor does it provide adequate information in risk assessment and treatment plans for premalignant and malignant conditions of the oral cavity. Oral examination can only differentiate between a benign lesion with inflammatory aetiology from a suspicious lesion that is likely to become malignant.<sup>6</sup> Often a thorough clinical oral examination by the maxillofacial surgeon is enough to precisely diagnose benign conditions of the oral cavity and assess if there is any need for biopsy or not.<sup>7</sup> For suspected malignant oral epithelial lesions, biopsy and histopathological examination are the gold standards for reaching a definite diagnosis. The biopsy may be incisional for larger or small lesions, each with its limitations.<sup>6,7</sup> The objective of this study was to evaluate varying histopathological outcomes of oral lesions in different age groups, histological types and location of the lesions, with special emphasis on oral cancer.

## METHODOLOGY

This cross-sectional study was done at the department of Pathology (Histopathology) at Foundation University Islamabad Pakistan in its Medical and Dental affiliates, including Foundation University School of Health Sciences (FUSH) and Foundation University College of Dentistry and Hospital (FUCD & H). Formal permission was obtained from Institutional Ethical Review Committee (Ref No. 531 / RC / FFH / RWP Dated 15 Feb 2022). The duration of this study was two years, from May 2019 to May 2021. The sample size was calculated using the population variance (from literature),<sup>8</sup> and online RaoSoft sample size calculator.

A total of 99 cases of oral lesions, which were biopsied, were included in the study. The patients included were beneficiaries of Fauji Foundation Hospital (FFH) Rawalpindi, FFH Jehlum, FFH Kalar Kahar and Civilian Non Entitled (CNE) patients. Scalpel biopsies of mucosal lesions of the oral cavity were performed under adequate local anaesthesia at Foundation University College of Dentistry and Hospital.

**Inclusion Criteria:** According to history and clinical presentation, excisional or incisional biopsies containing adequate tissue were included in the study. Excisional biopsy was considered for smaller lesions with no associated risk factors. Incisional biopsies with margins of normal tissue were done for larger suspicious oral lesions.

**Exclusion Criteria:** Biopsies showing inadequate tissue or marked crushing were excluded from the study.

Tissue specimens fixed in 10% formalin and labelled with short history were sent to the Histopathology Department of Foundation University Medical College (FUMC) for histopathology and diagnosis. A team of qualified histopathologists at FUMC was assigned to examine Hematoxylin-Eosin stained slides under a microscope and to give a definite diagnosis.

Data collection was done with the help of a centralized histopathology system, Medix Online Histopathology Reporting System (MOHRS), with keywords Buccal mucosa, Tongue, Lip, and Floor of mouth and Palate, Maxilla, Mandible and Oral Squamous Cell Carcinoma. Statistical Package for Social Sciences (SPSS) version 21.0 was used for the data analysis. In addition, the Pearson-chi square analysis for age and type of lesion was done.

## RESULTS

A total of 99 oral samples were biopsied and examined histologically. On histological evaluation, the oral pathologies observed were broadly divided into three categories, including non-neoplastic, neoplastic and premalignant lesions.

Out of these 99 cases, 41 cases (41.4%) were non-neoplastic, 56 cases (56.6%) were neoplastic and 2 cases (2.0%) were categorized as premalignant lesions. The frequency and percentage of different oral lesions were given in Figure-1.

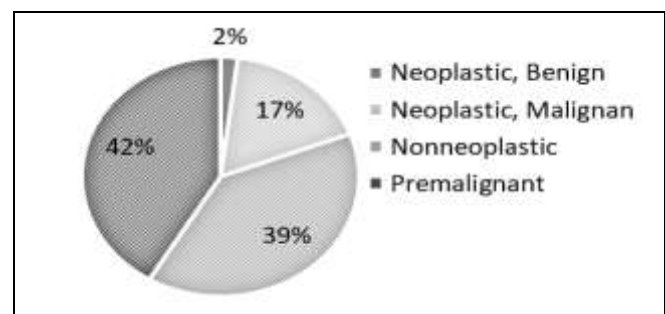


Figure-1: Relative percentages of all oral lesions (n=99)

Out of 41 non-neoplastic lesions, 14 cases (34.1%) were inflammatory, followed by 5 cases (12.1%) of

fibroepithelial polyps, 4 cases (9.7%) of pyogenic granulomas and 3 cases (7.3%) of pseudoepitheliomatous hyperplasia. Among the rest of the non-neoplastic lesions, 03 (7.3%) showed ulceration, while one case (2.4%) was of epulis.

Of 56 neoplastic lesions, 39 (69.6%) were confirmed as carcinomas. Squamous cell carcinoma was the most common malignancy comprising 29 cases (74.3%), followed by verrucous carcinoma 5 cases (12.8%), adenoid cystic carcinoma 3 cases (7.6%) and one case each of mucoepidermoid carcinoma and carcinoma in situ, respectively. The rest of the 17 neoplastic cases were benign lesions, including fibroma, 7 cases (41.1%), papilloma, 06 cases (35.2%), adenoma, and 2 cases (11.7%) and one case each of hemangioma and neurofibroma. In addition, there were two cases of potentially premalignant lesions, including one case each of leukoplakia and dysplasia, respectively. The histological diagnoses of all oral lesions were summarized in Table.

relative relation of the type of lesions (non-neoplastic and neoplastic) with age (Figure-2).

Regarding gender distribution, out of 99 patients, 86 (86.86 %) were females, and 13 (13.13 %) were males. The most common presenting complaints were non-healing ulcers, exophytic growths, white lesions, and swelling with or without pain. Regarding the location of lesions in the oral cavity, buccal mucosa and tongue had increased frequency than other sites (Figure-3).

## DISCUSSION

Oral lesions show a diversified spectrum and have always been a challenge for diagnosticians and clinicians, and our study was not an exception, which showed a mixed picture of oral pathologies, revealing neoplastic lesions being more common than non-neoplastic lesions. Similar studies on oral lesions in other parts of the world show different results. A similar study on oral lesions in the USA revealed that

**Table: Histological outcome of different oral lesions.**

Type	Diagnosis	Frequency (%)	Category	Categorized Total	Total		
Non-Neoplastic	Inflammation	14 (34.1)	Other	30	41		
	Hyperplasia	3 (7.3)					
	Epulis	1 (2.4)					
	Pyogenic granuloma	4 (9.7)					
	Fibroepithelial Polyp	5 (12.1)					
	Unremarkable/Ulceration	3 (7.3)	Cyst	11			
	Mucocele	4 (9.7)					
	Dentigerous Cyst	1 (2.4)					
	Radicular Cyst	3 (7.3)					
	Keratocyst	1 (2.4)					
	Ranula	1 (2.4)					
Lymphoepithelial Cyst	1 (2.4)	Benign	17	56			
Neoplastic	Papilloma				6 (35.3)		
	Fibroma				7 (41.2)		
	Haemangioma				1 (5.9)		
	Adenoma				2 (11.7)		
	Neurofibroma				1 (5.9)		
	Squamous Cell Carcinoma				29 (74.3)	Malignant	39
	Verrucous Carcinoma				5 (12.8)		
	Adenoid Cystic Carcinoma				3 (7.6)		
	Carcinoma in situ				1 (2.5)		
	Mucoepidermoid Carcinoma	1 (2.5)					
Premalignant	Leukoplakia	1 (50.0)	Pre-malignant	2	2		
	Dysplasia	1 (50.0)					
Total		99					

The age ranged from 8 years to 89 years, with the maximum number of patients reporting in the fifth and sixth decade. The *p*-value (*p*=0.031) for age and type of lesion was statistically significant, indicating the

74.9% of oral mucosal lesions were reactive, and only 1.97% were malignant.<sup>8</sup> Epidemiological data in Australia on oral and maxillofacial pathologies indicate an increased ratio of benign over malignant lesions.<sup>9</sup> A review of diagnoses of oral pathologies at

Kuwait University also implies most lesions to be benign.<sup>10</sup> Likewise, analysis in Brazil reported an increased propensity of inflammatory and non-neoplastic lesions.<sup>11</sup> While looking up for comparison of the range of diagnoses, it has been found that many similar studies focused only on specific oral pathology or were relevant to either paediatric or adult populations. The trend of more malignant outcomes is high in Asia and Arabian Gulf countries, likely due to predisposing factors, e.g. use of smokeless tobacco, alcohol, diet and poor oral hygiene. Saudi Arabia reported a high malignancy index, revealing 36.1% of Squamous Cell Carcinomas,<sup>12,13</sup> Moreover, this Saudi research article presented most outcomes to be neoplasia of the malignant category (38.7%) rather than inflammatory (16.5%) or reactive lesions.<sup>12</sup>

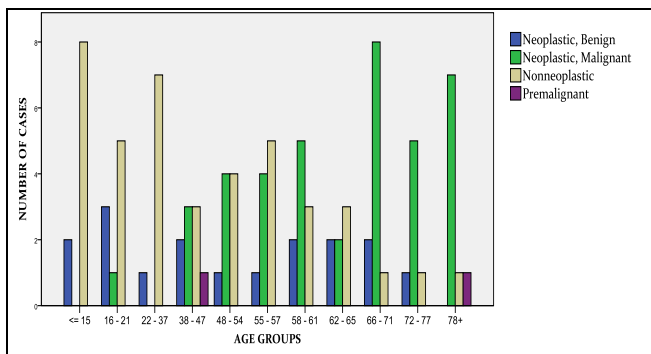


Figure-2: Distribution of lesions with respect to age groups (n=99)

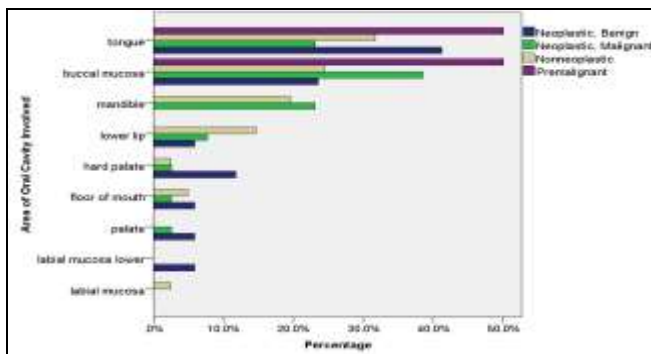


Figure-3: Distribution of lesions with respect to area of oral cavity (n=99)

Evaluating biopsies done in another university hospital in Pakistan painted a similar picture of rising trends of malignant outcomes. Malignant pathologies make up about 40% of all outcomes, with squamous cell carcinoma making up 35%, against our research of 56% neoplastic and 69% squamous cell carcinomas.<sup>14</sup> The results of our study are also in line with that in

Iran, where 27.9% of diagnoses were oral squamous cell carcinomas.<sup>15</sup>

The average age recorded in our study was 50.6, with the most prevalent age group being in the fifth and sixth decades. When relating the age differential to the type of pathology, it was found that non-neoplastic pathologies, including inflammatory and reactive, were most common in the younger age group. In contrast, malignant neoplasms had a predilection for older adults greater than 60 years of age which is consistent with other studies.<sup>16</sup> However, this finding was slightly different from one study on the geriatric population in Brazil, where inflammatory lesions were the most common diagnosis, followed by neoplasia.<sup>15</sup> In addition, another study showed increased percentages of reactive lesions in the elderly age group (60-75 years), whereas our study showed a peak of malignant neoplasms, predominantly squamous cell carcinoma, between 60-70 years.<sup>17</sup>

Nevertheless, oral squamous cell carcinoma was the dominant lesion (84.6%), similar to our study, where it constituted 69% of the neoplastic category.<sup>17</sup> The peak age group recorded for non-neoplastic inflammatory or reactive lesions was second and third decades in this analysis. This differs from the analysis by Farynowska *et al*, whose research paper indicates reactive lesions to be predominant in the fifth and seventh decade of life owing to chronic irritation to oral mucosa by mal-occlusion, ill-fitting dentures, faulty restorations, parafunctional habits etc. These combined factors contribute to low-grade chronic irritation causing hyperplasia and irritation fibromas.<sup>18</sup> Our study is similar to a Nigerian paper where 9-29 years was the predominant age group for reactive non-neoplastic lesions.<sup>19</sup>

The peak age group for malignancy recorded in our study was the sixth and seventh decade, with major cases being squamous cell carcinomas. This finding was similar to a paper published in Clinical Cosmetic and Investigative Dentistry by a researcher's group in Saudi Arabia, where the fifth and sixth decade was common for squamous and verrucous carcinoma.<sup>16</sup> Furthermore, the fifth to an eighth decade was predominant for oral cancer indicated in a multicentric study conducted in Thailand, Taiwan, and Iran, which also showed oral squamous cell carcinoma to be most prevalent in epithelial tumours.<sup>20</sup> These findings corroborate that the risk of malignancy increases with advanced age. In addition, the notable factor ( $p = 0.031$ ) in our study indicated an important

link between the type of pathology, benign and malignant, strongly associated with age.

Regarding the predominance of the anatomical area involved in oral pathology, buccal mucosa and tongue were the most common sites for non-neoplastic and neoplastic lesions, consistent with other studies.<sup>21</sup> The predilection for oral lesions also differs depending on the general attitude towards maintaining good oral hygiene, certain habits and the type of pathology. For example, Soyele *et al*, analyzed local hyperplastic lesions and found gingiva (84.6%) to be the most common site.<sup>19</sup> In contrast, hyperplastic lesions in our study were mostly localized to the tongue.

Generally, extremes of temperature by hot or cold food, altered pH, mechanical trauma from accidental cheek biting, and malposed teeth can affect any area of the oral cavity.<sup>22</sup> For oral cancer and premalignant lesions, the site for most common occurrence depends upon various etiological factors, amongst which tobacco, betel nut, alcohol, and smoking patterns play a dominant role.<sup>6</sup> Recent studies have also indicated HPV infection as a causative factor for developing oropharyngeal cancer worldwide. The panoramic review for oral cancer, e.g., squamous cell carcinoma, also indicated tongue and buccal mucosa to be the most common sites involved.<sup>20</sup>

Non-specific inflammatory lesions, including pyogenic granuloma and fibroepithelial polyp, which constituted the major portion of non-neoplastic lesions, were predominant in the female gender, which was in line with previous studies for benign reactive lesions.<sup>18</sup> Pyogenic granuloma and fibroepithelial polyp mostly presented as painless sessile and pedunculated outgrowths of oral mucosa ranging in colour from light pink to red depending on their stage of development.

The close association of these reactive lesions with the females suggests premenopausal hormonal changes contribute to inflammatory and reactive lesions, as indicated by another study. In addition, the notable fact may be the concern of females towards oral and dental care.<sup>22</sup>

Premalignant lesions constituted 2% of our study, but the diligent evaluation is required in these lesions because of their propensity to be malignant in future. Not all premalignancy proceeds to squamous cell carcinomas, but the degree of dysplasia (mild, moderate, severe) can give a clue about the nature of the lesion. In severe dysplasia, there is a greater chance of malignant potential.<sup>6</sup> One study reported that any leukoplakia, irrespective of dysplasia, has a 3.4%

chance of malignant potential with a total range of 0.13-34.0%.<sup>23</sup> Advanced age and female gender are other risk factors for the malignant potential of the premalignant lesion.<sup>23</sup> For suspicious and premalignant lesions, biopsy and prompt referral to a specialist are recommended by American Dental Association's evidencebased clinical guidelines.

Counselling of patients was also added to these guidelines because of the chance of refusal to treatment by these patients because of fear of diagnosis.<sup>24</sup> These guidelines would be beneficial if implemented in our clinical setup owing to increased malignancy outcomes.

In our study, most cases of malignant neoplasm were confirmed as squamous cell carcinomas, followed by verrucous carcinoma, similar to another paper reporting most of the epithelial tumours with squamous cell carcinoma and verrucous carcinoma, making the top two diagnoses in Canada, Iran, South Korea, Thailand and Taiwan.<sup>20</sup> The predominant site was buccal mucosa, tongue, and lip in descending order of frequency akin to reviews on oral cancer elsewhere.<sup>20,17</sup>

The prognostic differential of oral cancer is entirely a separate and detailed subject, involving the interplay of many variables beyond the scope of this article. However, oral cancer, the second most prevalent cancer in Pakistan after breast cancer, is a case of immediate concern for oral/maxillofacial surgeons, oral pathologists and oral medicine specialists.<sup>25</sup>

#### ACKNOWLEDGEMENTS

We want to thank supervisors Professor Brig (R) Dr Tariq Sarfraz, Head of the Pathology Department and Professor Dr Fatima Kaleem for their expertise in research work, beneficial guidelines and constructive critique. This study could not have been possible without the encouragement and support from family and work colleagues, Dr Saima Ishtiaq and Dr Malghalara Khattak.

#### RECOMMENDATIONS

Diagnosis of any oral pathology lesion is the interplay of history, conventional oral examination, an association of systemic disease, finding about risk factors and biopsy, if deemed necessary. Most benign oral mucosa lesions may not be sent for histopathology if the local causative factor is suspected. However, owing to a greater proportion of malignant outcomes and rising trends of oral cancer in our population, it is recommended that in all the oral lesions clinically suspected of malignancy, a biopsy should be done, and the tissue must be submitted for histopathological examination.

## CONCLUSION

In our setup, most of the oral lesions evaluated histologically are neoplastic and that too malignant, mostly squamous cell carcinomas. Most of the oral lesions occur in the fifth and sixth decade. Buccal mucosa and tongue are the most common sites of oral lesions. Therefore, the biopsy is a useful diagnostic tool for suspicious oral lesions and must be used frequently.

**Conflict of Interest:** None.

### Author's Contribution

AW: Study design, executed the study, drafting, data analysis, proof reading, TS: Study design, revising critically, supervising study, data analysis, final approval of study, proof reading, FK: Draft preparation, study design, revising critically, data analysis, proof reading, RR: Data collection, data analysis, proof reading.

## REFERENCES

1. Panarese I, Aquino G, Ronchi A, Longo F, Montella M, Cozzolino I, et al. Oral and Oropharyngeal squamous cell carcinoma: prognostic and predictive parameters in the etiopathogenetic route. *Expert Rev Anticancer Ther* 2019; 19(2): 105-119.
2. Curtis DC, Eckhart SC, Morrow AC, Sikes LC. Demographic and Behavioral Risk Factors for Oral Cancer among Florida Residents. *J Int Soc Prev Community Dent* 2020; 10(3): 255-261.
3. Siegel RL, Miller KD, Jemal A. Cancer statistics, 2018. *Cancer J Clin* 2018; (68): 7- 30.
4. Abati S, Bramati C, Bondi S, Lissoni A, Trimarchi M. Oral Cancer and Precancer: A Narrative Review on the Relevance of Early Diagnosis. *Int J Environ Res Public Health* 2020; 17(24): 9160.
5. Awadallah M, Idle M, Patel K, Kademani D. Management update of potentially premalignant oral epithelial lesions. *Oral Surg Oral Med Oral Pathol Oral Radiol* 2018; 125(6): 628-636.
6. Speight PM, Khurram SA, Kujan O. Oral potentially malignant disorders: risk of progression to malignancy. *Oral Surg Oral Med Oral Pathol Oral Radiol*. 2018; 125(6): 612-627.
7. Forman MS, Chuang SK, August M. The Accuracy of Clinical Diagnosis of Oral Lesions and Patient-Specific Risk Factors that Affect Diagnosis. *J Oral Maxillofac Surg* 2015; 73(10): 1932-1937.
8. Dovigi EA, Kwok EY, Eversole LR, Dovigi AJ. A retrospective study of 51,781 adult oral and maxillofacial biopsies. *J Am Dent Assoc* 2016; 147(3): 170-176.
9. E Kelloway, WN Ha, F Dost, CS Farah. A retrospective analysis of oral and maxillofacial pathology in an Australian adult population. *Aust Dent J* 2014; 59(2): 215-220.
10. Joseph BK, Ali MA, Dashti H, Sundaram DB. Analysis of Oral and Maxillofacial Pathology Lesions over an 18-year period diagnosed at Kuwait University. *J Investig Clin Dent* 2019; 10(4): e12432-12435.
11. Silva LP, Leite RB, Sobral APV, Arruda JA, Oliveira LV, Noronha MS, et al. Oral and Maxillofacial lesions diagnosed older people of a Brazilian Population. *J Am Geriatr Soc* 2017; 65(7): 1586-1590.
12. Saleh SM, Idris AM, Vani NV, Tubaigy FM, Alharbi FA. Retrospective analysis of biopsied oral and maxillofacial lesions in South-Western Saudi Arabia. *Saudi Med J* 2017; 38(4): 405-412.
13. Alqahtani WS, Almufareh NA, Al-Johani HA, Alotaibi RK, Juliana CI. Oral and Oropharyngeal Cancers and Possible Risk Factors Across Gulf Cooperation Council Countries: A Systematic Review. *World J Oncol* 2020; 11(4): 173-181.
14. Zaib N, Sajjad M, Iltaf S, Abbas S, Shaheen S. Oral Biopsies: Study of 114 cases. *Pak Oral Dent J* 2012; 32(3): 416-20.
15. Shooroki ZS, Zare S. Evaluation of the frequency distribution of Oral biopsies in ShahidSadoughi Hospital in Yazd during 2010-2019. *Int J Epidemiol Res* 2021; 8(3): 109-114.
16. Alhindi NA, Sindi AM, Binmadi NO, Elias WY. A retrospective study of oral and maxillofacial pathology lesions diagnosed at the Faculty of Dentistry, King Abdulaziz University. *Clin Cosmet Investig Dent* 2019; 4(11): 45-52.
17. Qannam A, Bello IO. The range of diagnoses for oral soft-tissue biopsies of geriatric patients in a Saudi Arabian teaching hospital. *Saudi Dent J* 2016; 28(2): 96-101.
18. Farynowska J, Blochowiak K, Trzybulska D, Wyganowska M. Retrospective analysis of reactive hyperplastic lesions in the oral cavity. *Eur J Clin Exp Med* 2018; 16(2): 92-96.
19. Soyele OO, Ladeji AM, Adebisi KE, Adesina OM, Aborisade AO, Olatunji AS, et al. Pattern of distribution of reactive localised hyperplasia of the oral cavity in patients at a tertiary health institution in Nigeria. *Afr Health Sci* 2019; 19(1): 1687-1694.
20. Dhanuthai K, Rojanawatsirivej S, Thosaporn W, Kintarak S, Subarnbhesaj A, Darling M, et al. Oral cancer: A multicenter study. *Med Oral Patol Oral Cir Bucal* 2018; 23(1): 23-29.
21. Blochowiak K, Farynowska J, Sokalski J, Wyganowska-Świątkowska M. Benign tumours and tumour-like lesions in the oral cavity: a retrospective analysis. *Postepy Dermatol Alergol* 2019; 36(6): 744-751.
22. McKinney R, Olmo H. *Physical and Chemical Lesions of The Oral Mucosa*, Review from Stat Pearls Publishing, Treasure Island (FL); 2021, [Internet] available at: <https://pubmed.ncbi.nlm.nih.gov/34283445/>.
23. Warnakulasuriya S, Ariyawardana A. Malignant transformation of oral leukoplakia: a systematic review of observational studies. *J Oral Pathol Med* 2016; 45(3): 155-166.
24. Lingen MW, Abt E, Agrawal N, Chaturvedi AK, Cohen E, D'Souza G, et al. Evidence-based clinical practice guideline for the evaluation of potentially malignant disorders in the oral cavity: A report of the American Dental Association. *J Am Dent Assoc* 2017; 148(10): 712-727.
25. Khokhar MA, Niaz MO, Aslam A, Khan HA. Pakistan Oral Cancer Collaborative: analyzing barriers and obstacles to oral cancer diagnosis, treatment, and prevention in Pakistan. *Oral Surg Oral Med Oral Pathol Oral Radiol* 2021; 132(3): 312-319.