

ULTRASOUND GUIDED TRANSVERSUS ABDOMINIS PLANE BLOCK VERSUS WOUND INFILTRATION WITH LOCAL ANESTHETIC AGENT IN ABDOMINAL SURGERIES

Qurat Ul Ain Amjad, Asjad Sharif, Amanat Khan

Combined Military Hospital/National University of Medical Sciences (NUMS) Rawalpindi Pakistan

ABSTRACT

Objective: To compare the pain relief and frequency of analgesia requirement in post abdominal surgeries using ultrasound guided transversus abdominis plane (TAP) block with that of wound infiltration with local anesthetic agent.

Study Design: Randomized control trial.

Place and Duration of Study: This randomized control trial study was conducted at Anesthesia Department of Combined Military Hospital, Rawalpindi, after getting permission from hospital ethical committee from 28th Feb, 2015 to 31st Aug 2015.

Material and Methods: The total number of patients included in the study were 100 with American Society of Anaesthesiologists (ASA) status I/II scheduled for elective abdominal surgeries. They were included in the study after written informed consent. The patients in group I received TAP block with 20 ml of 0.25% bupivacaine while those in group II had wound infiltration at the end of surgery with 20 ml of 0.25% bupivacaine. After induction of general anesthesia, ultrasound guided transversus abdominis plane block was performed with Kontron Agile ultrasound system using linear transducer (8-12 Hz) 15 minutes prior to the surgical incision. A Stimuplex nerve stimulator needle 22G, 50mm was used by in-plane technique to deposit local anesthetic agent. In post anesthesia care unit (PACU), visual analogue scale (VAS) from 0 to 10, and requirement of analgesia at 0, 2, 4, and 6 hours respectively was used to assess the pain.

Results: Both groups were comparable in regard to demographic data. Peak pain scores were measured using VAS with higher scores indicating worst outcome. The peak pain scores in group I patients were lower as compared to the patients in group II (p -value <0.05). The time to first analgesia was longer 8.92 ± 1.509 in group I as compared to 5.1 ± 1.971 in group II (p -value $=0.05$). The frequency of analgesia requirement in post-operative period was also more in group II. 30% patients in group II required analgesia in first two hours as compared to 0% in group I while in the sixth hour 64% of the patients in group II required analgesia as compared to 8% in group I.

Conclusion: The comparable short term post-operative pain relief was provided by both ultrasound guided TAP block and local wound infiltration, but the TAP Block showed better and long lasting effects.

Keywords: Abdominal surgeries, Local wound infiltration, Transversus abdominis plane (TAP) block, Ultrasound guided, Visual analogue scale (VAS).

This is an Open Access article distributed under the terms of the Creative Commons Attribution License (<http://creativecommons.org/licenses/by/4.0>), which permits unrestricted use, distribution, and reproduction in any medium, provided the original work is properly cited.

INTRODUCTION

The control of postoperative pain effectively is an essential component of the care of the surgical patients. The objectives of managing postoperative pain are to reduce the length of hospital stay, and patient's satisfaction besides seeking early mobilization and relieving suffering

after surgery. Management of acute perioperative pain, traditionally relied on opioid medications solely. Opioids target the central mechanisms involved in pain perception. Recently concept of multimodal analgesia has been introduced which is a better approach that uses several agents, each of which act at different sites of pain pathway. This reduces the dependence on a single medication and mechanism. The target of postoperative pain management is to keep side effects to a minimum besides relieving pain. The

Correspondence: Dr Asjad Sharif, Dept of Anesthesia, CMH Rawalpindi Pakistan (Email: asjadsharif@gmail.com)
Received: 28 Jan 2016; revised received: 29 Feb 2016; accepted: 09 Mar 2016

measures taken to make the postanesthesia period less uncomfortable are important with regards to pain relief. During surgery the nerves can be blocked before making an incision or after skin closure with local anesthetic agent (abdominal nerve block) at the end of operation or the local anesthetic solution can be used to infiltrate the wound to lessen the postoperative pain (pre-emptive wound analgesia)¹. The transversus abdominis plane (TAP) block is a peripheral nerve block designed to anesthetize the nerves supplying the anterior abdominal wall (T6 to L1). It was first described in 2001 by Rafi as a traditional blind landmark technique using the lumbar triangle of Petit². For abdominal surgery both local infiltration and Transversus abdominis plane (TAP) block target on relieving somatic pain. Local anesthetic wound infiltration is easy to perform with low risk. As the advancement of ultrasound technology, performing TAP block have also become easier, safer and more accurate.

MATERIAL AND METHODS

This randomized control trial study was conducted at Anesthesia Department of Combined Military Hospital, Rawalpindi from 28th Feb 2015 to 31st Aug 2015 after getting approval from the hospital ethical committee. The procedure and purpose of this comparative study was explained to the patients and an informed written consent was obtained. A total of

study. Technique used was consecutive non-probability sampling. All patients were randomly allocated equally to the two groups with 50 patients in each group I and II. The patients in group I received TAP block with 20 ml of 0.25% bupivacaine bilaterally while those in group II received 20 ml of 0.25% bupivacaine as local wound infiltration. Patients with age less than 20 years and greater than 65 years, pregnant females, infection at injection site and bleeding disorder were excluded from the study. Block was performed after induction of anesthesia. Patients were anesthetized with injection propofol 2-2.5 mg/kg body weight I/V. Anesthesia was augmented by isoflurane 1-2% inhaled and endotracheal intubation was facilitated with injection atracurium besylate 0.5 mg/kg body weight I/V. Maintenance anesthesia consisted of 50% air in oxygen with isoflurane 1-2%, and hemodynamic variables within 10% of baseline values was maintained. All patients were pre-medicated with injection midazolam 2mg I/V, injection nalbuphine 5-10mg I/V, injection metoclopramide 10 mg I/V. Anticholinesterase was given to reverse neuromuscular block at the end of procedure with injection neostigmine 0.04-0.07 mg/ kg body weight I/V in combination with injection glycopyrrolate 5-10 micrograms/kg body weight I/V. At surgical completion, anesthesia was discontinued, 100%

Table-I: Demographic data.

	Group I	Group II	P-values
AGE (years)	35.52 ± 7.091	35.36 ± 7.247	0.885
GENDER (male/female)	38/12	32/18	1.000
HEIGHT (cms)	162.80 ± 5.717	166.46 ± 5.65	0.363
WEIGHT (kg)	62.92 ± 10.760	69.80 ± 9.519	0.544

Table-II: Peak pain scores at 0,2,4,and 6 hours post operatively (Mean ± Standard Deviation).

Time	Peak pain scores		
	Group I	Group II	p-value
0 hours	0.06 ± 0.23	0.12 ± 0.38	0.838
2 hours	0.14 ± 0.35	1.28 ± 1.08	0.008
4 hours	1.06 ± 1.01	5.38 ± 1.01	0.015
6 hours	4.50 ± 0.50	7.24 ± 1.13	0.009

100 patients of ASA status I and II scheduled for elective abdominal surgeries were included in the

oxygen administered and patients were extubated when appropriate and shifted to PACU.

After induction of general anesthesia, ultrasound guided TAP block was performed with Kontron Agile ultrasound system using linear ultrasound transducer (8-12 Hz) 15 minutes before the surgical incision. The patient was held in supine position and the ultrasound probe was placed in a transverse plane between the lower costal margin and the iliac crest in the mid axillary line. Transversus abdominis and external oblique muscles were identified. A Stimuplex 22 G,50 mm needle was advanced using in-plane technique with an anteromedial to

After two hours Inj Tramadol 30 mg I/V was given based on initial post operative analgesic requirement protocol with minimum 30 minutes following the last tramadol dose. The record of analgesia requirement was also made. Investigator who was involved in recording post operative parameters of the patients was blinded to the study group.

All the data were analyzed using statistical package for social sciences (SPSS) version 19. Descriptive statistics for both qualitative and quantitative variables were calculated. Frequency

Table-III: Frequency of analgesia requirement in percentages.

Time		Group I	Group II	p-value
0 Hours	Yes	0%	4%	0.159
	No	100%	96%	
2 Hours	Yes	0%	30%	0.000
	No	100%	70%	
4 Hours	Yes	4%	44%	0.000
	No	96%	56%	
6 Hours	Yes	8%	64%	0.000
	No	92%	32%	

Table-IV: Time to first requirement of i/v analgesia in hours.

Time to first analgesia in hours		
Group 1	Group II	p-value
8.92 ± 1.509	5.1 ± 1.971	0.05

posterolateral direction. The needle was advanced between the aponeurosis of the internal oblique and transversus abdominis muscles. With intermittent aspiration the local anesthetic i.e. 20 ml of 0.25% bupivacaine was deposited and seen as a hypoechoic shadow pushing the two layers apart. Likewise TAP was performed on contralateral side. The patients in the other group received 20 ml of 0.25% bupivacaine as local wound infiltration after skin closure.

In post anesthesia care unit, visual analogue scale (VAS) graduated from 0 to 10 was used for pain assessment. '0' showed no pain while '10' showed the worst pain imaginable. The VAS score of greater than 5 was used for administering analgesic. For first two hours in the post operative care unit, Inj Tramadol 50 mg I/V was given by the nurse on request of the patients with minimum 20 minutes between the doses.

and percentages were calculated for qualitative variables like analgesia requirement. Mean ± standard deviation was calculated for quantitative data like age, pain scores. p-values for demographic data and analgesia requirement was calculated using paired sample t-test. Frequency of pain between the two groups was measured using chi-square test. Level of significance was taken as p<0.05.

RESULTS

A total of 100 patients with ASA status I/II were included in the study with 50 patients in each group. Mean ± SD was calculated for demographic data and means were compared using paired sample t-test.

Demographic data of both groups were comparable as represented by Mean X ± SD (table-I)

Post-operative pain was measured using numerical rating scale. Using visual analogue scale graduated from 0 to 10 on which 0 meant no pain while score of 10 showed worst pain. Higher score indicated worst outcome. In both groups pain scores were less in group I as compared to group II with *p*-value of less than 0.05 compared using chi-square test (table-II).

The frequency of requirement of analgesia in post operative period by the patients in two groups and the time for first analgesia requirement was measured using percentages and chi square test respectively (table-III & IV). The patients in group II have higher percentages for the requirement of analgesia as those in group I and the time to first analgesia needed was more in group I. Frequency of analgesia requirement was compared using paired sample t-test.

DISCUSSION

A variety of unwanted post operative consequences following poorly controlled pain after abdominal surgery includes prolonged hospital stay besides patient suffering and distress. Transversus abdominis plane (TAP) block, first described by Kuppuvelumani et al in 1993³, and formally documented by Rafi in 2001²,

TAP block is a promising effective method for post operative pain control after abdominal surgeries. Ultrasound guided transversus abdominis plane block provides excellent results in experienced hands with lesser complications⁶. TAP block is both effective and safe post operative analgesic modality in a variety of procedures including general surgeries^{7,8}. It has proven to be effective in various pediatric surgeries also^{9,10}. Other procedures like urological¹¹, gynecological¹²⁻¹⁴ and plastic¹¹ can also benefit from this. To enhance the recovery after lower abdominal surgeries, it is suggested as a part of multimodal anesthetic approach¹⁶. It is not only effective in reducing pain but also decreases morphine/opioid consumption after lower abdominal surgery^{17,18}.

Wound infiltration with local anesthetic agent is also a commonly used method for reducing post operative pain^{19,20}. A single injection of local anesthesia into skin and subcutaneous tissue layer at surgical incision sites could lower the pain scores postoperatively²¹. It is a convenient post operative analgesia procedure which is widely performed.

Our primary aim was the alleviation of post operative pain. VAS pain score considered as the

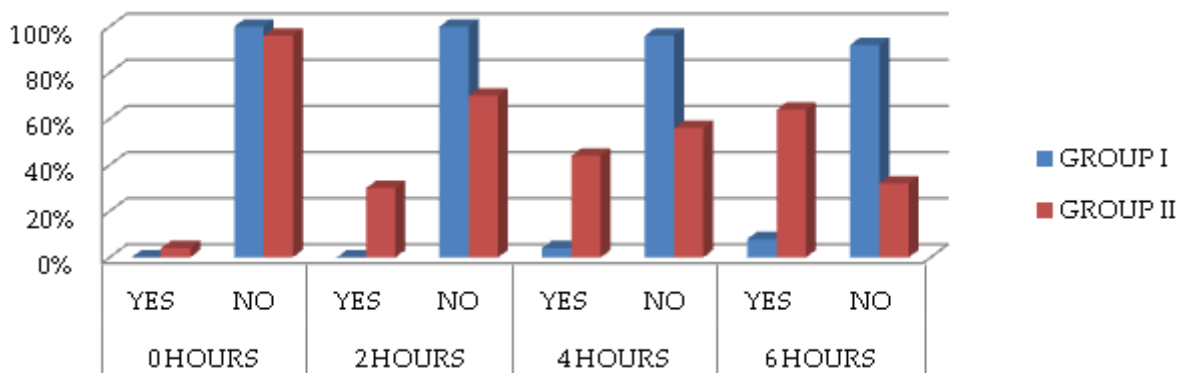


Figure: Frequency of analgesia requirement.

is used for the management of post surgical abdominal pain by injecting local anesthesia into the plane between the internal oblique and transversus abdominis muscle^{4,5}.

gold standard for pain quantification²² was used to evaluate post operative pain severity on a scale of 0-10. Uptil 6 hours postoperatively, there was significantly lower peak pain scores in group I. The results of this study were comparable with

the observations reported by Ortiz and other researchers²³ that the efficacy of TAP is of longer duration than that of local anesthetic infiltration. Ultrasound guided TAP block, which allows more accurate visualization of the needle, TAP plane, and injection spot is considered to be safer clinically and is associated with lesser complications like failure to block, injuries to abdominal viscera, nerves and vessels²⁴.

CONCLUSION

The comparable short term post operative pain relief was provided by both ultrasound guided TAP block and local wound infiltration, but the TAP block showed better and long lasting effects.

CONFLICT OF INTEREST

This study has no conflict of interest to declare by any author.

REFERENCES

- Bamigboye AA, Hofmeyr GJ. Local anesthetic wound infiltration and abdominal nerves block during caesarean section for post operative pain relief: Cochrane Database Meta analysis 2009; 10. 2002/14651858. CD006954. pub2.
- Rafi AN. Abdominal field block: a new approach via the lumbar triangle: *Anaesthesia* 2001; 56(10): 1024-6.
- Kuppuvelumani P, Jaradi H, Delilkan A. Abdominal nerve blockade for post operative analgesia after caesarean section: *Asia Oceania J Obstet Gynecol* 1993; 19(2): 165-9.
- Aveline C, Le Hetet H, Le Roux A, Vautier P, Cognet F, Vinet E, et al. Comparison between ultrasound guided transversus abdominis plane and conventional ilioinguinal/iliohypogastric nerve blocks for day-case open inguinal hernia repair: *Br J Anaesth* 2011; 106(3): 380-6.
- Lapmahapaisan S, Tantemsapya N, Aroonprukaskul N, Maisat W, Suraseranivongse S. Efficacy of surgical transversus abdominis plane block for post operative pain relief following abdominal surgery in pediatric patients: *Paediatr Anaesth* 2015; 25(60): 614-20.
- Albrecht E, Kirkham KR, Endersby RV, Chan VW, Jackson T, Okraie CA, et al. Ultrasound-guided transversus abdominis plane (TAP) block for laparoscopic gastric by-pass surgery: a prospective randomized controlled double-blinded trial: *Obes Surg* 2013; 23(8): 1309-14.
- Peterson PL, Mathiesen O, Stjernholm P, Kristiansen VB, Torup H, Hansen EG et al. The effect of transversus abdominis plane block or local anesthetic infiltration in inguinal repair: a randomized clinical trial: *Eur J Anaesthesiol* 2013; 30(7): 415-21.
- Atim A, Bilgin F, Kilickaya O, Purtologlu T, Alanbay I, Orhan ME et al. The efficacy of ultrasound guided transversus abdominis plane block in patients undergoing hysterectomy: *Anaesth Intensive Care* 2011; 39(4): 630-4.
- Sahin L, Sahin M, Gul R, Saricicek V, Isikay N. Ultrasound-guided transversus abdominis plane block in children: a randomized comparison with wound infiltration: *Eur J Anaesthesiol* 2013; 30(7): 409-14.
- Sandeman DJ, Bennett M, Dilley AV, Isperczuk A, Lim S, Kelly KJ. Ultrasound guided transversus abdominis plane blocks for laparoscopic appendectomy in children: a prospective randomized trial: *Br J Anaesth* 2011; 106(6): 882-6.
- Araco A, Pooney J, Araco F, Gravante G. Transversus abdominis plane block reduces the analgesic requirements after abdominoplasty with flank liposuction: *Ann Plast Surg* 2010; 65(4): 385-8.
- Sivapurapu V, Vasudevan A, Gupta S, Badhe AS. Comparison of analgesic efficacy of transversus abdominis plane block with direct infiltration of local anesthetic into surgical incision in lower abdominal gynecological surgeries: *J Anaesthesiol Clin Pharmacol* 2013; 29(1): 71-5.
- Belavy D, Cowlshaw PJ, Howes M, Phillips F. Ultrasound-guided transversus abdominis plane block for analgesia after caesarean delivery: *Br J Anaesth*, 2009; 103(5): 726-30.
- Skjelsager A, Ruhnau B, Kistrop TK, Kridina I, Hværnes H, Mathiesen O, et al. Transversus abdominis plane block or subcutaneous wound infiltration after open radical prostatectomy: a randomized study: *Acta Anaesthesiol Scand* 2013; 57(4): 502-8.
- Sforza M, Andjelkovic K, Zaccacheddu R, Nagi H, Colic M. Transversus abdominis plane block anesthesia in abdominoplasties: *Plast Reconstr Surg* 2011; 128(2): 529-35.
- Johns N, O'Neil S, Ventham NT, Barron F, Brady RR, Daniel T. Clinical effectiveness of transversus abdominis plane (TAP) block in abdominal surgery: a systemic review and meta-analysis: *Colorectal Dis* 2012; 14(10): e635-42.
- Abdallah FW, Halpem SH, Margarido CB. Transversus abdominis plane block for postoperative analgesia? A systemic review and meta-analysis: *Br J Anaesth* 2012; 109(5): 679-87.
- Siddiqui MR, Sajid MS, Uncles DR, Cheek L, Baig MK. A meta-analysis on the clinical effectiveness of transversus abdominis plane block: *J Clin Anesth* 2011; 23(1): 7-14.
- Coughlin SM, Karanicolas PJ, Emmerton-Coughlin HM, Kanbur B, Kanbur S, Colquhoun PH. Better late than never? Impact of local analgesia timing on postoperative pain in laparoscopic surgery: a systemic review and meta-analysis: *Surg Endosc* 2010; 24(12): 3167-76.
- Einarsson JI, Sun J, Oray J, Young AE. Local analgesia in laparoscopy: a randomized trial: *OBstet Gynecol* 2004; 104(6): 1335-9.
- Gupta A. Local anaesthesia for pain relief after laparoscopic cholecystectomy: a systemic review: *Best Pract Res Clin Anaesthesiol* 2005; 19(2): 275-92.
- Myles PS, Urquhart N. The linearity of the visual analogue scale in patients with severe acute pain: *Anaesth Intensive Care* 2005; 33(1): 54-8.
- Ortiz J, Suliburk JW, Wu K, Bailard NS, Minard CG, Palvadi RR. Bilateral transversus abdominis plane block does not decrease postoperative pain after laparoscopic cholecystectomy when compared with local anesthetic infiltration of trocar insertion sites: *Reg Anesth Pain Med* 2012; 37(2): 188-92.
- Soltani Mohammadi S, Dabir A, Shoeibi G. Efficacy of transversus abdominis plane block for acute postoperative pain in kidney recipients: a double-blinded clinical trial: *Pain Med* 2014; 15(3): 460-4.