

## ASSESSMENT OF OCCULT CERVICAL LYMPH NODE METASTASIS IN PRIMARY SQUAMOUS CELL CARCINOMA OF THE HEAD AND NECK BY COMPUTED TOMOGRAPHY

Usman Shakil, Mashkoor Ahmad\*, Atiq Ur Rehman\*\*, Rahat Shahid\*\*\*

Combined Military Hospital Lahore, \*Combined Military Hospital Peshawar, \*\*Armed Forces Institute of Radiology & Imaging, \*\*\*Pakistan Naval Ship Hospital Karachi

### ABSTRACT

**Objectives:** To determine the frequency of occult (node negative) cervical lymph node metastasis in primary head and neck squamous cell carcinoma, using contrast enhanced computed tomography (CT).

**Study Design:** Cross sectional descriptive study.

**Place and Duration of Study:** Study was conducted in Department of Radiology, Combined Military Hospital Rawalpindi. Duration of the study was 06 months i.e. from 19<sup>th</sup> February 2011 to 19<sup>th</sup> August 2011.

**Patients and Methods:** A total of 141 cases, fulfilling the inclusion criteria, reporting to the radiology department, were included in the study after seeking written informed consent. All patients underwent contrast enhanced CT scan of the neck from base of skull to root of neck using Asteion Whole Body X-ray CT Scanner (Model TSX-021A). Images were evaluated for the presence or absence of cervical lymph node metastasis according to the cervical lymph node metastatic criteria at each level of the neck.

**Results:** Of the 141 patients with clinically no head and neck squamous cell carcinoma, 45.4% were found to have lymph node metastases. Frequency of occult metastases in squamous cell carcinoma of oral cavity was 47.6%, oropharynx 23.5%, larynx 33.3% and hypopharynx 78.6%.

**Conclusion:** In clinically node negative neck, the risk of lymph node metastases is significantly high in patients of head and neck squamous cell carcinoma in our population. All patients presenting with node negative neck should undergo CT scans for early detection of occult metastasis.

**Keywords:** Computed tomography, Lymph node metastases, Squamous cell carcinoma.

### INTRODUCTION

Histopathologically, squamous cell carcinoma (SCC) is most frequently seen in head and neck malignancies. These cancers that arise from the lips, oral cavity, nasal cavity, paranasal sinuses, oropharynx and larynx, account for 5% of all malignant tumors<sup>1</sup>. Oral cavity and oropharynx tumors account for more than 2% of all the malignant neoplasms and consistently ranks among the top ten prevalent cancers worldwide<sup>2</sup>. In South Central Asia, oral cavity carcinoma is the third most common prevailing cancer<sup>3</sup>.

Regional lymph node metastasis is a frequent finding and one of the most important

factors in the prognosis and treatment of patients with head and neck tumors. The management of neck positive head and neck squamous cell carcinoma (HNSCC) revolves around the standard therapeutic options which include surgery with radical tumor resection, dissection of lymph nodes of varied extensions, radiotherapy or chemotherapy or any of these treatment combinations.

In clinically node negative neck, lymph nodes in the neck are also treated with surgery or radiotherapy because statistical data from various studies reveal that the risk of occult cervical lymph node metastases in such cases ranges from 20% to 40%<sup>4</sup> although in majority of the cases this aggressive treatment is totally unnecessary. Clinical data suggest that the rate of occult metastasis in carcinomas of oral cavity (tongue, gingivo-buccal) is above 20%<sup>5</sup>, tonsils 18.2%<sup>6</sup>, glottis 6.24%<sup>7</sup>, larynx 12.5%<sup>8</sup> and maxillary alveolus/hard palate 27%<sup>9</sup>. Studies from Pakistan have indicated equally high

**Correspondence:** Dr Usman Shakil, House No. 201, Street No. 2, Sector 1, Airport Housing Society, Gulzarequaid, Rawalpindi

Email: [usman\\_shakil@hotmail.com](mailto:usman_shakil@hotmail.com)

Received: 17 Feb 2014; Accepted: 27 Nov 2014

prevalence rates<sup>10</sup>.

In our setup, imaging techniques like computed tomography, magnetic resonance imaging and ultrasonography are employed to accurately stage cancers in the neck. CT is considered to be more accurate and preferred technique keeping in view its high sensitivity and specificity especially in depicting small pathologic lymph nodes and availability<sup>11</sup>. Positron emission tomography (PET) is the latest addition to the armoury in adequate detection of occult lymph node metastases. Although the facility is available in few major cities of Pakistan, yet affordability and accessibility is the major issue rendering CT as the mainstay modality.

This study is aimed to determine the frequency of occult (N0) cervical lymph node metastasis in primary squamous cell carcinoma of head & neck using CT scan. This study may provide vital data to the clinicians for proper staging and management of the disease. This will also help in reducing the dilemma of subjecting those patients who do not harbor metastasis to the morbidity of unnecessary treatment.

## **MATERIAL AND METHODS**

This was a cross sectional descriptive study conducted in Department of Radiology, Combined Military Hospital Rawalpindi from 19<sup>th</sup> February 2011 to 19<sup>th</sup> August 2011. Patients with histopathological or cytological proven primary squamous cell carcinoma of oral cavity, oropharynx, larynx and hypopharynx with negative neck on clinical examination, ages  $\geq 18$  years and both genders willing to participate in the study were included. Patients with recurrent head and neck squamous cell carcinoma, patients with 2 primary head and neck squamous cell carcinoma, patients with primary malignancy other than head and neck and patients in which intravenous contrast was contraindicated (renal failure, diabetes mellitus, known allergy to intravenous contrast agents and pregnancy) were excluded from the study. A total of 141 patients fulfilling the criteria were selected using non probability consecutive sampling. After formal permission from

hospital ethical committee and informed written consent from all selected patients, detailed history and physical examination was carried out. All patients underwent CT scan with Asteion Whole Body Xray CT Scanner (Model TSX-021A). The entire neck from base of skull to root of neck was scanned with 5 mm collimation/slices and a table speed of 5 mm/s after administration of  $50 \pm 100$  ml of intravenous contrast medium Iohexol (Omnipaque 350 mg of Iodine/ml) in a dose of 1 ml/kg. All images were evaluated by us for the presence or absence of cervical lymph node metastasis according to the cervical lymph node metastatic criteria at each level of the neck. Criteria includes size (short-axis diameter having a cutoff 11 mm for level 2 and 10 mm for all other levels), central nodal necrosis, nodal grouping and extracapsular spread. Occult metastases is the presence of lymph node metastases on imaging in patients with N0 stage neck disease at initial clinical examination. Anatomical levels of lymph nodes were assessed. SPSS version 13 was used for data analysis. Percentage and frequency were calculated for the qualitative variables while mean and standard deviation (SD) were calculated for the quantitative variables.

## **RESULTS**

A total of 141 patients were selected with mean age of  $61.73 \pm 12.27$  years. Out 116 were male (82.3%) with mean age of  $61.97 \pm 12.6$  years and 25 were female (17.7%) having mean age of  $60.64 \pm 10.78$  years. Out of 141 patients of HNSCC with N0 neck 64 (45.4%) cases were found to have lymph node metastases on contrast enhanced CT. Lymph node metastases according to the primary subsite are shown in Fig-1. Relative frequencies of different cervical lymph node levels in patients with cervical lymph node metastases are shown in Fig-2.

## **DISCUSSION**

Study suggests that by using the proposed criteria, presence of lymph node metastases is accurately depicted in patients with clinical N0 stage neck disease at initial examination. Limited data from Pakistan is currently available regarding the prevalence of HNSCC.

A local study shows that most common site of HNSCC in Bahawalpur region is larynx<sup>12</sup>. Admission record of our hospital suggests that cases of head and neck tumors are continuously on a rise.

Lymph node metastases is an important indicator for prognosis. Treatment options vary quite differently for HNSCC with or without nodal metastases. Biopsy is considered to be the gold standard for diagnosing lymph node metastases. Although biopsy is relatively safe it is still associated with risk of complications, patient discomfort and high cost. Also the access of all anatomical levels is not possible all the time. In addition, nodal biopsy examinations may lead to false negative results due to inadequate tissue sampling. Therefore, there is a need to develop a simple, reliable and non-invasive technique in order to assess the extent of nodal involvement. Computed tomography is a non-invasive, relatively inexpensive and accessible modality especially in tertiary care hospitals and can be used as a valuable tool during the diagnosis and follow up of patients with lymph node metastases in HNSCC. Stern et al<sup>13</sup> concluded that while it is not possible to identify all instances of cervical node involvement, employment of CT in addition to physical examination facilitates appropriate detection of nodal metastases and thus appropriate selection of patients for elective treatment of the neck. Reports published in the literature to date have shown that all patients with N0 head and neck squamous cell carcinomas should be studied at the time of their presentation and later during follow-up by using CT techniques. With latest CT generation and algorithms, one can obtain a better and more complete lymph node study of the cervical nodal group, which previously could be achieved only with per operative nodal biopsies.

The main criteria used for the detection of cervical lymph node metastases in this study was size of the lymph nodes. There have been many different size criteria for metastatic nodes with CT<sup>14-15</sup>. We used a size criterion of 11 mm as a cutoff for level 2 and 10 mm for all other levels keeping in view the high prevalence rate

of HNSCC in our region. Sumi et al<sup>16</sup> observed that although many factors may affect the accuracy of CT in detection of occult cervical

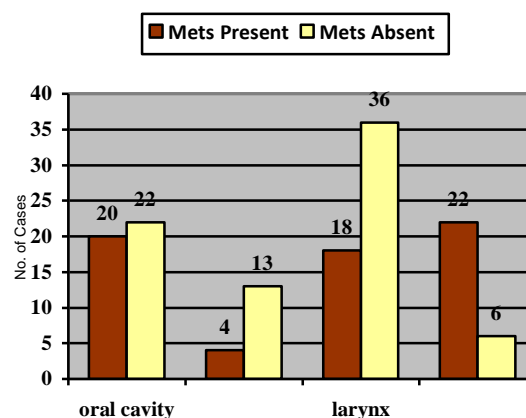


Figure-1: Lymph node metastases according to primary subsite.

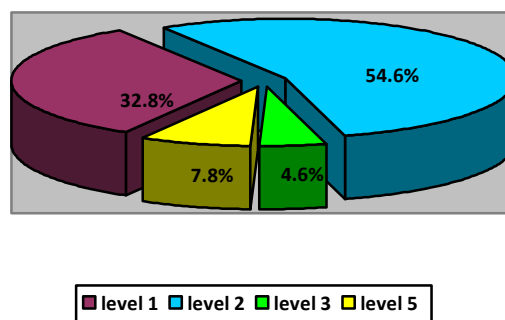


Figure-2: Frequency of cervical lymph node levels.

metastases, but the nodal size and presence of central nodal necrosis are efficiently detected by CT thus giving this modality an edge over other available and common techniques.

Study shows that 64 patients out of 141 were found to have cervical lymph node metastases giving a total risk of 45.4%. Although most studies suggest occult rate according to different primary sub sites but few authors have concluded a cumulative incidence of occult lymph node metastases in N0 neck in HNSCC. Cole<sup>17</sup> concluded that risk of occult metastases in HNSCC is around 46.37% which is very much close to the results of our study. Out of 42 patients of SCC of the oral cavity

47.6% showed occult cervical node metastases. Data from studies showed that the rate of occult cervical metastases for N0 SCC oral cavity was between 40% to 60%<sup>18</sup>. Oropharynx SCC showed 23.5% cases as positive for nodal mets. This result was slightly low as compared to the study done by Shah<sup>19</sup>, which concluded that in cases of oropharynx the risk of occult metastases is around 33%. In 54 cases of SCC of the larynx 33.3% showed occult nodal metastases. Pitman et al<sup>20</sup> suggested that occult cervical lymph node metastases in laryngeal SCC is about 30% which may be considered as equivocal to our results. Redaelli de Zinis et al<sup>21</sup>, in his study showed comparable results. However, majority of the studies conducted worldwide on different ethnic groups have a consensus that the risk of occult cervical lymph node metastases in cases of laryngeal squamous cell carcinoma is the lowest – being less than 10%<sup>22</sup>. Our study population showed a significantly high risk of metastases which may require a different treatment approach by the clinicians. It was noted in this study that out of all patients of hypopharynx 78.5% were positive for lymph node metastases which were close to the study that was conducted by Aluffi et al<sup>23</sup>. He noted an occult risk of around 77%. Finally it was also noted that for all cases with positive cervical lymph node metastases, level 1 involvement was 32.8%, level 2 showing maximum involvement with 54.6%, level 3 with only 4.6% being the least most involved level and 7.8% for level 5. There was no isolated involvement of level 4 noted in this study. The results are closely related to many international and regional studies that show that the maximum lymph node involvement of level 2<sup>5</sup>. Even in one of the local studies it was noted that level 2 involvement was largest among all other lymph node levels<sup>10</sup>.

There are few limitations to this study. Firstly, contrast enhanced CT scan is an expensive and relatively less accessible as compared to colour doppler ultrasound which is more readily available and cost effective, specially keeping in view the low socio economic status of majority of the patients who develop HNSCC in our country. Nevertheless, the diagnostic yield and accuracy of CT is much

better than ultrasonography with superior and long term benefits. Secondly interpretation of CT studies to detect occult metastases require significant expertise and inexperience on the part of radiologist can easily lead to under or over diagnosis of the condition.

## CONCLUSION

It is concluded that occult cervical lymph node metastasis in patients with squamous cell carcinoma of the head and neck is not rare. All patients presenting with node negative neck should undergo CT scans in conjunction with ultrasound for early detection of occult metastasis which can lead to appropriate management of such cases and thus reducing mortality and morbidity.

## CONFLICT OF INTEREST

This study has no conflict of interest to declare by any author.

## REFERENCES

1. Yoon DY, Hwang HS, Chang SK, Rho YS, Ahn HY, Kim JH, et al. CT, MR, US,18F-FDG PET/CT, and their combined use for the assessment of cervical lymph node metastases in squamous cell carcinoma of the head and neck. *Eur Radiol.* 2009; 19:634-42.
2. Figueiredo PT, Leite AF, Freitas AC, Nascimento LA, Cavalcanti MG, Melo NS, et al. Comparison between computed tomography and clinical evaluation in tumour/node stage and follow-up of oral cavity and oropharyngeal cancer. *Dentomaxillofac Radiol.* 2010; 39:140-8.
3. Garcia M, Jemal A, Ward EM, Center MM, Hao Y, Siegel RL, et al. *Global Cancer Facts & Figures 2007.* Atlanta, GA: American Cancer Society, 2007.
4. Richards PS, Peacock TE. The role of ultrasound in the detection of cervical lymph node metastases in clinically N0 squamous cell carcinoma of the head and neck. *Cancer Imaging.* 2007; 7:167-78. (5):810-4
5. Narendra H, Tankshali RA. Prevalence and pattern of nodal metastasis in pT4 gingivobuccal cancers and its implications for treatment. *Indian J Cancer.* 2010; 47:328-31.
6. Da Mosto MC, Zanetti F, Boscolo-Rizzo P. Pattern of lymph node metastases in squamous cell carcinoma of the tonsil: Implication for selective neck dissection. *Oral Oncol.* 2009; 45:212-7.
7. Zhang Q, Lai FY, Guo ZM, Zeng ZY, Song M, Yu WB, et al. Correlation of cervical lymphatic metastasis to prognosis of glottic carcinoma: a report of 333 cases. *Ai Zheng.* 2007; 26:1138-42.
8. Mnejja M, Hammami B, Bougacha L, Chakroun A, Charfeddine I, Khabir A, et al. Occult lymph node metastasis in laryngeal squamous cell carcinoma: Therapeutic and prognostic impact. *Eur Ann Otorhinolaryngol Head Neck Dis.* 2010; 127:173-6.
9. Simental AA, Johnson JT, Myers EN. Cervical metastasis from squamous cell carcinoma of the maxillary alveolous and hard palate. *Laryngoscope.* 2006; 116:1682-4.
10. Ahmed MU, Khawar A, Ahmed J, Ajmal M, Bangash WK, Akhter MR. Occult metastasis in carcinoma of oral cavity. *J Coll Physicians Surg Pak.* 2007; 17:313-5.
11. Atula TS, Varpula MJ, Kurki TJ, Klemi PJ, Grenman R. Assessment of cervical lymph node status in head and neck cancer patients: palpation, computed tomography and low field magnetic resonance imaging compared with ultrasound-guided fine-needle aspiration cytology. *Eur J Radiol.* 1997; 25:152-61.
12. Chaudhary MH, Samina S, Alam MS, Ehsan U, Khalid U. Head and neck squamous cell carcinoma - A 5 year experience at a tertiary care hospital in Bahawalpur, Pakistan. *Rawal Med J.* 2013; 38(4): 341-4.

13. Stern WB, Silver CE, Zeifer BA, Persky MS, Heller KS. Computed tomography of the clinically negative neck. *Head Neck*. 1990 ;12: 109-13.
  14. Castelijns JA, van den Brekel MW. Detection of lymph node metastases in the neck: radiologic criteria. *AJNR Am J Neuroradiol*. 2001; 22: 3-4.
  15. Steinkamp HJ, Hosten N, Richter C, Schedel H, Felix R. Enlarged cervical lymph nodes at helical CT. *Radiology*. 1994 : 191:795-8.
  16. Sumi M, Ohki M, Nakamura T. Comparison of sonography and CT for differentiating benign from malignant cervical lymph nodes in patients with squamous cell carcinoma of the head and neck. *AJR Am J Roentgenol*. 2001 Apr; 176: 1019 -24.
  17. Cole I, Hughes L. The relationship of cervical lymph node metastases to primary sites of carcinoma of the upper aerodigestive tract: a pathological study. *Aust N Z J Surg*. 1997; 67:860-5.
  18. Won J, Hong C, Kwang H, Myoung S, Myung J. Treatment of Patients with Clinically Lymph Node-negative Squamous Cell Carcinoma of the Oral Cavity. *Jpn J Clin Oncol*. 2008; 38: 395-401.
  19. Shah J. Patterns of cervical lymph node metastasis from squamous carcinoma of the upper aerodigestive tract. *Am J Surg*. 1990; 160:405-9.
  20. Pitman KT, Johnson JT, Brown ML, Myers EN. Sentinel node biopsy in head and neck squamous cell carcinoma. *Laryngoscope*. 2002; 112:2101-13.
  21. Redaelli de Zinis LO, Nicolai P, Tomenzoli D, Ghizzardi D, Trimarchi M, Cappiello J, et al. The distribution of lymph node metastases in supraglottic squamous cell carcinoma: therapeutic implications. *Head Neck*. 2002 ;24:913-20.
  22. Ferlito A, Silver CE, Rinaldo A. Selective neck dissection (IIA, III): a rational replacement for complete functional neck dissection in patients with N0 supraglottic and glottic squamous carcinoma. *Laryngoscope*. 2008; 118:676-9.
  23. Aluffi P, Pisani P, Policarpo M, Pia F. Contralateral cervical lymph node metastases in pyriform sinus carcinoma. *Otolaryngol Head Neck Surg*. 2006; 134: 650-3.
- .....