

## DIAGNOSTIC ACCURACY OF INDIRECT LARYNGOSCOPY AND X-RAY NECK IN THE DIAGNOSIS OF FISH BONE IMPACTION IN UPPER AERO DIGESTIVE TRACT

Nasir Akram Kundi, Talat Mehmood

Combined Military Hospital Nowshera

### ABSTRACT

**Objective:** This study was aimed at finding the validity of indirect laryngoscopy (IDL) and neck X-Rays in the diagnosis of fish bone impaction.

**Study Design:** Validation study.

**Place and Duration of Study:** CMH Nowshera from August 2012 to February 2013.

**Material and Methods:** A total of 50 patients were selected by consecutive sampling presenting with history of fishbone impaction in aerodigestive tract. IDL examination and neck X-rays were performed and findings were recorded. Those with no fishbone on both the investigations were discharged from hospital with follow up after 03 days. Those with fishbone detected on either of investigations underwent removal. Fishbone easily approachable were removed under local anaesthesia with forceps and in others Endoscopy (Direct laryngoscopy or Oesophagoscopy) was performed under General Anaesthesia. Sensitivities and specificities of both the modalities were calculated using standard 2/2 Table. ROC curve analysis was carried out and significance level  $p < 0.05$  was taken as significant.

**Results:** In 20 patients no fishbone was found, 26 patients were diagnosed on IDL and in 04 patients fishbone was detected by neck X-Rays. Most common site for fishbone impaction was pharyngeal tonsil. In 22 patients fishbone was removed with forceps and in 08 patients endoscopy was performed. Diagnostic accuracy for IDL 86% and Neck X-Rays 48% was calculated. ROC curve analysis revealed AUC for IDL 0.933 and Significance level (P) as  $<0.0001$ . ROC curve analysis for X-ray gives AUC of 0.567 and Significance level (p) 0.4132.

**Conclusion:** IDL shows higher diagnostic accuracy than neck X-Rays for detection of fishbone in upper aerodigestive tract. Neck X-rays are more useful for impacted foreign bodies in oesophagus.

**Keywords:** Aero digestive tract, Fishbone, Foreign body.

### INTRODUCTION

Whenever an object not intended for ingestion by human being is intentionally or unintentionally swallowed or inhaled, it becomes foreign body in aero digestive tract<sup>1</sup>. Foreign bodies (F.B) of aerodigestive tract can be broadly classified into blunt, sharp and vegetable FB. Fish bone is included in sharp category. Other commonly found foreign bodies are coins, common pins, batteries, impacted meat bolus, whistle, peanut and beetle nut<sup>2</sup>. Its potential for complications which necessitates its early removal. Most commonly children are effected, others include psychiatric patients and those seeking benefit, relaxation in job on medical grounds.

Our hospital is situated on bank of river Kabul. A number of fish restaurants are

situated in the surroundings of hospital. Different types of fish available at these restaurants are Lahori Rahu, China fish, Malhi, Mahusher etc. Causes of fish bone impaction are eating in hurry, improper chewing and poor vision of the patient. For these reasons fish bone impaction is one of the common emergencies in ENT department at CMH Nowshera.

Patients present with complaints of throat pain, haemoptysis and odynophagia<sup>3</sup>. Fish bone can only be seen on examination with the help of IDL mirror. Signs of fish bone impaction on mirror examination are pooling of saliva and blood stained saliva. While on X-Ray film the fish bone appears as radio opaque linear calcific structure in the upper aerodigestive tract<sup>4</sup>. Other signs of fishbone impaction are widening of prevertebral shadow and retropharyngeal air on X-ray lateral view neck.

Most common site of fishbone impaction is pharyngeal tonsil. While sometimes it produces laceration of mucosa and moves further down the digestive tract due to peristalsis. Other sites

**Correspondence:** Dr Nasir Akram Kundi, ENT Specialist, Nowshera

Email: nasir1926@hotmail.com

Received: 10 Oct 2013; Accepted: 21 May 2014

for impaction can be base of tongue, retromolar trigone, valleculae, epiglottis, pyriform fossae and along entire length of oesophagus<sup>5</sup>. Most common site for impaction of foreign body in the oesophagus is cervical oesophagus at the level of cricopharyngeus followed by thoracic oesophagus at the level of aortic arch<sup>6</sup>.

Complications of fish bone impaction can range from mild continuous pain that persists for days to life threatening perforation of oesophagus, duodenum and caecum<sup>7</sup>. Other local complications are haematoma and granuloma formation and pancreatic, thyroid and hepatic abscess. Even aortoduodenal fistula formation has also been mentioned in literature<sup>8</sup>.

For diagnosis, simple and most readily available tools are IDL (mirror examination) and neck-rays. Examination technique involves examiner and patient sitting opposite to each other at same level. Tongue is held with the help of surgical gauze piece and slightly pulled forward. Mirror is warmed and tested first on own palm and then on back of patients hand to gain his/her confidence<sup>9</sup>. It is introduced by holding it like a pen with patients mouth wide open. With focused light on the mirror held in oropharynx, a clear view of laryngo pharynx and hypopharynx can be obtained. This technique requires practice and it is easy to perform in patients with long and thin neck. Advantages of IDL are that it provides direct visualization of the foreign body and it can be removed with forceps under local anaesthesia. Its disadvantage is that it is impossible to perform in uncooperative patient and it does not provide view beyond pyriform fossae. While x-rays are also useful in the diagnosis of fishbone. Its limitation is inability to show fish bones with poor calcification e.g China fish.

Direct laryngoscopy and oesophagoscopy are traditional methods of removal of foreign bodies of upper aerodigestive tract. Its advantages include examination of all anatomical structures in laryngopharynx, hypopharynx and oesophagus under General Anaesthesia. A number of complications can arise as result of these techniques like oesophageal perforation, mediastinitis,

pneumothorax, surgical emphysema and peritonitis<sup>10</sup>. Minor complications include injury to lips, teeth and dislocation of cervical vertebrae.

Both the methods are used in the diagnosis of fish bone impaction. The rationale of this study was to elaborate the significance of these investigations and single out the most useful investigation in emergency situations.

## **MATERIAL AND METHODS**

A validation study was carried out at ENT OPD of CMH Nowshera between Aug 2012 to Feb 2013. Study commenced after formal permission was taken from hospital ethical committee. All the patients who presented with the complaints of throat pain, haemoptysis and odynophagia after fish bone impaction were included in the study. Those patients who were unwilling for IDL examination or in whom IDL was not possible due to excessive gag reflex were excluded from the study. Total 50 patients were included in the study through consecutive sampling. All the patients were subjected to clinical examination by an ENT specialist including indirect laryngoscopy (IDL). Here IDL means examination of anatomical structures in upper aero digestive tract with the help of mirror. All the data of patients and examination findings were recorded on a specially designed history sheet. An urgent x-ray lateral and anteroposterior views of the neck were performed. Depending on the IDL examination and X-ray findings, diagnostic endoscopy (either laryngoscopy or oesophagoscopy) under GA was performed and fish bone was removed. In some of the patients fish bone was removed with the help of forceps and headlight under local anaesthesia (10% lignocaine spray). In those patients with no evidence of fish bone impaction either on IDL examination or x-ray neck, no intervention except symptomatic pain relief was decided. Patients were allowed to go home after reassurance. Oral tablet Brufen 400 mg once daily for pain and follow up in ENT OPD after 03 days. Out of 20 cases proved negative by IDL examination and neck X-Rays only 14 turned up for follow up and none reported persistence of symptoms. Sensitivity and specificity of both

diagnostic modalities were calculated using 2/2 table and formulae. ROC curve analysis was carried out by using MedCalc software.

**RESULTS**

Out of 50 patients 35 (70%) were male and 15(30%) were female. Mean age of the patient was 35 (SD = 25). Most of the cases reported to hospital between the months of October and February which is the peak season for fish hunting in the rivers in Pakistan. Fish business is also at its peak in the restaurants during these months. In 20 (40%) patients there was no evidence of fish bone impaction on IDL and X-ray neck. They did not require any intervention. IDL had sensitivity of 86.7% , specificity 100%, positive predictive value of 100% , negative predictive 83.3% and diagnostic accuracy of 86%. X-ray neck had sensitivity of 13.3% , specificity 100% , positive predictive value 100% and negative predictive value of 43.47%. The diagnostic accuracy of X ray neck in diagnosing neck fish bone was 48%. In 8 (16%) patients fish bone was removed through rigid endoscope (either laryngoscope or oesophagoscope) while in 22 (44%) patients it was removed with forceps under local anaesthesia with the help of headlight.

ROC curve analysis revealed AUC for IDL 0.933 and significance level (p) as <0.0001. ROC curve analysis for x-ray gives AUC of 0.567 and Significance level (p) 0.4132.

**DISCUSSION**

Fish bone impaction presents as an acute emergency, because patient perceives severe pain and is unable to swallow solids and liquids. Its early removal relieves pain and avoids further complications<sup>11</sup>. Although in literature a number of various investigations are described such as flexible endoscopy and CT scan neck for the definite diagnosis. But in emergency circumstances and due to lack of resources these two modalities (IDL and -Ray neck) for the diagnosis of fish bone is best available aid in our set up. Secondly, these are the most cost effective investigations<sup>12</sup>. The results of our study reflect that in 40% of cases there was no fish bone impaction and patient’s symptoms of throat pain were relieved with

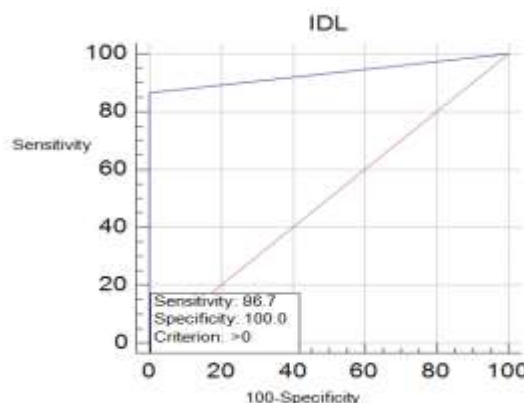
oral NSAIDs. Reassurance and follow up was enough for definitive management. In 60% of the patients presence of fish bone was

**Table- 1: Cross tabulation for x-ray neck in diagnosing neck fish bone.**

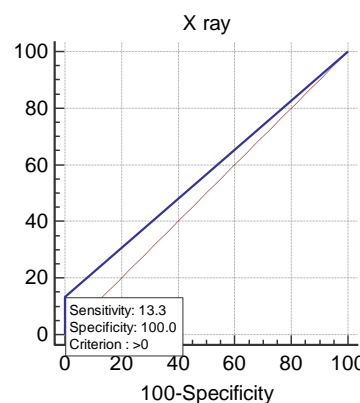
IDL	Present	Absent	
Positive	26	0	26
Negative	4	20	24
	30	20	50

**Table- 2: Cross tabulation for IDL in diagnosing neck fish bone.**

Site of impaction	No. of patients	Percentage
Tonsil	13	43.33%
Base of tongue	06	20%
Vallecullae	03	10%
Epiglottis	0	0%
Hypopharynx	02	6.66%
oesophagus	06	20%



**Figure-1. Roc Curve analysis for IDL.**



**Figure-2: ROC analysis for x-ray.**

confirmed. In 24 patients fishbone was detected with the help of IDL mirror examination. While in only 6 patients x-rays gave the diagnosis.

This high sensitivity of IDL is due to the reason that fish bone impaction in most of the cases is high enough in the upper aero digestive tract to be detected on IDL. While only a few fish bones find its way down the tract to be impacted in lower tract<sup>13</sup>. Lower down the tract x-rays can easily detect presence of fish bone due to two reasons. It is the absence of overshadowing by other bones as happens in fish bone impaction in upper aerodigestive tract. Where the images of mandible, hyoid bone and laryngeal cartilages cause hindrance in detection of fish bone. Secondly it is relative radio opacity of the fish bone in comparison with less opaque tissues of cervical oesophagus which makes it prominent on neck x-rays. Our research has shown that IDL is predominantly more useful than x-ray neck in diagnosis of fishbone impaction. However due to limited view provided by the mirror examination, fishbone impaction in esophagus can be diagnosed on x-rays only. Moreover in many of the cases, there is no actual impaction of fish bone. It is the laceration caused by the dislodged fishbone which can cause pain on swallowing. This poor sensitivity of x-rays can be due to inability to demonstrate small fishbones with lesser degree of calcification. Secondly oedema and inflammatory response of mucosa may also obscure the view of impacted fishbone.

Another finding of our study was the frequency of sites of fish bone impaction. Most common site is pharyngeal tonsils. Less frequent sites were valeculae and base of tongue. These results are concurrent with studies on the same subject<sup>14</sup>. Impaction of fish bone in cervical oesophagus and thoracic oesophagus is less frequent as compared to relatively dense tissues like pharyngeal tonsils, base of tongue and valeculae.

Moreover, in 22 patients (73%) fishbone was removed per orally under local anaesthesia while 8(27%) required rigid endoscopy under General Anaesthesia.

Ritchie T<sup>15</sup> conducted research on 20 different species of fish and found sensitivity of radiographs in the range of 95% but here

images were reproduced in custom made phantoms.

Davies WR<sup>16</sup> showed that neck X-Rays to be 79% sensitive and 90% specific for the detection of fish bone in upper aerodigestive tract but cadaveric sheep model was used.

Bathla G<sup>17</sup> et al. provided evidence for 32% sensitivity of neck X-Rays for detection of fish bone impaction.

Jassar P<sup>18</sup> described an interesting method of differentiating between laceration of mucosa and fish bone impaction by asking patients to have gargles with toluidine blue.

Hone SW<sup>19</sup> presented his data about different species of fish available in the region and declared visibility on radiograph dependent on position of fishbone rather their degree of opacity.

Sundgren PC<sup>20</sup> showed no trust in radiographs and preferred clinical examination and endoscopy for the detection of fish bones.

Kim HU<sup>21</sup> described the portion of specific fish species involved in impaction in upper aerodigestive tract causing deep penetration and mural involvement as compared to other species. Dagan E<sup>22</sup> described the relationship of fishbone impaction to its price. Timing and location whether eaten at home or outdoor. Kikuchi K<sup>23</sup> narrated a case of neglected fishbone presenting as granuloma in oesophagus after one year detected with the help of endoscopy and CT scan.

Gulshan Hussain<sup>24</sup> also described types of foreign bodies encountered and indicated presence of underlying pathology like benign strictures, webs, neoplasms and diverticulum. Dushyant Shetty<sup>25</sup> emphasized use of digital radiography giving diagnosis of fish bone impaction in 100% of patients. He also claimed that overshadowing by hyoid bone, laryngeal cartilages and cooked status of fishbone may also effect its opacity on neck X-rays.

In available literature much of the work on fish bone impaction comes from the countries where fish consumption is high e.g Japan, China and Malaysia. In our country there is relatively less consumption of sea food including fish. For this reason less number of

cases were available for the study. Secondly, the different types of fish can have different appearances on radiographs depending on the extent of calcification of fish bone. This can be the confounding factor in the study.

Still there is lot of room for further research on pattern of presentation on X-rays of various species of fish in our region. Multicenter trials should be carried out to further evaluate the diagnostic efficacy of these investigative techniques.

In this era of technological advancements, it is possible to diagnose impaction of fish bone with 100% accuracy with investigations like CT scan and flexible endoscopy. But the availability of these modalities and cost of treatment are main issues in our setup. However it is recommended that these advanced modalities be made available in emergency departments of all tertiary care hospitals for the benefit of the patients and ease of diagnosis for the attending surgeon.

## CONCLUSION

IDL examination is more accurate for diagnosing fishbone impaction in upper aerodigestive tract than x-ray neck. IDL provides the diagnosis in majority of cases, while x-rays are useful for impaction in the esophagus only. Those with negative results on both investigations merely require analgesia, reassurance and follow up.

## CONFLICT OF INTEREST

This study has no conflict of interest to declare by any author.

## REFERENCES

- DePietro J, Devaiah A. Endoscopic removal of esophageal foreign body and drainage of thyroid abscess. *Am J Otolaryngol*. 2013 Mar-Apr; 34(2): 151-3.
- Ko SF, Lu HI, Ng SH, Kung CT. Fishbone penetration of the thoracic esophagus with prolonged asymptomatic impaction within the aorta. *J Vasc Surg*. 2013 Feb; 57(2): 518-20.
- Chen H. A Tongue granuloma due to a fishbone mimicking a neoplasm: ultrasound-guided differential diagnosis. *Ultraschall Med*. 2011 Jan; 32 Suppl 1: S1-2.
- Hung CC, Lee JC, Hsiao LC, Lin YS. Vocal cord immobility caused by the long-standing impaction of a fishbone in the hypopharynx. *Laryngoscope*. 2009 Jan; 119(1): 228-30.
- Endican S, Garap JP, Dubey SP. Ear, nose and throat foreign bodies in Melanesian children: an analysis of 1037 cases. *Int J Pediatr Otorhinolaryngol*. 2006 Sep; 70(9): 1539-45.
- Giger R, Landis BN, Dulguerov P. Uncommon position of a retropharyngeal impacted fishbone. *Laryngorhinootologie*. 2004 Dec; 83(12): 852-5.
- Akazawa Y, Watanabe S, Nobukiyo S, Iwatake H, Seki Y, Umehara T, et al. The management of possible fishbone ingestion. *Auris Nasus Larynx*. 2004 Dec; 31(4): 413-6.
- Casadio G, Chendi D, Franchella A. Fishbone ingestion: two cases of late presentation as pediatric emergencies. *J Pediatr Surg*. 2003 Sep; 38(9): 1399-400.
- Sokolowski D, Sosada K. Pharynx perforation caused by fishbone--diagnostic problems. *Wiad Lek*. 2002; 55(11-12): 772-7.
- Tong M, Kang X, Sakakibara H, Suetsugu S. Successful removal of a 12 year long intrabronchial fishbone through fiberoptic bronchoscopy. *Respiology*. 1997 Dec; 2(4): 291-3.
- Ell SR, Sprigg A, Parker AJ. A multi-observer study examining the radiographic visibility of fishbone foreign bodies. *J R Soc Med*. 1996 Jan; 89(1): 31-4.
- Sands NB, Richardson K, Mlynarek A. A bone to pick? Fish bones of the upper aerodigestive tract: review of the literature. *J Otolaryngol Head Neck Surg*. 2012 Oct; 41(5): 374-80.
- Ihama Y, Hokama A, Iraha A, Kaida M, Kinjo F, Fujita J. Esophageal perforation by fish bone ingestion. *Gastrointest Endosc*. 2011 Oct; 74(4): 921; discussion 921.
- Revadi G, Philip R, Gurdeep S. Removal of foreign-bodies under general anaesthesia. A review of rigid endoscopy for foreign-bodies of the hypopharynx and oesophagus. *Med J Malaysia*. 2010 Jun; 65(2): 143-5.
- Ritchie T, Harvey M. The utility of plain radiography in assessment of upper aerodigestive tract fishbone impaction: an evaluation of 22 New Zealand fish species. *N Z Med J*. 2010 Apr 30; 123(1313): 32-7.
- Davies WR, Bate PJ. Relative radio-opacity of commonly consumed fish species in South East Queensland on lateral neck x-ray: an ovine model. *Med J Aust*. 2009 Dec 7-21; 191(11-12): 677-80.
- Bathla G, Teo LL, Dhanda S. Pictorial essay: Complications of a swallowed fish bone. *Indian J Radiol Imaging* 2011; 21: 63-8.
- Jassar P, Murray DP, Lee MS. The use of toluidine blue gargles to aid the detection of impacted pharyngeal fish bones. *J Laryngol Otol*. 1999 Oct; 113(10): 909-10.
- Hone SW, Fenton J, Clarke E, Hamilton S, McShane D. The radio-opacity of fishbones: a cadaveric study. *Clin Otolaryngol Allied Sci*. 1995 Jun; 20(3): 234-5.
- Sundgren PC, Burnett A, Maly PV. Value of radiography in the management of possible fishbone ingestion. *Ann Otol Rhinol Laryngol*. 1994 Aug; 103(8 Pt 1): 628-31.
- Kim HU, Song HJ. Clinical characteristics of an esophageal fish bone foreign body from *Chromis notata*. *J Korean Med Sci*. 2012 Oct; 27(10): 1208-14.
- Dagan E, Yakirevich A, Migirov L, Wolf M. The role of economics and weekend meals in impacted fish bone occurrence in central Israel. *Isr Med Assoc J*. 2011 Jan; 13(1): 48-50.
- Kikuchi K, Tsurumaru D, Hiraka K, Komori M, Fujita N, Honda H. Unusual presentation of an esophageal foreign body granuloma caused by a fish bone: usefulness of multidetector computed tomography. *Jpn J Radiol*. 2011 Jan; 29(1): 63-6.
- H Gulshan, I Mahid, I hsanullah, H Mohammed, A Sharafat. Esophageal foreign bodies: an experience with rigid esophagoscope. *Gomal J Med Sci Jul - Dec 2010; 8(2): 218-20.*
- Dushyant Shetty, David AT Gay. The lateral neck radiograph for an impacted fish bone in the aero-digestive tract: Going back to basics. *J Biomedical Science and Engineering*, 2012; 5, 826-828.