

## DIAGNOSTIC ACCURACY OF GRAY-SCALE AND COLOUR DOPPLER ULTRASONOGRAPHY IN DIAGNOSING MALIGNANT THYROID NODULES

Dost Muhammad, Shamrez Khan\*, Asif Rahman\*\*

Pakistan Air Force Shahbaz Jacobabad Pakistan, \*Armed Forces Institute of Rehabilitation Medicine/National University of Medical Sciences (NUMS) Rawalpindi Pakistan, \*\*Combined Military Hospital Jhelum/National University of Medical Sciences (NUMS) Pakistan

### ABSTRACT

**Objective:** To determine diagnostic accuracy of gray-scale and colour doppler ultrasonography in diagnosing malignant thyroid nodules.

**Study Design:** Validation study.

**Place and Duration of Study:** Radiology department Combined Military Hospital (CMH) and Military Hospital (MH) Rawalpindi from July 2007 to July 2008.

**Subjects and Methods:** Fifty cases of solitary/multinodular goitre with clinical suspicion of malignancy were included in the study by non-probability purposive sampling. Gray-scale and colour doppler ultrasonography of neck/thyroid gland was done and results were compared with histo-pathological findings from Armed Forces Institute of Pathology (AFIP) and Army Medical College keeping histopathology as gold standard.

**Results:** In 50 patients, 10 cases found to have ultrasound findings suspicious of malignancy. Out of these 10 cases, 6 cases confirmed as malignant on histopathology. In 40 patients with benign ultrasound findings, one had malignancy on histo-pathological examination. Out of these 7 patients with confirmed malignancy, four had papillary carcinoma; two had follicular carcinomas and one anaplastic carcinoma. Diagnostic parameters calculated and found to be: sensitivity 85.7%; specificity 90.6%; PPV 60%; NPP 97.5% and accuracy of 90%.

**Conclusion:** Gray-scale and colour doppler ultrasonography is a good technique in diagnosing malignant thyroid nodules. Entirely solid nodule with no cystic element having spiculated margins, micro-calcifications and central flow are helpful sonographic findings pointing towards malignancy. Associated cervical lymphadenopathy with calcification or degeneration is a significant finding favouring malignancy.

**Keywords:** Doppler ultrasound, Malignancy, Nodular goitre.

---

This is an Open Access article distributed under the terms of the Creative Commons Attribution License (<http://creativecommons.org/licenses/by/4.0>), which permits unrestricted use, distribution, and reproduction in any medium, provided the original work is properly cited.

---

### INTRODUCTION

Thyroid nodules are extremely common especially in females and ultrasound is frequently the initial radiological investigation requested. Ultrasound was thought to be helpful only in differentiating solid from cystic nodules but the introduction of high resolution probes and Doppler has made it possible to detect many non-palpable thyroid nodules as well as features suggestive of malignancy<sup>1,2</sup>. Ultrasonography is non-invasive, quick, accurate, completely safe and relatively inexpensive.

Ultrasound is a sensitive method for diagnosing intrathyroid lesions. It can depict as small as 2-mm cystic lesions and 3-mm solid intrathyroid lesions. It is challenging to differentiate a few malignant nodules from the common benign ones. Despite ultrasound's ability to clearly identify nodules, no single sonographic feature is reliable in differentiating benign from malignant thyroid nodules and overlap exists between them. However, many sonographic features may aid in predicting malignant nature of a given nodule. Typically, most malignant nodules are usually predominantly solid and hypoechoic, have irregular or spiculated margins and, at times, show fine micro-calcifications in the nodule, particularly in papillary carcinomas. Benign

---

**Correspondence:** Dr Dost Muhammad, Radiologist, PAF Hospital Shahbaz, Jacobabad Pakistan  
 Email: [dostmuhammad16@yahoo.com](mailto:dostmuhammad16@yahoo.com)  
 Received: 04 Feb 2015; revised received: 25 May 2015; accepted: 09 Jun 2015

nodules are commonly well defined (96% benign), entirely cystic, solid and cystic or may be solid, demonstrate coarse calcification, have thin echolucent halo around the entire lesion and may show spongiform appearance<sup>3,4</sup>.

The role of colour doppler sonography in the evaluation of a thyroid nodule for malignancy is invaluable; it shows a pattern of either spotty intranodular flow or hypervascular central flow which may be associated with malignancy<sup>3</sup>. The purpose of this study is to determine utility and accuracy of Gray-scale and colour doppler ultrasound in diagnosing malignant/suspicious thyroid nodules.

**MATERIAL AND METHODS**

This was a validation study conducted at department of Radiology, Military Hospital/ Combined Military Hospital Rawalpindi from July 2007 to July 2008. All willing and cooperative patients suffering from solitary/multinodular

study commenced. All the patients were included in the study after obtaining their informed consent.

Gray-scale and colour doppler ultrasonography was done in each case with Toshiba Aplio ultrasound machine using linear probes having frequency range of 7.5 to 11 MHz. All the patients were examined while lying supine on the examination couch. Thyroid gland including both lobes and isthmus were scanned anterior to the trachea. Findings were recorded with associated cervical lymphadenopathy. The findings of each ultrasonography were substantiated by opinion of a consultant radiologist. Histo-pathological specimens were obtained surgically in all cases and sent to Armed Forces Institute of Pathology/Army Medical College Laboratory Rawalpindi. Both sonographic and histo-pathological findings were compared keeping histo-pathological findings as gold standard.

**Table-1: Ultrasound findings of suspected malignant thyroid nodules.**

| S.No. | Ultrasound findings                       | Number of patients |
|-------|---|--------------------|
| 1.    | Entirely solid and no cystic element      | 10 (20%)           |
| 2.    | Hypoechoic to normal thyroid echo pattern | 8 (16%)            |
| 3.    | Spiculated margins                        | 5 (10%)            |
| 4.    | Micro-calcifications                      | 6 (12%)            |
| 5.    | Increased intranodular vascularity        | 4 (08%)            |
| 6.    | Associated cervical lymphadenopathy       | 1 (02%)            |

**Table-2: Histopathological finding.**

|  | Histopathology positive for malignancy | Histopathology negative for malignancy |
|--|--|--|
| Gray scale colour doppler ultrasound positive for malignancy | a (TP) 6                               | b (FP) 4                               |
| Gray scale colour doppler ultrasound negative for malignancy | C (FN) 1                               | d (TN) 39                              |

goitre of all ages and either gender with clinical suspicion of malignancy were included. Patients with diffuse goitre and history of known thyroid malignancy were excluded from the study. A total number of 50 patients were selected on non-probability convenience sampling technique. The seeking permission from concerned authorities and approval of Hospital Ethical Committee

All data collected was analysed using SPSS version 11. Descriptive statistics were used to calculate mean and standard deviation for quantitative variables while frequency and percentages for qualitative variables. Sensitivity, specificity, positive predictive/negative predictive values and accuracy were calculated for Gray-scale and colour doppler

ultrasonography keeping histopathology as gold standard.

**RESULTS**

Out of 50 patients there were 5 males and 45 females with age varying from 16 to 60 years. Mean for age was 43.8 years and Standard Deviation was 10.7. Sonographic features suggestive of malignancy included entirely solid nodule with no cystic elements, marked hypoechoogenicity to normal thyroid echo pattern, irregular or microlobulated borders, thick peripheral hypoechoic halos, micro-calcifications and intranodular vascularity. Out of the fifty

Predictive Value: 60%; Negative Predictive Value: 97.5% and Accuracy of 90%. These values are comparable with the values found in the international literature.

**DISCUSSION**

A nodule is a swelling or lump, which can be solid, liquid filled cyst or mass. Thyroid nodules are common and ultrasound is frequently the initial investigation of choice<sup>1,2</sup>. Thyroid nodules are detected in approximately 40-50% of patients who are scanned for other reasons<sup>1,2,5</sup>. Although thyroid is the most common endocrine organ to undergo malignant

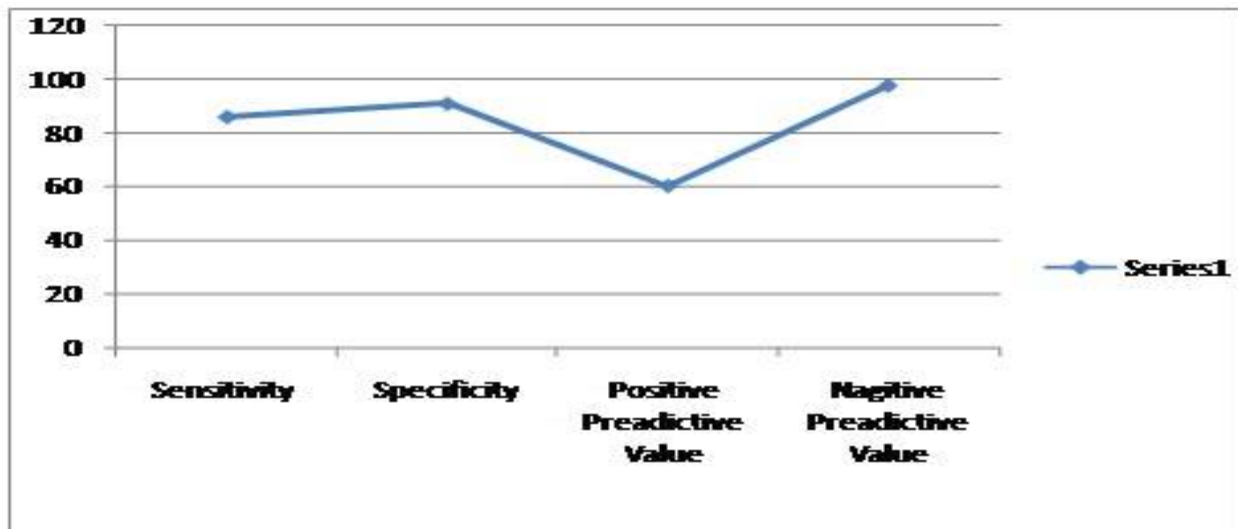


Figure-1: ROC curve.

patients whose ultrasound was done 10 were found to have sonographic findings suspicious of malignancy. Two were males and 8 were females. Table-1 shows the findings of these 10 patients.

Out of the 10 patients found to have findings suspicious of malignancy on ultrasound 6 had malignancy on histo-pathological examination. In 40 patients with benign sonographic findings, one had malignancy on histopathology thus aiding false negative to our study. Out of these 7 patients with confirmed malignancy four were papillary carcinomas, two follicular carcinomas and one anaplastic carcinoma. Diagnostic parameters calculated and found to be: Sensitivity: 85.7%; Specificity: 90.6%; Positive

transformation, thyroid carcinoma accounts for only 1% of diagnosed neoplasm in the United States each year. Conventional diagnostic approaches such as history taking, physical examination and routine laboratory tests are not always conclusive; therefore adjunctive tests like ultrasonography, FNAC and radionuclide scan are commonly used to improve diagnostic accuracy. Radionuclide thyroid scan determines whether a nodule is hot, warm or cold. A hot nodule is almost always benign however a cold nodule requires further diagnostic evaluation. In addition compared with inpatient observations and serial laboratory tests, thyroid imaging is cost effective. Most forms of thyroid cancers are treatable and curable<sup>7,8</sup>.

In this study we determined the utility and accuracy of gray-scale and colour doppler ultrasound in patients with suspected thyroid malignancy, as it will avoid unnecessary financial burden of inconclusive serial investigations. In our study the statistically significant features for the depiction of malignancy were entirely solid nodule with no cystic elements, spiculated margins, marked hypoechogenicity, micro-calcifications and cervical lymphadenopathy. Entirely solid nodule was seen in 60% histopathologically confirmed malignant cases. A predominantly solid component was observed in the majority of nodules. Therefore, a predominantly solid component alone cannot be a useful criterion for the differentiation of malignant from benign nodules. Frates et al in a randomized control trial of 254 patients at Harvard Medical School, Brigham and Women's hospital Boston, USA, arrived at the conclusion that a solid nodule on ultrasound of thyroid has a high chance of being malignant thus favouring results of my study<sup>9</sup>.

The margins of a nodule are important for characterization. In my study spiculated margins were suggestive of malignancy. It was seen in 5 cases which all turned out to be malignant thus making it an important sign. Frequency of hypoechogenicity was significantly different between benign and malignant nodules; however I observed that marked hypoechogenicity was more suggestive of malignant nodules. The presence of micro or macro calcification in a predominantly solid nodule increased cancer risk as compared with nodules without any calcification. Micro-calcifications have a high predictive value and correspond to calcified psamoma bodies that are typical of papillary cancer. Macro-calcifications or coarse calcifications seen in benign nodules are related to fibrosis and degeneration. Micro-calcifications were seen in 6 cases in this study, out of which 4 cases turned out to be malignant.

Intranodular flow was seen in 4 cases on colour doppler out of which 3 cases were malignant. Bozborra et al in a study of 81 patients

using colour doppler ultrasound and FNAC arrived at the conclusion that colour doppler ultrasound is an extremely accurate way of diagnosing malignancy in solitary thyroid nodule thus favouring result of my study<sup>10</sup>.

Moon et al<sup>11</sup> in a retrospective multicenter study on 8024 patients using FNAC and ultrasound to pick up malignancy in cases of solitary thyroid nodule, found ultrasound to be an extremely reliable tool to pick up malignancy thus favouring my study results.

In Pakistan thyroid cancer is responsible for 1.2% cases of all malignant tumours. Previous reports from this region show papillary thyroid cancer to constitute 57 to 89% of all thyroid malignancies. The female to male ratio is noted to be between 2.5 to 4:1, which is comparable to international data<sup>12</sup>.

## CONCLUSION

Gray-scale and colour doppler ultrasound is a most sensitive method to study nodular goitre and diagnose malignant thyroid nodules. Entirely solid hypoechoic nodule with no cystic element having spiculated margins, micro-calcifications and central flow are helpful sonographic findings pointing towards malignancy. Associated cervical lymphadenopathy with calcification or degeneration is a significant finding favouring malignancy. Despite ultrasound's ability to clearly identify malignant nodules, no single sonographic feature is reliable in differentiating malignant from benign thyroid nodules due to the overlap exists between them. Therefore histopathological diagnosis should be ascertained in all thyroid nodules considered malignant. Ultrasound of the thyroid gland is also a useful tool to correctly identify patients not having malignancy.

## CONFLICT OF INTEREST

This study has no conflict of interest to declare by any author.

## REFERENCES

1. Khati N, Adamson T, Johnson KS, Hill MC. Ultrasound of the thyroid and parathyroid glands. *Ultrasound Q*, 2003; 19: 162 - 76.

2. Kim EK, Park CS, Chung WY, Oh KK, Kim DJ, Lee JT, et al Cheong S P, Woung Y C. New sonographic criteria for recommending fine needle aspiration biopsy of nonpalpable solid nodules of the thyroid. *AJR AmJ Roentgenol*, 2002; 178: 687 - 91.
  3. Bartolotta TV, Midiri M, Runza G. Incidentally discovered thyroid nodules: incidence, and greyscale and colour Doppler pattern in an adult population screened by real-time compound spatial Sonography. *Radiol Med*. 2006; 111: 989-98.
  4. Tsantis S, Dimitropoulos N, Cavouras D, Nikiforidis G. Morphological and wavelet features towards sonographic thyroid nodules evaluation. *Comput Med Imaging Graph*, 2009; 33: 91-9.
  5. Papini E, Guglielmi R, Bianchini A, Crescenzi A, Tacconga S, Nardi F et al. Risk of malignancy in non palpable thyroid nodules; predictive value of Ultrasound and Colour Doppler features. *J Clin Endocrino Metab*, 2002; 87: 1941- 6.
  6. Chang BK, Desser TS, Mc Dougall IR, Weigel RJ, Jeffrey RB Jr. Common and uncommon sonographic features of papillary carcinoma. *J Ultrasound Med*, 2003; 22: 1083-93.
  7. Clark KJ, Cronan JJ, Scola FH. Colour Doppler Sonography: anatomic and physiologic assessment of the thyroid. *J Clin Ultrasound*; 1995; 23: 215-23.
  8. Marqusee E, Benson C, Frates MC, Doubilet PM, Larsen RR, Cibas ES, et al. Usefulness of ultrasonography in the management of nodular thyroid disease. *Ann Intern Med* 2000; 133: 696-700.
  9. Frates MC, Benson CB, Doubilet PM, Cibas ES, Marqusee E. Can color Doppler sonography aid in the prediction of malignancy of thyroid nodules? *JUltrasoundMed*, 2003; 22: 127-31.
  10. Bozbora A, Erbil Y, Ozarmagan S, Barbaros U, Sari S, Degirmenci B. Colour Doppler sonography in cold thyroid nodules for malignancy prediction. *Acta chir Belg* 2002; 102: 259-62.
  11. Moon WJ, Jung SL, Lee JH, Na DG, Baek JH, Lee YH, at al. Benign and malignant thyroid nodules: US differentiation--multicenter retrospective study. *Radiology*, 2008; 247: 762-70
  12. Shah SH, Muzaffar S, Soomro IN, et al. Morphological patterns and frequency of thyroid tumours. *J Pak Med Assoc*, 1999; 49: 131-3.
- .....