

## PLACENTAL MORPHOLOGY AT DIFFERENT MATERNAL HEMOGLOBIN LEVELS: A HISTOPATHOLOGICAL STUDY

Nazma Kiran, Alia Zubair, Tariq Masood Malik\*, Muhammad Ayyub\*\*, Iqbal Muhammad Khan\*\*

Army Medical College Rawalpindi, \*Combined Military Hospital Malir, \*\*Armed Forces Institute of Pathology

### ABSTRACT

**Objective:** To evaluate the histopathological parameters of the placenta like weight, infarct and syncytial knots, at different maternal hemoglobin levels, in both qualitative and quantitative manner.

**Study design:** Descriptive study

**Place and Duration of Study:** Army Medical College, National University of Sciences and Technology in collaboration with Department of Obstetrics and Gynecology, Military Hospital, Rawalpindi, Pakistan, from December 2011 to November 2012.

**Patients and Methods:** A total of 75 placentas were included, that were collected from full term mothers at the time of childbirth. Placental weight was taken without umbilical cord and gross placental infarcts were noted. Samples of placental tissue were taken and stained by haematoxylin and eosin (H&E). Microscopic study was done to evaluate placental infarcts and syncytial knots.

**Results:** Mean placental weight at normal and low maternal hemoglobin was  $581.67 \pm 83.97$ g and  $482.58 \pm 104.74$ g respectively. Gross placental infarcts were found in all cases having low maternal hemoglobin concentration (60% cases). Syncytial knots were found in all placentas but they were considerably more at decreasing levels of maternal hemoglobin ( $19.79 \pm 5.22$ ).

**Conclusion:** The present study showed decrease in placental weight, increase in placental infarcts and syncytial knot hyperplasia at low maternal hemoglobin concentration, displaying adaptive alterations.

**Keywords:** Low hemoglobin concentration, Placental infarcts, Placental morphology, Placental weight, Syncytial knots.

### INTRODUCTION

Anemia is the late manifestation of deficiency of nutrients needed for hemoglobin synthesis<sup>1</sup>. It is extremely common that severe anemia contributes to maternal morbidity and mortality<sup>2</sup>. It is assessed that anemia may be responsible for 40-60% of maternal deaths in developing countries. It causes deaths from cardiac failure, hemorrhage, infection and pre-eclampsia<sup>3</sup>.

According to WHO standards, anemia in pregnancy is present when the hemoglobin concentration in the peripheral blood is less than 11gm/dl<sup>2</sup>. According to WHO, at hemoglobin level of 10.0-10.9 gm/dl anemia is mild, at 7-9.9gm/dl; it is moderate anemia and < 7gm/dl concentration is seen in severe anemia<sup>4,5</sup>. Global prevalence of anemia in pregnant women is 41.8%, and in Pakistan it is 39.1%<sup>6</sup>. In many developing countries,

prevalence rates of up to 75% are reported<sup>7,8</sup>.

Placenta is the structure where the fetal and maternal tissues come in direct contact without rejection and it is the site of exchange between maternal and fetal circulation<sup>9</sup>. Different hemoglobin levels in pregnancy are associated with variable morphological changes in placenta, which show a clear reflection for the poor fetal outcome<sup>10</sup>. Increase in placental weight is associated with low hemoglobin level during pregnancy<sup>11</sup>. The effects of decreasing concentration of hemoglobin in placenta and birth weight have been evaluated in Mexico and a trend towards an increase in placental weight in patients with low hemoglobin levels is observed<sup>12</sup>.

The most frequent lesion observed in placentas at lower hemoglobin concentration is infarct, characterized by aggregation of the villi with marked narrowing, often obliteration of the intervillous space and coagulative necrosis of the villi<sup>11-12</sup>. The microscopic changes of the placental components at decreasing levels of hemoglobin studied in Bangladesh, confirmed that the pathological areas such as infarcts are

**Correspondence:** Dr Nazma Kiran, Army Medical College, Rawalpindi

Email: nazmakiran@hotmail.com

Received: 08 Feb 2013; Accepted: 10 Oct 2013

significantly increased and villous area is reduced in anemic placentas<sup>13</sup>.

Syncytial knots are clusters of syncytial nuclei at the surface of tertiary villi and develop in the third trimester, due to ischemic changes<sup>14,15</sup>. Quantitative changes in histological features of full term placenta at different hemoglobin levels, studied in India, revealed that the full term placenta shows marked increase in numbers of syncytial knots at low hemoglobin concentration<sup>16</sup>.

There is need to explore the extent of above mentioned structural changes, because severity of these histomorphological parameters i.e. placental weight, infarct and syncytial knots, is correlated with the efficiency of placenta to support the growth of a fetus, and low hemoglobin level is likely to be related to insufficient functioning of the placenta<sup>17</sup>. In the West, analysis of histopathological changes in placenta at different hemoglobin levels has been carried out but there are no such studies available in Pakistan. In order to address this issue we designed the present study.

The present study was aimed to evaluate the gross as well as histopathological parameters of the placenta, at different hemoglobin levels in both qualitative and quantitative manner, in our setup.

### **PATIENTS AND METHODS**

This descriptive study was carried out in Pathology Department of Army Medical College, Rawalpindi, National University of Sciences and Technology (NUST), Islamabad in collaboration with Military Hospital, Rawalpindi from December 2011 to November 2012. Non-probability convenience sampling was done. Placentas were obtained from 75 full-term pregnant women having different hemoglobin levels. The placentas of the mothers having systemic disorders i.e. diabetes mellitus, hypertension, asthma and antepartum hemorrhage were not included in the study.

Placentas were collected immediately after expulsion and washed in tap water to remove blood clots. Specimens were preserved in 10% formal saline and each placenta was given a laboratory number. Weight of the placenta was

taken without umbilical cord. Infarcts were noted on gross examination and extent of placental infarct was recorded in terms of percentage of infarcted area (nil/<5%, 5-25%, 25-50%, >50%) and their pattern of distribution (focal/multifocal/diffuse). The whole placenta was equally divided into 1 cm thick sections and infarcted areas were noted in each cm and percentage of the area showing infarct was noted. Three representative sections were taken i.e. one close to umbilical cord (A), one from periphery (C) and one from the mid of A and C (B). Additional sections were taken from pathological area, if any. One complete circular section was taken from umbilical cord (D). The tissues were kept in cassettes with proper labeling, processed and stained by H & E stain. The slides were then examined under light microscope for placental infarcts and syncytial knots. Presence or absence of placental infarcts was noted under 10x objective. Number of syncytial knots was counted erratically in five high power fields per slide from region A, B and C using 40x objective.

Data analysis was computer based using SPSS version 17. Percentages and mean values were calculated for different variables.

### **RESULTS**

The mean age of the mothers was 27 years and mean duration of pregnancy was 37 weeks. Among the 75 placentas, 15 cases exhibited normal hemoglobin level (>11g/dl). Hemoglobin level 10.0-10.9 gm/dl (mild anemia) was found in 19 cases (25.3%) with mean hemoglobin level of 10.4g/dl. Maximum number of cases (n 26) revealed hemoglobin level of 7-9.9 gm/dl (moderate anemia). Hemoglobin level < 7gm/dl (severe anemia) was found in 15 cases.

The mean value of placental weight at different hemoglobin levels is given in table-1.

Gross placental infarcts were not seen at normal hemoglobin levels while 21.1% (4 out of 19 cases) having hemoglobin level 10.0-10.9 gm/dl and all the specimens having hemoglobin level  $\leq$  9.9 gm/dl (n=41) showed placental infarcts covering 5-25% (% of total

surface area) of placental area. All placental infarcts were multifocal.

will affect the structure and function of placenta. Decreased hemoglobin concentration

**Table- 1: Placental weight and number of syncytial knots at different hemoglobin levels.**

Hemoglobin levels g/dl	Number of cases n	Placental weight (grams) Mean ± SD	Number of syncytial knots Mean ± SD
Normal ≥11g/dl	15	581.67 ± 83.97	11.27 ± 2.96
Mild anemia 10.0-10.9 gm/dl	19	545.95 ± 73.24	16.21 ± 3.25
Moderate anemia 7-9.9 gm/dl	26	499.15 ± 87.52	20.05 ± 4.96
Severe anemia <7g/dl	15	373.60 ± 83.48	23.87 ± 4.70

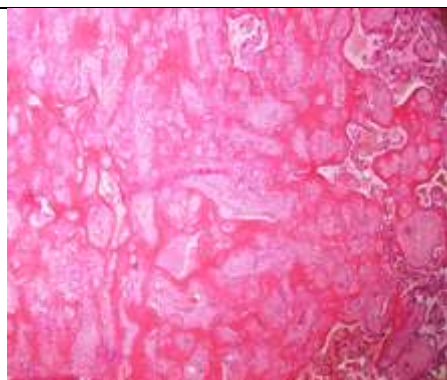


Figure-1: Photomicrograph of placental infarct at hemoglobin concentration 6.8 gm/dl exhibiting necrotic villi with obliterated intervillous space (H&E stain x 40).

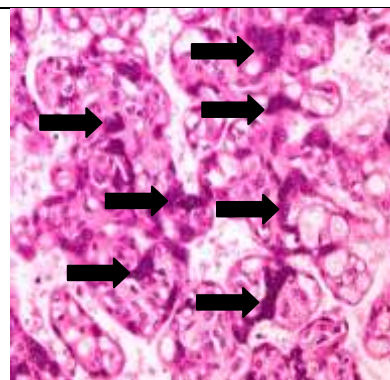


Figure-2 (a): Photomicrograph of placental tissue at hemoglobin level of 8.6 gm/dl displaying syncytial knot hyperplasia (H&E stain x 400).

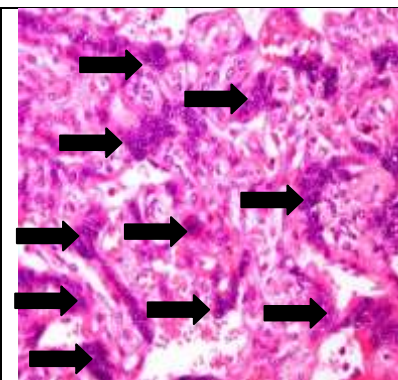


Figure-2 (b): Photomicrograph of placental tissue at hemoglobin level of 6.8gm/dl presenting syncytial knot hyperplasia (H&E stain x 400).

Placental infarcts were assessed histologically in a qualitative manner. At normal hemoglobin level, 60% (9 out of 15 cases) placental specimens showed infarcts, while at 10.0-10.9 gm/dl, 89.5% (17 out of 19 cases) placental specimens and at 7-9.9 gm/dl (n=26) and < 7 gm/dl (n=15) all placental specimens showed placental infarcts. Placental infarcts were seen at all hemoglobin levels but they were more common at low hemoglobin concentration.

The number of syncytial knots was remarkably increased in placentas at hemoglobin concentration 7-9.9 gm/dl and < 7gm/dl (20.05 ± 4.96 & 23.87 ± 4.70 respectively) where at normal hemoglobin level it was 11.27 ± 2.96 (Table-1) (Fig-2a & 2b).

**DISCUSSION**

The placenta is a functional component between fetus and mother. Therefore, any pathological incident related to mother or fetus,

during pregnancy is considered as a cause of pre-placental hypoxia which can give rise to fetal hypoxia and its complications. With this background, the current study was undertaken to evaluate the spectrum of histopathological changes in placenta at different hemoglobin levels.

The weight of the placenta is of significant importance and much information can be gathered by proper weight recording. It is functionally substantial as it is related to villous area<sup>18</sup>. Changes in placental weight are debatable. Few studies exhibit increased placental weight while some of the previous data revealed decrease in placental weight.

Huang et al documented increase in placental weight in mild and moderate degree of maternal anemia and it is shown to be significantly increased in severe anemia<sup>11</sup>. They suggested that placental hypertrophy is due to adequate compensatory capacity of anemic placentas. The effects of decreasing



concentration of hemoglobin on placental and birth weight have been evaluated in Mexico and an increase in placenta weight in patients having low hemoglobin concentration is observed<sup>12</sup>. An increase in placental weight in mild maternal anemia was also confirmed by Lao and Wong in 1997<sup>19</sup>. Roberts et al in 2008 studied maternal risk factors for abnormal placental growth and observed a greater probability of increased placental weight when hemoglobin concentration is low<sup>17</sup>. In a histomorphometric study of placentas at different hemoglobin levels, Reshetnikova et al found no placentomegaly<sup>20</sup>.

Decrease in weight of placenta with low hemoglobin concentration was stated by Mongia et al<sup>21</sup>. Histopathological analysis of placenta at different hemoglobin concentrations of anemia was done in Belgaum and it was found that the mean placental weight is less when hemoglobin concentration is below normal. The possible cause could be the reduced volume of placental villous and stromal tissue and more wide intervillous space as seen in current study.

Number of factors may contribute to these inconsistencies including difference in method of delivery, the amount of blood remaining in the placenta as well as collection and processing techniques<sup>18</sup>.

In current study placental infarcts were found to be significantly more at decreasing concentration of hemoglobin. Begum et al reported that placental infarcts increase significantly at low hemoglobin concentration<sup>13</sup>. According to Huang et al when pregnancy is associated with maternal anemia, placental infarcts occur which decreases the functional villous mass<sup>11</sup>. Both observations are similar to the present study.

When infarcts are located away from the placental margins, and particularly when they are haphazardly distributed, conditions of malperfusion always exist. Infarcts in any location in first and second trimester placentas are always abnormal. Placental infarcts that make up more than 5% of the placental mass are considered pathologic and may influence the fetal oxygen/nutrient state<sup>22</sup>.

In current study the number of syncytial knots was more at low hemoglobin levels. Mongia et al in 2011 studied histological features of placenta in anemia and showed an increase in the number of syncytial knots<sup>21</sup>. Adil and Nausheen in 2006 found high villous syncytial count in placentas of decrease hemoglobin concentration<sup>18</sup>.

Increased syncytial knotting is widely accepted as a diagnostic indicator of placental ischemia. Syncytium depends upon the maternal blood supply for its oxygen requirement and reduction of villous vascularity impairs the oxygenation of the syncytium. Excessive syncytial knots indicate reduced oxygenation of the fetal blood due to low haematocrit value of maternal blood<sup>18</sup>. This may be a possible explanation of increased syncytial knots at low hemoglobin concentration in the present study. Another study hypothesized that increased syncytial knots in placenta at low hemoglobin levels suggested that an effort is being made to form new villi so as to increase an effective surface area for exchange<sup>16</sup>.

## CONCLUSION

The present study showed marked decrease in placental weight, increase in placental infarcts, and syncytial knot hyperplasia at decreasing levels of maternal hemoglobin. Thus our study specified some of the adaptive alterations which placenta has to adapt to overwhelm the effects of low maternal hemoglobin concentration.

## CONFLICT OF INTEREST

This study has no conflict of interest to declare by any author.

## REFERENCES

1. Johnston TA. Anaemia. In: Luesley D, Baker P, Drife J, eds. *Obstetrics and gynaecology an evidence-based text for MRCOG*. Arnold, London 2004; 2: 131-5.
2. Buseri FI, Uko EK, Jeremiah ZA, Usanga EA. Prevalence and risk factors of anaemia among pregnant women in Nigeria. *Open Hematol J* 2008; 2: 14-9.
3. Jaleel R, Khan A. Severe anemia and adverse pregnancy outcome. *Int J Surg* 2008; 13: 147-150.
4. Regil LMD, Penarosas JP, Cusick S, Lynch S. Haemoglobin concentration for the diagnosis of anemia and assessment of severity. *Vitamin and mineral nutrition information system, department of nutrition for health and development, WHO* 2011.
5. Grewal A. Anaemia and pregnancy: Anaesthetic implications. *Indian J Anaesth* 2010; 54: 380-6.

6. Benoist BD, McLean E, Egli I, Cogswell M. Worldwide prevalence of anemia 1993-2005. WHO global database on anemia, WHO library cataloguing-in-publication data 2008.
  7. Broek, NVD. Anaemia and micronutrient deficiencies. *Br Med Bull* 2003; 67: 149-60.
  8. Awan MM, Akbar MA, Khan MI. A study of anemia in pregnant women of railway colony, Multan. *Pak J Med Res* 2004; 43: 11-4.
  9. Ross MH, Pawlina W. Female reproductive system. In: *Histology: a text and atlas with correlated cell and molecular biology*. Lippincott Williams & Wilkins, Baltimore 2011; 854-9.
  10. Raghunath G, Vijayalakshmi, Shenoy V. A study on the morphology and the morphometry of the human placenta and its clinical relevance in a population in Tamilnadu. *J Clin Diagn Res* 2011; 5: 282-6.
  11. Huang A, Zhang R, Yang Z. Quantitative (stereological) study of placental structures in women with pregnancy iron-deficiency anemia. *Eur J Obstet Gynecol Reprod Biol* 2001; 97: 59-64.
  12. Levario CM, Hernandez M, Vasquez ME, Chavez D, Sanchez C, Corral M. Effects of iron deficiency anemia on placenta and birth weight. *Ginecol Obstet Mex* 2003; 71: 75-81.
  13. Begum M, Ara S, Kishwara S, Nurunnabi ASM, Rayhan KA. Microscopic changes of the placental components in maternal anemia. *Bangl J Anat* 2010; 8: 59-63.
  14. Loukeris K, Sela R, Baergen RN. Syncytial knots as a reflection of placental maturity: Reference values for 20 to 40 weeks' gestational age. *Pediatr Dev Pathol* 2010; 13: 305-9.
  15. Saga Z, Minhas LA, Rehana R. Effects of altitude on morphology of human placenta with special reference to terminal villi and syncytial knots. *Int J Pathol* 2008; 6-11.
  16. Dhall U. Histological changes in placenta in anaemia, a quantitative study. *J Anat Soc India* 1994; 43: 21-6.
  17. Roberts KB, Salafia CM, Nicholson WK, Duggan N, Wang, NY, Brancati FL. Maternal risk factors for abnormal placental growth: The national collaborative perinatal project. *BMC Pregnancy Childbirth* 2008; 8: 44-51.
  18. Adil SAK, Nausheen R. Histopathological study of placenta in severe anemia during pregnancy. *J Evo Med Dent Sci* 2012; 4: 616-23.
  19. Lao TT, Wong WM. Placental ratio-its relationship with mild maternal anemia. *Placenta* 1997; 18: 593-6.
  20. Reshetnikova OS, Burton GJ, Teleshova OV. Placental histomorphometry and morphometric diffusing capacity of the villous membrane in pregnancies complicated by maternal iron-deficiency anemia. *Am J Obstet Gynecol* 1995; 173: 724-7.
  21. Mongia SM, Kumar JS, Mukesh Y. Placenta: The Wonder Organ. *J Indian Acad Forensic Med* 2011; 33: 140-2.
  22. Roberts DJ. *Placental Pathology, a Survival Guide*. *Arch Pathol Lab Med* 2008; 132: 641-51.
- .....