

Comparison of Haller Index Values Calculated with Chest Radiographs versus Computed Tomography for Pectus Excavatum Evaluation

Asma Afzal Kiani , Sara Haider , Sana Sharif*, Khadija tul Kubra**, Khushbu Fatima**, Nadia Murtaza

Department of Radiology, Combined Military Hospital, Peshawar/National University of Medical Sciences (NUMS) Pakistan, *Department of Radiology, PNS Shifa Hospital Karachi Pakistan, **Department of Radiology, Combined Military Hospital, Lahore/National University of Medical Sciences (NUMS) Pakistan

ABSTRACT

Objective: To compare and correlate the value of the Haller index calculated with chest x-ray with the values calculated with a Computed Tomography (CT) scan.

Study Design: Cross-sectional study.

Place and Duration of Study: Department of Radiology, Combined Military Hospital, Peshawar Pakistan, from Jan to Jun 2018.

Methodology: A total of 50 male patients aged ≥ 16 years presenting with pectus excavatum were included. Haller index was calculated after CT scan and X-ray.

Results: The mean age of the patients was 20.20 ± 2.34 years. The mean Haller Index for CT scan was 2.35 ± 0.39 , and the mean Haller Index for X-ray was 2.01 ± 0.45 . A strong and positive correlation existed between the Haller index for CT scans and X-rays ($r=0.83$).

Conclusion: X-rays can be used instead of CT scans to measure the Haller index and plan the surgical intervention with similar accuracy.

Keywords: CT scan, Chest radiograph, Pectus excavatum, X-ray.

How to Cite This Article: Kiani AA, Haider S, Sharif S, Kubra KT, Fatima K, Murtaza N. Comparison of Haller Index Values Calculated with Chest Radiographs versus Computed Tomography for Pectus Excavatum Evaluation. Pak Armed Forces Med J 2024; 74(1): 216-219. DOI: <https://doi.org/10.51253/pafmj.v74i1.7465>

This is an Open Access article distributed under the terms of the Creative Commons Attribution License (<https://creativecommons.org/licenses/by-nc/4.0/>), which permits unrestricted use, distribution, and reproduction in any medium, provided the original work is properly cited.

INTRODUCTION

Pectus excavatum, also known as anterior chest wall depression or sunken chest, is among the most common chest anomalies, which usually presents in infancy and progresses as the child grows.^{1,2} It is more prevalent in males and presents in one individual out of every four hundred and is found most commonly in members of the Caucasian ethnic group.³ This depression might be of variable severity, i.e. mild to severe. The extent and depth of this depression determines the degree of pulmonary as well as cardiac compression.⁴

With the advancement of minimally invasive thoroscopically assisted techniques, the most challenging question a surgeon faces is which patient would improve with surgical intervention.⁵ This decision may differ according to the cardiopulmonary compression, the patient's physical signs and symptoms, and the psychological impact of coping with this deformity. Another measurement which can impact the decision to operate is the Haller Index.⁶ It is

the ratio of the transverse dimension of the chest to the anteroposterior chest wall diameter taken at the point of maximum depression or deformity. The Haller Index has traditionally been described as taken on axial slices of the chest on computerized tomography (CT scan).^{7,8}

According to the standard guidelines, computed tomography (CT scan) determines the bony and cartilaginous chest wall deformity in children with pectus excavatum.^{9,10} This study aims to compare and correlate the value of the Haller index calculated with chest x-ray with the values calculated with CT scan (taken as reference). Furthermore, see if using X-rays as the standard modality to calculate the Haller Index at our hospital is feasible.

METHODOLOGY

The cross-sectional study was conducted at Department of Radiology, Combined Military Hospital (CMH), Peshawar Pakistan, from January to June 2018, after obtaining approval from the Hospital Ethical Review Committee (No. 37/21).

Inclusion Criteria: Male patients aged ≥ 16 years presenting to the Radiology Department after a referral from Orthopaedic or Surgical consultants for evaluation of pectus excavatum were included.

Correspondence: Dr Sana Sharif, Department of Radiology, PNS Shifa Hospital Karachi Pakistan
Received: 04 Oct 2021, revision received: 07 Dec 2021; accepted: 11 Apr 2023

Comparison of Haller Index Values Calculated

Exclusion Criteria: Patients with other anomalies, e.g., scoliosis, kyphosis, Marfan's syndrome, or pectus carinatum, were excluded.

The procedure and purpose of the study were explained to the patients and their attendants, and written informed consent was taken. Using a 64-slice GE light-speed VCT CT scanner, a non-contrast-enhanced chest CT scan was performed. Haller Index was calculated using a rotation time of 330 milliseconds, tube voltage of 120 kV, weight-based mAs and collimation of 64 x 0.625 mm.

Images were stored and retrieved from the GE PACS system. An axial slice of the CT scan at the site of maximum deformity (where the chest anteroposterior dimension was the least) was chosen. A line was drawn from the sternum's posterior surface to the vertebral body's anterior surface (line b). At the same level, another line was drawn horizontally, measuring the thoracic cage's maximal width from the ribs' inner margins on either side (line a). Haller's index was calculated by dividing the maximal width of the thorax by anteroposterior distance (Figure-1).

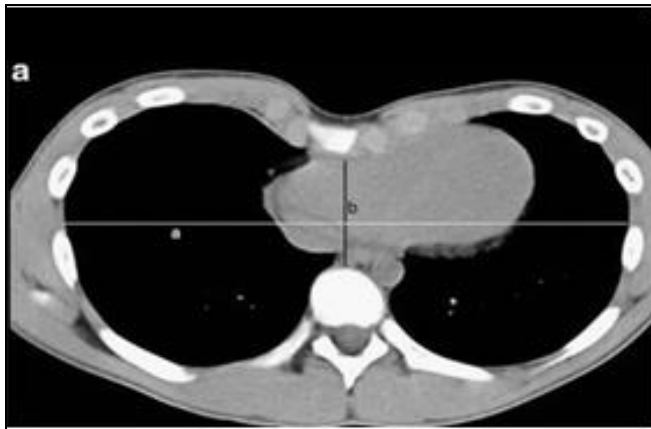

Figure-1: A Line is drawn from the posterior surface of sternum to the anterior surface of the vertebral body (line b). Another line drawn horizontally measuring maximal width of the thoracic cage (line a). The Haller's index was calculated by dividing the maximal width of thorax by antero-posterior height (Haller Index= a/b)

After the CT scan, a two-way chest x-ray was done in both postero-anterior and lateral views. This was achieved using a 300 mA Siemens x-ray machine, and the Haller Index was calculated according to the standard guidelines, as mentioned previously. A horizontal line was drawn on the lateral radiograph from the sternum's deepest portion to the vertebral body's anterior margin (line b). The level of this vertebral body was ascertained by counting from the 12th rib. The transverse diameter

of the chest was determined at the same vertebral body level on the postero-anterior view of the chest from the inner margins of the rib cage (line a). The ratio obtained was the radiographic Haller's index (Figure-2).

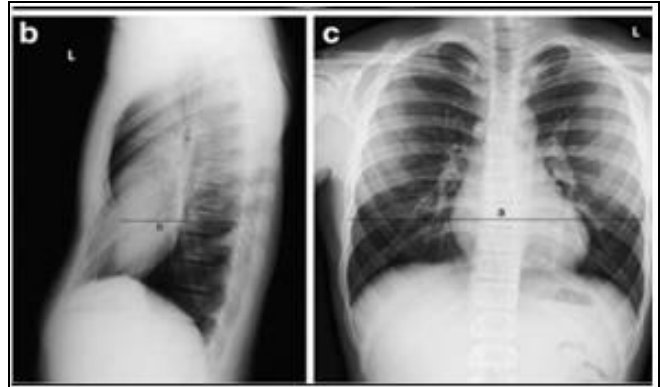


Figure-2: A horizontal line (line b) was drawn on the lateral radiograph from the deepest portion of the sternum to the anterior margin of the vertebral body. The level of this vertebral body was ascertained by counting from the 12th rib. The transverse diameter (line a) of the chest was determined at the same vertebral body level on postero-anterior view of chest. The ratio of these two lines (a/b), was the radiographic Haller's index

Statistical Package for Social Sciences (SPSS) version 25.0 was used for the data analysis. Quantitative variables were expressed as Mean±SD and qualitative variables were expressed as frequency and percentages. Pearson's correlation test was applied to measure the strength of the linear relationship between variables.

RESULTS

All the patients included in the study were male. The mean age of the patients was 20.20±2.34 years (Range 16-25 years). The mean Haller Index for CT scan was 2.35±0.39, with a minimum index of 1.70 and a maximum index of 3.30. The mean Haller Index for X-ray was 2.01±0.45, with a minimum index of 1.40 and a maximum index of 3.50 (Table). Pearson's correlation was used to determine the relationship between the Haller index for CT scans and the Haller index for X-rays. There was a strong and positive correlation (r=0.83) and was statistically significant.

Table: Comparison of Haller index for CT scan x-ray (n=50)

HALLER INDEX	CT SCAN	X- RAY	p-value
Mean±SD	2.35±0.39	2.01±0.45	<0.001

DISCUSSION

This study was conducted while working in an armed forces hospital, where many candidates for recruitment in Pakistan's military services have their medical tests carried out for physical fitness. These include chest radiographs for all candidates as a basic investigation and any radiological investigation for those candidates who require further evaluation in case of any specific clinical or medical query arising from the physical examination. Traditionally, only CT scans have been used to evaluate the Haller Index, and we applied the same principles to chest radiographs to establish if we were able to achieve comparable results, as CT scan machines are not always readily available in remote locations in Pakistan. Additionally, a CT scan is much more expensive and usually beyond the financial reach of most candidates and results in a much heavier radiation dose to the patient. Our purpose was to achieve the same results with plain chest radiographs, which are readily available, carry a significantly reduced radiation dose and are much cheaper.

Pectus excavatum is among the most common anterior chest anomalies involving the lower sternum near the xiphoid and the adjacent costal cartilages, resulting in decreased thoracic cavity anteroposterior diameter.¹¹ Pectus excavatum presents during childhood, and in some cases, it develops once an individual reaches the age of puberty. It usually results in impairment of cardio-respiratory functioning, and the patients may suffer from various negative psychological and social effects. In order to determine the degree of anterior chest wall deformity, many scales depend on the distance between the spine and sternum.¹²

Among the most recent scales, the Haller index is commonly used. It is calculated as the ratio between the horizontal distance of the inside of the ribcage and the shortest distance between the vertebrae and sternum.¹³ All these measurements are made with the help of a CT scan. This Haller index is used to determine the severity of the disease, and it helps plan surgical interventions. According to the studies, surgical intervention has been shown to improve the symptoms of pectus excavatum, i.e., reducing anterior chest wall depression and cardio-respiratory functioning, etc.¹⁴ Nowadays, the Nuss technique, also known as the minimally invasive operation, is used for the repair of pectus excavatum.¹⁵

The mean Haller index in our study was 2.35 ± 0.39 . This index was close to the normal range. According to the study, a Haller index value of 2.5 was considered normal, and this value was increased as the degree of chest deformity increases, i.e., it may reach 3.25 and a maximum of up to 5.5.¹⁶

When we compared the Haller index for CT scan with the Haller index for X-ray, there was a strong and positive correlation and was statistically significant ($0.706, p=0.05$). According to a study by Khanna *et al.*³ Haller index for X-rays strongly correlated with that calculated with a CT scan. They also suggested that X-rays can be used for the Haller index and surgical intervention planning. A similar study was conducted by Messerli *et al.*¹⁷ in which they documented limited low-dose CT exposure in the case of pectus excavatum in order to measure the index and cover the deepest parts of the pectus. A study by Poston *et al.*¹⁸ also favoured the use of X-ray for measuring the correction index in the case of pectus excavatum.

LIMITATIONS OF STUDY

There were certain limitations to our study. Firstly, we included a smaller number of patients. Secondly, most of the patients in our study had Haller index values near normal; and lastly, only young male members of society were included in our study. All these patients had mild or, at the most, moderate pectus excavatum and were either asymptomatic or had minor cardiac or respiratory symptoms. An extensive study with more patients, including both males and females and having patients with a Haller index of more than 3.0, should be conducted for an improved, extensive and enhanced study.

CONCLUSION

According to our study, an X-ray can be used instead of a CT scan to measure the Haller index and plan the surgical intervention.

Conflict of Interest: None.

Authors' Contribution

Following authors have made substantial contributions to the manuscript as under:

AAK & SH: Data acquisition, data analysis, critical review, approval of the final version to be published.

SS & KTK: Study design, data interpretation, drafting the manuscript, critical review, approval of the final version to be published.

KF & NM: Conception, data acquisition, drafting the manuscript, approval of the final version to be published.

Authors agree to be accountable for all aspects of the work in ensuring that questions related to the accuracy or integrity of any part of the work are appropriately investigated and resolved.

Comparison of Haller Index Values Calculated

REFERENCES

- 1- Lin C, Fishman E. Normal Radiologic Anatomy and Anatomical Variants of the Chest Relevant to Thoracic Surgery. In: Anzidei, M., Anile, M. (eds) Diagnostic Imaging for Thoracic Surgery. Springer, Cham, 2018. https://doi.org/10.1007/978-3-319-89893-3_62018;115-126.
- 2- Nuss D, Obermeyer RJ, Kelly RE Jr. Pectus excavatum from a pediatric surgeon's perspective. *Ann Cardiothorac Surg* 2016; 5(5): 493-500. <https://doi.org/10.21037/acs.2016.06.04>.
- 3- Khanna G, Jaju A, Don S, Keys T, Hildebolt CF. Comparison of Haller index values calculated with chest radiographs versus CT for pectus excavatum evaluation. *Pediatr Radiol* 2010 ; 40(11): 1763-1767. <https://doi.org/10.1007/s00247-010-1681-z>.
- 4- Chung CS, Myrianthopoulos NC. Factors affecting risks of congenital malformations. I. Analysis of epidemiologic factors in congenital malformations. Report from the Collaborative Perinatal Project. *Birth Defects Orig Artic Ser* 1975; 11(10): 1-22.
- 5- Koumbourlis AC. Pectus deformities and their impact on pulmonary physiology. *Paediatr Respir Rev* 2015; 16(1): 18-24. <https://doi.org/10.1016/j.prrv.2014.10.009>.
- 6- Ravitch MM. The operative treatment of Pectus excavatum. *Ann Surg* 1949; 129: 429-44.
- 7- Walsh DS, Ponsky TA, Bruns NE. The SAGES Manual of Pediatric Minimally Invasive Surgery. Springer Cham; 2017. <https://doi.org/10.1007/978-3-319-43642-5>.
- 8- Haller JA Jr, Kramer SS, Lietman SA. Use of CT scans in selection of patients for pectus excavatum surgery: a preliminary report. *J Pediatr Surg* 1987; 22(10): 904-906. [https://doi.org/10.1016/s0022-3468\(87\)80585-7](https://doi.org/10.1016/s0022-3468(87)80585-7).
- 9- Archer JE, Gardner A, Berryman F, Pynsent P. The measurement of the normal thorax using the Haller index methodology at multiple vertebral levels. *J Anat* 2016; 229(4): 577-581. <https://doi.org/10.1111/joa.12499>.
- 10- Haleem A, Hanif MS, Majeed FA, Din N, Wyne A, Rahim K, et al. Frequency of anomalies associated with chest deformity in physically fit male candidates reporting for military recruitment. *Pak Armed Forces Med J* 2015; 65(2): 170-174.
- 11- Iroegbu C, Zhongxi Z, Sheng T, Jiang B, Jingsong L. Pectus excavatum-insights into its diagnosis and the current treatment options along with its clinical outcomes: two case reports. *Int Sur J* 2018; 5(2): 756-764. <https://doi.org/10.18203/2349-2902.isj20180391>.
- 12- Haecker FM, Sesia S. Non-surgical treatment of pectus excavatum. *J Vis Surg* 2016; 2: 63. <https://doi.org/10.21037/jovs.2016.03.14>.
- 13- Swanson J, Avansino J, Phillips G, Yung D, Whitlock K, Redding G, et al. Correlating Haller Index and cardiopulmonary disease in pectus excavatum. *Am J Surg* 2012; 203(5): 660-664. <https://doi.org/10.1016/j.amjsurg.2011.12.013>.
- 14- Jaroszewski D, Ewais M, Chao C, Gotway M, Lackey J, Myers K, et al. Success of Minimally Invasive Pectus Excavatum Procedures (Modified Nuss) in Adult Patients (≥30 Years). *Ann Thorac Surg* 2016; 102(3): 993-1003. <https://doi.org/10.1016/j.athoracsur.2016.03.105>.
- 15- Zou X, Lin Y, Jin H, Cai S, Xu X, Yin W, et al. Screening for pectus excavatum among primary students and establishment of a pectus excavatum screening program in Dongguan, China. *J Thorac Dis* 2015; 7(5): 868-874. <https://doi.org/10.3978/j.issn.2072-1439.2015.04.48>.
- 16- Shaalan AM, Kasb I, Elwakeel EE, Elkamali YA. Outcome of surgical repair of Pectus Excavatum in adults. *J Cardiothorac Surg* 2017; 12(1): 72. <https://doi.org/10.1186/s13019-017-0635-z>.
- 17- Messerli-Odermatt O, Serrallach B, Gubser M, Leschka S, Bauer R, Dubois J, et al. Chest X-ray Dose Equivalent Low-dose CT with Tin Filtration: Potential Role for the Assessment of Pectus Excavatum. *Acad Radiol* 2020; 27(5): 644-650. <https://doi.org/10.1016/j.acra.2019.07.017>.
- 18- Poston PM, McHugh MA, Rossi NO, Patel SS, Rajput M, Turek JW. The case for using the correction index obtained from chest radiography for evaluation of pectus excavatum. *J Pediatr Surg* 2015; 50(11): 1940-1944. <https://doi.org/10.1016/j.jpedsurg.2015.06.017>.