

Forensic Age Estimation from Lower Third Molar Maturity Index

Ihsan Ullah, Hira Khurshid, Iftikhar Ahmed, Romisa Rehman*, Saad Atiq*

Khyber Girls Medical College Peshawar Pakistan, *Combined Military Hospital Peshawar/National University of Medical Sciences (NUMS) Pakistan

ABSTRACT

Objective: To estimate age from mandibular third molar maturation stages in the patient presenting to the Combined Military Hospital, Peshawar Pakistan.

Study Design: Cross-sectional.

Place and Duration of Study: Department of Dentistry, Combined Military Hospital, Peshawar Pakistan, from Jun to Jul 2021.

Methodology: One hundred and fifty participants of either gender, ages 14 to 24 years, with good quality orthopantomogram (OPG) showing mandibular third molar tooth germs and Pakistani nationals were included. Participants with hypodontia, oligodontia, Amelogenesis imperfecta, Dentinogenesis imperfecta, history of trauma /fracture in the third molar region and any systemic disease were excluded. Data like age, gender and tooth maturation stages of right mandibular molars were recorded.

Results: The mean age was 16.76±2.19 years. In 111(74.9%) cases, the variation in chronological age can be explained by mandibular third molar maturation stages. The only statistically significant predictor for age was Demirjian's stage of lower third molar ($p=0.002, 95\% \text{ CI}=3.643-15.442$), while gender was not a significant predictor.

Conclusion: The age can be estimated from the mandibular third molar with reliability in our population.

Keywords: Age estimation, Forensic age, Mandibular third molar, Third molar.

How to Cite This Article: Ullah I, Khurshid H, Ahmed I, Rehman R, Atiq S. Forensic Age Estimation from Lower Third Molar Maturity Index. *Pak Armed Forces Med J* 2023; 73(2): 531-534. DOI: <https://doi.org/10.51253/pafmj.v73i2.7364>

This is an Open Access article distributed under the terms of the Creative Commons Attribution License (<https://creativecommons.org/licenses/by-nc/4.0/>), which permits unrestricted use, distribution, and reproduction in any medium, provided the original work is properly cited.

INTRODUCTION

One of the important areas in forensic medicine is age estimation.¹ Forensic age estimation aid the authorities in detecting unidentified victims, the age of the dead, deciding the right to social benefits and dealing with undocumented refugees. Commonly radiographs are utilized as a means in human beings for age identification.²

The common radiographic methods in practice to estimate the age of persons are bone maturation and tooth developmental stages.^{3,4} Demirjian's method is of common staging index of tooth mineralization, which is reliable and non-invasive.^{5,6} Third molar calcification initiates at about seven years of age, formation of enamel ranges from 12 to 18 years, and completion of root formation between 18 and 25 years.⁷ Recent literature showed that mandibular third molar could be reliably used to estimate chronological age.^{8,9} A recent study showed that increasing stages of tooth mineralization were correlated with increasing age.¹⁰ However, most of the available literature is on other populations, and there needs to be more proper research on our population. Furthermore, the results can vary in different populations due to ethnic and genetic factors.

The objective of this study was to estimate the age from mandibular third molar maturation stages in the patient presenting to Combined Military Hospital (CMH), Peshawar Pakistan.

METHODOLOGY

The cross-sectional study was conducted at the Dentistry Department, Combined Military Hospital, Peshawar Pakistan, from June to July 2021 after IERB approval. The sample size was calculated through a correlation sample size calculator(G*power) using a correlation coefficient ($r=0.934$).¹¹ This study included one hundred and fifty cases by non-probability consecutive sampling technique.

Inclusion Criteria: Patients of either gender who visited for the dental treatment, aged 14 to 24 years, had good quality OPG showing mandibular third molar tooth germs bilaterally and were Pakistani nationals (based on NIC) were included in the study.

Exclusion Criteria: Participants with oligodontia, hypodontia, Amelogenesis imperfecta, Dentinogenesis imperfecta, history of trauma/fracture in the third molar region and any systemic disease were excluded from the study.

After a detailed explanation of the aim and benefits of this investigation, verbal informed consent was obtained from each participant. Demographic variables like age and gender were recorded. In

Correspondence: Dr Ihsan Ullah, Department of Forensic Medicine, Khyber Girls Medical College, Peshawar Pakistan
Received: 05 Sep 2021; revision received: 19 Jan 2022; accepted: 31 Jan 2022

addition, tooth maturation stages of the right mandibular molars were recorded using Demirjian's index from an OPG radiograph placed on a light illuminator by a single examiner. The details of Demirjian's calcification stage are: A) initial calcification, B) crown formation started, C) occlusal enamel has undergone completion, dentinogenesis initiated, the pulp chamber is curved lacking pulp horn, D) crown fully formed upto CEJ, the beginning of root development, the pulp chamber is curved and pulp horn formation initiated, E) root shorter than the crown, straight pulp chamber walls, pulp horns more differentiated, radicular bifurcation calcification started, F) pulp chamber looks like an isosceles triangle, radicular length is equal or more than coronal one, clear root shape due enough calcified bifurcation, G) root canal's walls look parallel, apices still open and H) completely closed root apex, the uniform periodontal membrane surrounding the root and apex.¹²

The collected data were analyzed using Statistical Package for the Social Sciences (SPSS) version 22.00. Mean and standard deviation were calculated for continuous data, while percentages and frequencies were for qualitative data. Linear regression analysis was run to estimate age from third molar maturation stages using age as a dependent variable and third molar maturation stages and genders as independent variables. The *p*-value of ≤ 0.05 was considered statistically significant.

RESULTS

The mean age of the study was 16.76 ± 2.19 years, ranging from 14 to 24 years. The most common stage of third molar maturation was stage with 73(48.6%) participants, followed by stage B had 37(24.67%) and stage D with 21(14%). The details are given in Figure-1.

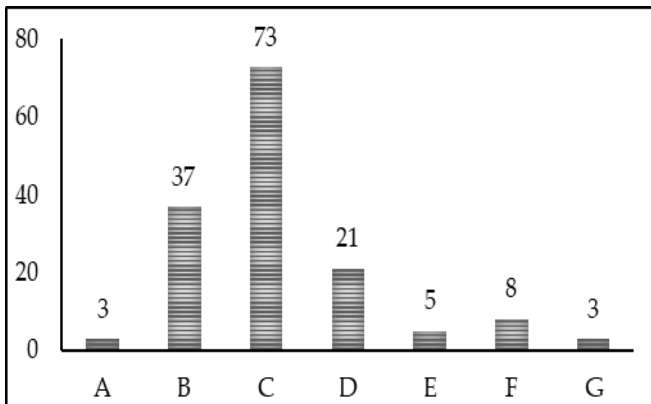


Figure- 1: Frequency of Various Stages of Third Molar from A to G (n=150)

The mean age increases as the third molar maturation stage increases. The mean ages in stages A, B, C, D, E, F, and G were 14.00 ± 0.01 , 15.51 ± 0.60 , 16.04 ± 0.88 , 17.95 ± 1.32 , 21.00 ± 1.73 , 21.75 ± 1.65 and 23.66 ± 0.57 years respectively. (Table-I).

Table-I: Mean of age by stages of third molar (n=150)

Demirjian's Stages of Third Molar	Range of Participants Ages (years)	Mean \pm SD of Participants Ages (years)
A	14-14	14.00 ± 0.01
B	14-17	15.51 ± 0.60
C	15-19	16.04 ± 0.88
D	15-19	17.95 ± 1.32
E	18-22	21.00 ± 1.73
F	20-24	21.75 ± 1.65
G	23-24	23.66 ± 0.57

Figure-2 shows a scatter plot between chronological age and third molar stages. There is a linear relationship between the two variables. In 111(74.9%) cases, the variation in chronological age could be explained by mandibular third molar maturation stages.

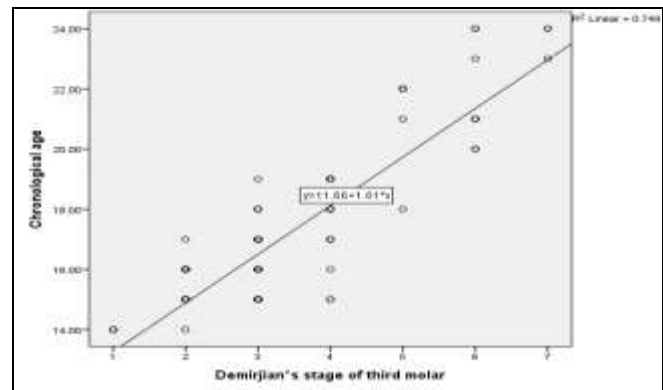


Figure-2: Scatter between Chronological Age and Lower Third Molar Stages (n=150)

The only statistically significant predictor for age was Demirjian's stage of lower third molar ($p = .002$, 95%CI=3.643-15.442), while gender was not a significant predictor for age estimation as shown in Table-II.

DISCUSSION

This study was performed to estimate age from the maturation stages of the mandibular third molar. Our findings showed a high correlation between the third molar and chronological age, and 74.9% of participants' ages could be estimated from the lower third molar in the age range of 14-24 years with statistical significance.

Table-II: Linear Regression Analysis (n=150)

Variables	Units of Measurement	Unstandardized Coefficients		Standardized Coefficients	t	p-value
		B	Std. Error	Beta		
(Constant)	-	11.828	0.385	-	30.706	<0.001
Demirjian's stage of third molar	Dummy (A=1, B=2, C=3, D=4, E=5, F=6, G=7)	1.626	0.080	0.872	20.373	<0.001
Gender	Dummy (male=1 female=2)	-0.122	0.206	-0.025	-0.592	0.555

Due to the recent increase in global crime, there is a need to determine age with accuracy.¹² Many parameters are available in the clinical practice of forensic medicine to determine the age of an individual, which is required for legal issue. The method used for age should be accurate, non-invasive to participants, not harmful to the clinician, need less financial burden and can be reusable on other occasions. OPG radiograph is normally required for any individual once a year for every individual as part of screening for dental and oral pathology.¹³ It is associated with minimum radiation exposure and is acceptable to most individuals.¹⁴

In this study, we selected the mandibular molar tooth on the right side. In the lower arch, there is no superimposition due to overlapping structures. In contrast, in the maxillary arch, there are overlapping structures like maxillary sinuses and buccal roots.¹⁵ The rationale for using right side tooth is always bilateral symmetry because a single gene is responsible for bilateral structure formation. We used Demirjian's method to determine maturation stages of the lower third molar. This method has many advantages like simplicity, reliability and no issue of magnification errors. Magnification has no effect because this method uses a proportion of crown and root formation, not actual length.^{16,17}

Our results showed a linear and high correlation between lower third molar and chronological age. Previous studies in other populations reported similar findings. 5,6, 8-10 Our regression model showed that in 74.9% of cases, this model could effectively estimate age in our population.

Our findings showed that gender was not a statistically significant covariate for age estimation from the third molar stage. It shows that this derived regression formula can be used for both genders equally. Similar findings were reported in a previous study by Ajmal *et al* in the Saudi population.⁶ However, other studies showed that there is diversity in results among gender while estimating age from tooth maturation stages.^{18,19}

However, this study has some limitations, like it is a single centre and hospital base and includes a small sample size. Large sample, multicenter and community base study can better address the issue of age estimation from the lower third molar.

CONCLUSION

Within the limits of this study, it can be concluded that mandibular third can be used in age estimation with reliability.

Conflict of Interest: None.

Author's Contribution

Following authors have made substantial contributions to the manuscript as under:

IU: Conception, study design, drafting the manuscript, approval of the final version to be published.

HK & IA: Data acquisition, data analysis, data interpretation, critical review, approval of the final version to be published.

RR & SA: Critical review, drafting the manuscript, approval of the final version to be published.

Authors agree to be accountable for all aspects of the work in ensuring that questions related to the accuracy or integrity of any part of the work are appropriately investigated and resolved.

REFERENCES

- Scendoni R, Zolotenkova GV, Vanin S, Pigolkin YI, Cameriere R. Forensic Validity of the Third Molar Maturity Index (I3M) for Age Estimation in a Russian Population. *Biomed Res IntS* 2020; 2020: 6670590. doi: 10.1155/2020/6670590.
- El-Bakary AA, El-Azab SM, Abou El Atta HM, Palacio LAV, Cameriere R. Accuracy of the cutoff value of the third molar maturity index: an Egyptian study. *Egypt J Forensic Sci* 2019; 9(1): 1-5. doi:10.1186/s41935-019-0156-0.
- Priyadharshini KI, Idiculla JJ, Sivapathasundaram B, Mohanbabu V, Augustine D, Patil S. Age estimation using development of third molars in South Indian population: A radiological study. *J Int Soc Prev Community Dent* 2015; 5(Suppl 1): S32-8. doi: 10.4103/2231-0762.156522.
- Kumar S, Singla A, Sharma R, Viridi MS, Anupam A, Mittal B. Skeletal maturation evaluation using mandibular second molar calcification stages. *Angle Orthod* 2012; 82(3): 501-506. doi: 10.2319/051611-334.1.
- Mestriner MB, Verquietini CM, Waisberg G, Akkari M, Fukunaga ET, Santili C. Radiographic evaluation in epiphysiolysis: possible predictors of bilaterality? *Acta Ortop Bras* 2012; 20(4): 203-306. doi: 10.1590/S1413-78522012000400001.

Forensic Age Estimation

6. Ajmal M, Assiri KI, Al-Ameer KY, Assiri AM, Luqman M. Age estimation using third molar teeth: A study on southern Saudi population. *J Forensic Dent Sci* 2012; 4(2): 63-65. doi: 10.4103/0975-1475.109886.
 7. Ajmal M, Assiri KI, Al-Ameer KY, Assiri AM, Luqman M. Age estimation using third molar teeth: A study on southern Saudi population. *J Forensic Dent Sci* 2012; 4(2): 63-65. doi: 10.4103/0975-1475.109886.
 8. Khosronejad A, Navabi M, Sakhdari S, Rakhshan V. Correlation between chronological age and third molar developmental stages in an Iranian population (Demirjian method). *Dent Res J (Isfahan)* 2017; 14(2): 143-149.
 9. Ashifa N, Parakh MK, Ulaganambi S. Estimation of Age Using Third Molar Development: A Radiological Cross-Sectional Study. *Am J Forensic Med Pathol* 2020; 41(2): 115-118. doi: 10.1097/PAF.0000000000000540.
 10. Franklin D, Flavel A, Noble J, Swift L, Karkhanis S. Forensic age estimation in living individuals: methodological considerations in the context of medico-legal practice. *Res Rep Forensic Med Sci* 2015; 5: 53-66. doi:10.2147/RRFMS.S75140.
 11. Schmeling A, Dettmeyer R, Rudolf E, Vieth V, Geserick G. Forensic Age Estimation. *Dtsch Arztebl Int* 2016; 113(4): 44-50. doi: 10.3238/arztebl.2016.0044.
 12. Verma M, Verma N, Sharma R, Sharma A. Dental age estimation methods in adult dentitions: An overview. *J Forensic Dent Sci* 2019 ; 11(2): 57-63. doi: 10.4103/jfo.jfds_64_19.
 13. Chandrasekar R, Chandrasekhar S, Sundari KKS, Ravi P. Development and validation of a formula for objective assessment of cervical vertebral bone age. *Prog Orthod* 2020 ; 21(1): 38. doi: 10.1186/s40510-020-00338-0.
 14. Franklin D, Swift L, Flavel A. 'Virtual anthropology' and radiographic imaging in the Forensic Medical Sciences. *Egypt J Forensic Sci* 2016; 6(2): 31-43. doi:10.1016/j.ejfs.2016.05.011.
 15. Naik SB, Patil SN, Kamble SD, Mowade T, Motghare P. Reliability of Third Molar Development for Age Estimation by Radiographic Examination (Demirjian's Method). *J Clin Diagn Res* 2014; 8(5): ZC25-28. doi: 10.7860/JCDR/2014/8160.4361.
 16. Signorelli L, Patcas R, Peltomäki T, Schätzle M. Radiation dose of cone-beam computed tomography compared to conventional radiographs in orthodontics. *J Orofac Orthop* 2016 ; 77(1): 9-15. doi: 10.1007/s00056-015-0002-4.
 17. Surendran S, Thomas E. Tooth mineralization stages as a diagnostic tool for assessment of skeletal maturity. *Am J Orthod Dentofacial Orthop* 2014; 145(1): 7-14. doi: 10.1016/2013.09.007.
 18. Lopes LJ, de Oliveira Gamba T, Visconti MA, Ambrosano GM, Haiter-Neto F, Freitas DQ. Utility of panoramic radiography for identification of the pubertal growth period. *Am J Orthod Dentofacial Orthop* 2016; 149(4): 509-515.
 19. Graber LW, Vanarsdall RL, Vig KW, Huang GJ. *Orthodontics-e-book: current principles and techniques*: Elsevier Health Sciences; 2016. https://books.google.com.pk/books/about/Orthodontics_E_Book.html?id=N0SwdAAAQBAJ&redir_esc=y
-