

CASE REPORTS

PRIMARY CNS LYMPHOMA MIMICKING TUBERCULOSIS INFECTION -
A CASE REPORT

Hassan Mumtaz, Shahzaib Ahmad*, Fatima Yasin*, Muhammad Ahsan Shafiq**

Shifa International Hospital, Islamabad Pakistan, *King Edward Medical University, Lahore Pakistan, **Holy Family Hospital, Rawalpindi Pakistan

ABSTRACT

Primary central nervous system lymphoma (PCNSL) is a rare variety of extra nodal non-Hodgkin lymphoma that reportedly involves leptomeninges, the brain, spinal cord, eyes, or may involve other organs systemically. We present a case of 46-year-old woman with complaints of headache and fever for three weeks, associated with right-sided weakness & altered state of consciousness for one week. The most common presentation of primary central nervous lymphoma is diffuse or multifocal supratentorial masses causing cognitive deterioration and involvement of vitreous, retina, and optic nerve. Most cases of PCNSL are left undiagnosed due to uncommon

Keywords: KI67, Non-Hodgkin lymphoma, Primary CNS lymphoma (PCNSL), Tuberculosis.

How to Cite This Article: Mumtaz H, Ahmad S, Yasin F, Shafiq MA. Primary CNS Lymphoma Mimicking Tuberculosis Infection - A Case Report. Pak Armed Forces Med J 2021; 71(6): 2253-2254. Doi: <https://doi.org/10.51253/pafmj.v71i6.7116>

This is an Open Access article distributed under the terms of the Creative Commons Attribution License (<https://creativecommons.org/licenses/by-nc/4.0/>), which permits unrestricted use, distribution, and reproduction in any medium, provided the original work is properly cited.

INTRODUCTION

Primary central nervous system lymphoma (PCNSL) is a rare variety of extra nodal non-Hodgkin lymphoma (NHL) that reportedly involves leptomeninges, the brain, spinal cord, eyes, or may involve other organs systemically.¹ The clinical presentation, pathologic features, and diagnosis of PCNSL in immunocompetent patients is different as compared to the immunocompromised individuals.²

PCNSL contributes around 4% of newly diagnosed primary central nervous system (CNS) tumors, with an overall annual incidence rate of four cases per million of the population.³

The differential of PCNSL may be an intravascular large cell lymphoma that commonly involves the central nervous system,⁴ but may be challenging due to highly variable clinical manifestations. An immunocompromised state of an individual entails a risk of various neoplasms that manifest similarly.⁵ In this case report, we present a case of CNS Lymphoma with "atypical" features and it was investigated by imaging studies and confirmed on histological testing.

CASE REPORT

A 46-year-old woman (non-diabetic, non-hypertensive, no history of cardiac disease, no tuberculosis (TB) infection or TB contact history) presented to our hospital with complaints of headache and fever for

three weeks, associated with right-sided weakness, and altered state of consciousness for one week. Headache was mild to moderate in intensity. It was associated with vomiting and visual disturbances, fever was of documented low grade, intermittent associated with rigors chills and night sweats with no diurnal variation. The patient also had a right-sided weakness with motor aphasia, and the patient was bedridden since the onset of symptoms. On examination, GCS was 10/15 (E2V2M5), pupils mildly dilated bilaterally, planters upward on right toes while downward on left toes, and on and off neck rigidity. There was harsh bilateral breathing on auscultation. Abdominal and cardiovascular system examination was not significant. Afterward, MRI was done, and the differential diagnosis of CNS TB, lymphomas, and metastatic disease with hydrocephalous were made. Patient was started on ATT and steroids for CNS TB with hydrocephalous. Lumbar puncture results were negative. There was no significant improvement in the patient's condition after the beginning of anti-tuberculous drugs. Bone scan also came back negative. A biopsy was planned with the suspicion of lymphoma, which came back positive for primary CNS lymphoma.

DISCUSSION

Primary Central Nervous Lymphoma (PCNSL) is one of the rare forms of extra nodal non-Hodgkin Lymphoma.⁶

The most common presentation of primary central nervous lymphoma is diffuse or multifocal supratentorial masses causing cognitive deterioration and

Correspondence: Dr Hassan Mumtaz, Medical Officer, Clinical Research Center, Shifa International Hospital, Islamabad Pakistan
Received: 16 Jul 2021; revision received: 23 Aug 2021; accepted: 30 Aug 2021

involvement of vitreous, retina, and optic nerve, both of these features were present in our patient.⁷ The MRI findings of PCNSL include the presence of iso- or hypo-intense signals on T1WI, iso- or slightly hyperintense signals on T2WI, hyperintense on FLAIR images, and plaque enhancement on contrast-enhanced images.⁸ The radiological findings in our patients correlated with these findings, additionally mild bilateral periventricular and right basal ganglia edema were also appreciated. Depending upon MRI, lymphomas were on top in differential while tuberculomas and metastatic disease were other differentials. Then, the final diagnosis was made on histopathology (Figure).

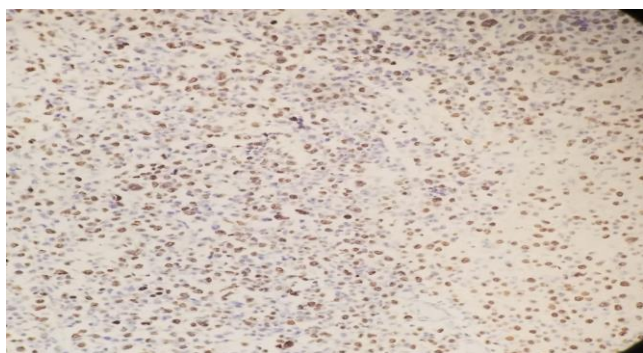


Figure: Histopathological Immunostained slide showing Primary CNS Lymphoma using Ki67 Proliferation Index (PI) 40% i.e Grade-3.

Firstly, the overall incidence is increased from last few years, and 5 and 10-year survival rate for PCNSL is 29.9% and 22.2%.⁹ Any patient who has a mass in CNS and diagnosis is getting confused & there is a strong suspicion of PCNSL, which would be a definite indication for stereotactic biopsy. There is strong evidence that PET-CT is superior to conventional MRI in diagnosing PCNSL and other CNS tumors.¹⁰ PET-CT facility was not available in our setting because of which differentials were made with the help of MRI imaging. One of the important things that come into account is that corticosteroids should always be used with caution before the definite diagnosis in case of CNS pathologies because they may interfere with the accuracy of the biopsy.

Primary central nervous system lymphoma (PCNSL) is an uncommon presentation clinically. The clinical signs and symptoms may not be sufficient for a clinician to reach a diagnosis of PCNSL. This condition is usually confused with CNS TB as occurred in this case. Several modalities like CT scan and CT guided biopsy or even open surgery may be required to reach to a histological confirmation of the tumor.

Conflict of Interest: None.

Authors' Contribution

HM: Manuscript design, SA: Data writing, FY: Data analysis, MA: Facilitation.

REFERENCES

1. Tsang M, Cleveland J, Rubenstein JL. On point in primary CNS lymphoma. *Hematol Oncol* 2020; 38(5): 640-647.
2. Lukas RV, Stupp R, Gondi V, Raizer JJ. Primary central nervous system lymphoma-part 1: epidemiology, diagnosis, staging, and prognosis. *Oncol (Williston Park)* 2018; 32(1): 17-22.
3. Villano JL, Koshy M, Shaikh H, Dolecek TA, McCarthy BJ. Age, gender, and racial differences in incidence and survival in primary CNS lymphoma. *Br J Cancer* 2011; 105(9): 1414-1418.
4. Braggio E, Van Wier S, Ojha J, McPhail E, Asmann YW, Egan J, et al. Genome-wide analysis uncovers novel recurrent alterations in primary central nervous system lymphomas. *Clin Cancer Res* 2015; 21(17): 3986-3994.
5. Nakamura T, Tateishi K, Niwa T, Matsushita Y, Tamura K. Recurrent mutations of CD79B and MYD88 are the hallmark of primary central nervous system lymphomas. *Neuropathol Appl Neurobiol* 2016; 42(3): 279-290.
6. Grommes C, De-Angelis LM. Primary CNS lymphoma. *J Clin Oncol* 2017; 35(21): 2410-2418.
7. Izquierdo C, Velasco R, Vidal N, Sánchez JJ, Argyriou AA, Besora S, et al. Lymphomatosis cerebri: a rare form of primary central nervous system lymphoma. Analysis of 7 cases and systematic review of the literature. *Neuro Oncol* 2016; 18(5): 707-15.
8. Sutherland T, Yap K, Liew E, Tartaglia C, Pang M, Trost N. Primary central nervous system lymphoma in immunocompetent patients: a retrospective review of MRI features. *J Med Imaging Radiat Oncol* 2012; 56(3): 295-301.
9. Ostrom QT, Gittleman H, Fulop J, Liu M, Blanda R, Kromer C, et al. CBTRUS statistical report: primary brain and central nervous system tumors diagnosed in the United States in 2008-2012. *Neuro Oncol* 2015; 17(Suppl-4): iv1-iv62.
10. Zeng X, Lu X, Li X, Peng L, Chen L. A case report of primary central nervous system lymphoma. *J Int Med Res* 2020; 48(7): 300060520937839.