

Diagnostic Accuracy of Magnetic Resonance Cholangiopancreatography in the Detection of Choledocholith, taking Post-Operative findings as the Gold Standard

Ayesha Javaid, Rashid Mahmood, Hidayat Ullah*, Mazhar Shafiq**, Nazia Dildar***, Ghulam Abbas****

Combined Military Hospital Sialkot/ National University of Medical Sciences (NUMS) Pakistan, *Frontier Medical & Dental College Abbottabad Pakistan, **Combined Military Hospital Kohat/National University of Medical Sciences (NUMS) Pakistan, *** Combined Military Hospital Kharian/National University of Medical Sciences (NUMS) Pakistan, **** Armed Forces Institute of Radiology & Imaging/National University of Medical Sciences (NUMS) Rawalpindi Pakistan

ABSTRACT

Objective: To assess the diagnostic accuracy of Magnetic resonance cholangiopancreatography (MRCP) in the detection of Choledocholith, taking post-operative findings as the gold standard.

Study Design: Cross-sectional validation study

Place and Duration of Study: Combined Military Hospital, Kharian Pakistan, from Jan 2020 to Jan 2021.

Methodology: Patients presenting with sonographic evidence of choledocholithiasis without any contraindications for magnetic resonance imaging were subjected to MRCP after informed consent. The patients who underwent surgery were followed up, and their per-operative findings were compared with the radiological findings of MRCP.

Results: A total of 87 patients were included in the study. The mean age of patients was 37.04±10.49 years (range of 22-65 years). The sensitivity for MRCP was 95%, specificity was 73.33%, positive predictive value (PPV) was 93.44%, and negative predictive value was 78.57%. The diagnostic accuracy for MRCP was found to be 90.66%.

Conclusion: The study shows that magnetic resonance cholangio-pancreatography is an effective imaging modality in diagnosing choledocholithiasis.

Keywords: Choledocholithiasis; Cholestasis; Jaundice; Magnetic resonance cholangiopancreatography (MRCP).

How to Cite This Article: Javaid A, Mahmood R, Ullah H, Shafiq M, Dildar N, Abbas G. Diagnostic Accuracy of Magnetic Resonance Cholangiopancreatography in the Detection of Choledocholith, taking Post-Operative findings as the Gold Standard. *Pak Armed Forces Med J* 2023; 73(2): 394-397. DOI: <https://doi.org/10.51253/pafmj.v73i2.7015>

This is an Open Access article distributed under the terms of the Creative Commons Attribution License (<https://creativecommons.org/licenses/by-nc/4.0/>), which permits unrestricted use, distribution, and reproduction in any medium, provided the original work is properly cited.

INTRODUCTION

Choledocholithiasis occurs in 5-15% of symptomatic gallstone cases. The common symptoms include jaundice, biliary colic and cholangitis. Choledocholithiasis can enhance the risk of complications such as pancreatitis and cholangitis with the associated increase in mortality and morbidity rates.¹ Thus, early detection and treatment of CBD stones is imperative due to its rising incidence.²

Preoperative evaluation of choledocholithiasis can be done with non-invasive and more invasive imaging methods. Non-invasive imaging techniques include Abdominal Ultrasonography (US) and Magnetic Resonance Cholangiopancreatography (MRCP), whereas more invasive techniques comprise Endoscopic Retrograde Cholangiopancreatography (ERCP), and Intra-operative Cholangiogram (IOC). Other suggested modes of assessment are CT cholangiography and Endoscopic Ultrasonography.³

The first line modality for bile duct obstruction is ultrasound, with a specificity of 95% in expert hands, followed by MRCP. The use of CT is limited due to

radiation risks involved.⁴ Thus, US, MRCP and ERCP are the modalities most commonly used as diagnostic tools for choledocholithiasis & correlated with LFT's.^{5,6}

Endoscopic Retrograde Cholangio-Pancreatography can very accurately detect calculi common bile duct along with delineating ductal anatomy and has the advantage of therapeutic potential.⁷ However, ERCP has significant morbidity and mortality. Cannulating duct could be, at times, difficult or even impossible in some patients with previous surgeries.⁸ Therefore, MRCP is often used instead of ERCP to investigate cases of benign biliary obstruction and chronic pancreatitis. This preference is because of the non-invasiveness of MRCP along with its better soft tissue resolution, multiplanar capability and differentiation of structures even without subjecting patients to ionized radiation and intravenous contrast.

The accuracy of Magnetic Resonance Cholangio-pancreatography in diagnosing CBD stones is 100%.⁹ However, some studies suggest limited use of MRCP due to its high cost and questionable negative predictive value.¹⁰ Therefore, the present study was carried out to understand and evaluate the diagnostic potential of MRCP for choledocholithiasis in our local context.

Correspondence: Dr Ayesha Javaid, Department of Radiology, Combined Military Hospital, Sialkot Pakistan

Received: 04 Jul 2021; revision received: 25 Oct 2021; accepted: 27 Oct 2021

METHODOLOGY

The cross-sectional validation study was conducted from January 2020 to January 2021 at CMH, Kharian Pakistan. Approval of the study was obtained from the Institutional Ethical Review Committee (Certificate number 37/2020). A sample size of 87 patients was calculated taking the prevalence of 6% for choledocholithiasis.¹¹

Inclusion Criteria: Patients presenting with evidence of choledocholithiasis on ultrasound were included in the study by non-probability consecutive sampling after getting informed consent if they were undergoing surgery.

Exclusion Criteria: Patients with the presence of obstructive jaundice due to reasons other than CBD stones and patients with contraindications for MRI, e.g. pacemakers, claustrophobia, and implantable cardiac defibrillators were excluded from the study.

Criteria for diagnosing choledocholithiasis were the visualization of stone in CBD and a common bile duct (CBD) diameter of more than 7 mm. In addition, the demographics of patients were noted. Magnetom Avanto system (1.5 Tesla), Germany, was used for MRCP, which an experienced radiologist reviewed. Fasting of 6 hours was mandatory for MRCP. The operative findings of patients were noted and considered the gold standard for comparison with MRCP findings.

Statistical Package for Social Sciences (SPSS) version 21.0 was used for the data analysis. Quantitative variables were expressed as mean±SD and qualitative variables were expressed as frequency and percentages. Diagnostic parameters were calculated using a 2x2 table. Sensitivity, specificity, positive predictive value, negative predictive value and diagnostic accuracy were determined by using the standard formulae.

RESULTS

A total of 87 patients were included in the study. The mean age of patients was 37.56±11.82 years, ranging from 22 to 66 years. The study included 17 (19.5%) males and 70(80.5%) females. Magnetic resonance cholangio-pancreatography showed 69 (79.3%) positive and 18(20.7%) negative results (Figure). Post-operatively 72(82.8%) cases were positive, and 15(17.2%) were negative(Table-I). Thus, there were 61(70.1%) true positive, 7(8%) true negative, 11(12.6%) false negative and 8(9.2%) false positive cases in the study with diagnostic parameters as given

in Table-II. The false positive and false negative cases showed other causes of CBD dilatation instead of calculi on surgery.

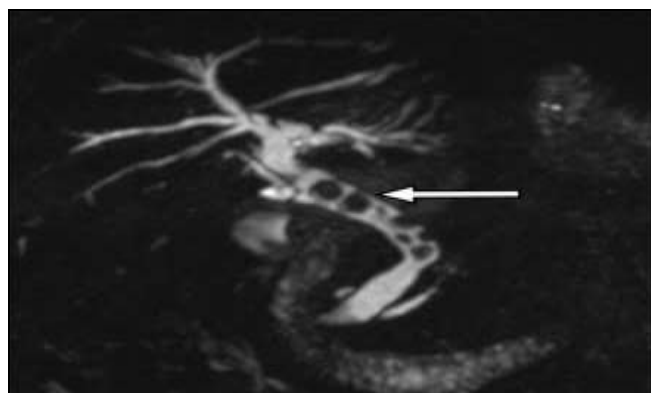


Figure: Magnetic Resonance Cholangiopancreatography (MRCP) Heavily T2 Weighted Half-Fourier Single-Shot Turbo Spin-Echo (HASTE) Sequence Image showing Dilated Common Bile Duct with Multiple Various Sized Filling Defects due to Choledocholithiasis

Table-I: Comparison of Magnetic Resonance Cholangiopancreatography (MRCP) and Post-Operative Results (n=87)

MRCP Results	Post-Operative Results	
	Positive	Negative
Positive	61(70.1%) (True positive; TP)	8(9.2%) (False Positive; FP)
Negative	11(12.6%) (False negative; FN)	7(8%) (True Negative; TN)

Table-II: Values of Diagnostic Parameters (n=87)

Diagnostic Parameters	Values
Sensitivity=True Positive/ (True Positive+False Negative)	84.72%
Specificity=True Negative/ (True Negative+False Positive)	46.66%
Positive Predictive Value=True Positive/ (True Positive+False Positive)	88.40%
Negative Predictive Value=True Negative/ (True Negative+False Negative)	38.88%
Diagnostic Accuracy=(True Positive+True Negative)/All Patients	78.16%

DISCUSSION

Choledocholithiasis has a prevalence of 5% to 20% in patients at the time of cholecystectomy general population.¹² It can result in life-endangering outcomes, including acute pancreatitis and acute cholangitis. The primary means of detecting choledocholithiasis includes clinical evaluation and abdominal ultrasound. However, the lack of sensitivity and specificity demands substitutional methods.¹³ As a result, and many approaches have been introduced, such as endoscopic ultrasound (EUS), magnetic

resonance cholangiopancreatography (MRCP), Endoscopic retrograde cholangiopancreatography (ERCP) and intra-operative cholangiography (IOC). While ERCP and IOC are considered standard imaging techniques but their use is linked with adverse issues such as pancreatitis, due to which their regular use in diagnosing choledocholithiasis is not advocated.¹⁴ On the other hand, EUS and MRCP are thought to be non-invasive imaging methods with high accuracy in diagnosing choledocholithiasis with lower adverse outcomes. However, the specificity and sensitivity of these methods still need to be determined.

In our study, the diagnostic attributes of MRCP included 95% sensitivity, 73.33% specificity, 93.44% positive predictive value (PPV) and 78.5% negative predictive value and 90.66% diagnostic accuracy. Virzi *et al.* assessed the utilization of MRCP for choledocholithiasis, which showed stones in 7 out of 106 patients (6.7%) with normal biochemical markers and ultrasonography. The study advocated the use of MRCP as a reliable means of diagnosing common bile duct stones.¹⁵

Anand *et al.* evaluated the significance of using MRCP and ERCP among patients with a high risk of choledocholithiasis. The study found that use of MRCP was associated with negative outcomes such as longer hospital stays and higher radiology and hospital charges without any significant effect on the outcomes.¹⁶ Badger *et al.* compared the efficiency of MRCP, ERCP and IOC in diagnosing choledocholithiasis. The sensitivity for MRCP was 90%, specificity was 86%, PPV was 97%, and NPV was 60%. However, the study discouraged the utilization of MRCP preceding these more invasive tests because of additional cost without changing the management plan of the patients.¹⁷

Orman *et al.* determined the diagnostic accuracy among choledocholithiasis patients with imaging modalities such as US, CT, MRCP and ERCP. MRCP was associated with a sensitivity of 86.4%, lower than expected. Moreover, the study stated that MRCP is usually preferable when a non-therapeutic diagnosis is required. Although MRCP was highly reliable in determining CBD dilation, it yielded low in discriminating location, size and number of stones.¹⁸

Qiu *et al.* inferred that MRCP had better diagnostic potential than the US. 44.95% of missed diagnostic cases were confirmed by MRCP. The study advocated the use of MRCP in case of fluctuations such as CBD diameter, enhanced alanine aminotransferase and concurrent acute cholecystitis.¹⁹

CONCLUSION

The present study supports the use of MRCP in diagnosing choledocholithiasis.

Conflict of Interest: None.

Author's Contribution

Following authors have made substantial contributions to the manuscript as under:

AJ & RM: Critical review, drafting the manuscript, approval of the final version to be published.

HU & MS: Data acquisition, data analysis, data interpretation, critical review, approval of the final version to be published.

ND & GA: Conception, study design, drafting the manuscript, approval of the final version to be published.

Authors agree to be accountable for all aspects of the work in ensuring that questions related to the accuracy or integrity of any part of the work are appropriately investigated and resolved.

REFERENCES

1. De Castro VL, Moura EG, Chaves DM, Bernardo WM, Matuguma SE, Artifon EL. Endoscopic ultrasound versus magnetic resonance cholangiopancreatography in suspected choledocholithiasis: A systematic review. *Endosc Ultrasound* 2016 ; 5(2): 118-128. doi: 10.4103/2303-9027.180476.
2. Chen YI, Martel M, Barkun AN. Choledocholithiasis: Should EUS replace MRCP in patients at intermediate risk? *Gastrointest Endosc* 2017 ; 86(6): 994-996. doi: 10.1016/j.gie.2017.07.034.
3. Pan S, Guo Q. Endoscopic ultrasonography versus magnetic resonance cholangiopancreatography for suspected choledocholithiasis: Comments from the radiologists'. *Endosc Ultrasound* 2016 ; 5(2): 129-131. doi: 10.4103/2303-9027.180477.
4. Sonnenberg A, Enestvedt BK, Bakis G. Management of Suspected Choledocholithiasis: A Decision Analysis for Choosing the Optimal Imaging Modality. *Dig Dis Sci* 2016 ; 61(2): 603-609. doi: 10.1007/s10620-015-3882-7.
5. Lee TY. Optimal Evaluation of Suspected Choledocholithiasis: Does This Patient Really Have Choledocholithiasis? *Clin Endosc* 2017 ; 50(5): 415-416. doi: 10.5946/ce.2017.146.
6. Morris S, Gurusamy KS, Sheringham J, Davidson BR. Cost-effectiveness analysis of endoscopic ultrasound versus magnetic resonance cholangiopancreatography in patients with suspected common bile duct stones. *PLoS One* 2015 ; 10(3): e0121699. doi: 10.1371/journal.pone.0121699.
7. Topal B, Van de Moortel M, Fieuws S, Vanbeckevoort D, Van Steenberghe W, Aerts R, et al. The value of magnetic resonance cholangiopancreatography in predicting common bile duct stones in patients with gallstone disease. *Br J Surg* 2003 ; 90(1): 42-47. doi: 10.1002/bjs.4025.
8. Morales SJ, Sampath K. A Review of Prevention of Post-ERCP Pancreatitis. *Gastroenterol Hepatol (N Y)* 2018 ; 14(5): 286-292.
9. Giljaca V, Gurusamy KS, Takwoingi Y, Higgie D, Poropat G, Štimac D, Davidson BR. Endoscopic ultrasound versus magnetic resonance cholangiopancreatography for common bile duct stones. *Cochrane Database Syst Rev* 2015; 2015(2): CD011549.
10. Aydelotte JD, Ali J, Huynh PT, Coopwood TB, Uecker JM, Brown CV. Use of Magnetic Resonance Cholangiopancreatography in Clinical Practice: Not as Good as We Once Thought. *J Am Coll Surg* 2015; 221(1): 215-219.

Diagnostic Accuracy of Magnetic Resonance

11. Meeralam Y, Al-Shammari K, Yaghoobi M. Diagnostic accuracy of EUS compared with MRCP in detecting choledocholithiasis: a meta-analysis of diagnostic test accuracy in head-to-head studies. *Gastrointest Endosc* 2017; 86(6): 986-993.
 12. Zahur Z, Jeilani A, Fatima T, Ahmad A. Transabdominal Ultrasound: A Potentially Accurate and Useful Tool For Detection Of Choledocholithiasis. *J Ayub Med Coll Abbottabad* 2019; 31(4): 572-575.
 13. Revzin MV, Scoutt LM, Garner JG, Moore CL. Right Upper Quadrant Pain: Ultrasound First! *J Ultrasound Med* 2017 ; 36(10): 1975-1985. doi: 10.1002/jum.14274.
 14. Chandrasekhara V, Khashab MA, Muthusamy VR, Acosta RD, Agrawal D, Bruining DH, et al. Adverse events associated with ERCP. *Gastrointest Endosc* 2017; 85(1): 32-47.
 15. Virzi V, Ognibene NMG, Sciortino AS, Culmone G, Virzi G. Routine MRCP in the management of patients with gallbladder stones awaiting cholecystectomy: a single-centre experience. *Insights Imaging* 2018 ; 9(5): 653-659.
 16. Anand G, Patel YA, Yeh H-C, Khashab MA, Lennon AM, Shin EJ, et al. Factors and Outcomes Associated with MRCP Use prior to ERCP in Patients at High Risk for Choledocholithiasis. *Can J Gastroenterol Hepatol* 2016; 2016: 5132052. doi: 10.1155/2016/5132052.
 17. Badger WR, Borgert AJ, Kallies KJ, Kothari SN. Utility of MRCP in clinical decision making of suspected choledocholithiasis: An institutional analysis and literature review. *Am J Surg* 2017 ; 214(2): 251-255. doi: 10.1016/j.amjsurg.2016.10.025.
 18. Orman S, Senates E, Ulasoglu C, Tuncer I. Accuracy of Imaging Modalities in Choledocholithiasis: A Real-Life Data. *Int Surg* 2018; 103(3-4): 177-183.
 19. Qiu Y, Yang Z, Li Z, Zhang W, Xue D. Is preoperative MRCP necessary for patients with gallstones? An analysis of the factors related to missed diagnosis of choledocholithiasis by preoperative ultrasound. *BMC Gastroenterol* 2015; 15: 158-62. doi: 10.1186/s12876-015-0392-1.
-