

Immunohisto Chemical Expression of IDH1, ATRX and P53 in Low Grade Diffuse Gliomas at Armed Forces Institute of Pathology, Rawalpindi

Ayesha Arif, Farhan Akhtar*, Ahmed Ahson, Hafeez Uddin, Rabia Ahmed**, Aminah Ahmed***

Armed Forces Institute of Pathology/National University of Medical Science (NUMS) Rawalpindi Pakistan, *Army Medical College/National University of Medical Science (NUMS) Rawalpindi Pakistan, **Pakistan Naval Ship Shifa Hospital, Karachi Pakistan, ***Rehman Medical College, Peshawar Pakistan

ABSTRACT

Objective: To determine the immune histochemical expression of IDH1, ATRX and p53 in low-grade diffuse gliomas.

Study Design: Cross-sectional study.

Place and Duration of Study: Department of Histopathology, Armed Forces Institute of Pathology, Rawalpindi Pakistan, from Jan to Jun 2020.

Methodology: Forty-two cases of low-grade diffuse glioma were included in the study. The cases were stratified into diffuse astrocytoma and oligodendroglioma based on results of immunohistochemistry expression for IDH1, ATRX and p53.

Results: The frontal lobe was the most commonly affected site 14 (33.3%). Based on the results of immunohistochemistry expression, 26 cases (61.9%) were diagnosed as an oligodendroglioma, while 16 cases (38.1%) were diagnosed as diffuse astrocytoma. All cases were assigned who grade II out of IV. In oligodendrogliomas, all cases (100%) were IDH1 mutants with the retained expression of ATRX and wild type expression of p53. Among the 16 cases of diffuse astrocytoma, IDH1 was mutant in 12 cases (75%), ATRX expression was lost in all cases, and p53 was mutant in 6 cases (37.5%).

Conclusion: The study showed that low-grade diffuse gliomas could be stratified and sub-classified in accordance with the World Health Organization (WHO) classification of CNS tumours (2016) successfully by application of immunohistochemistry for IDH1, ATRX and p53.

Keywords: ATRX, Diffuse glioma, IDH1, Low grade, p53.

How to Cite This Article: Arif A, Akhtar F, Ahson A, Uddin H, Ahmed R, Ahmed A. Immunohisto Chemical Expression of IDH1, ATRX and P53 in Low Grade Diffuse Gliomas at Armed Forces Institute of Pathology, Rawalpindi. *Pak Armed Forces Med J* 2022; 72(3): 754-757. DOI: <https://doi.org/10.51253/pafmj.v72i3.6851>

This is an Open Access article distributed under the terms of the Creative Commons Attribution License (<https://creativecommons.org/licenses/by-nc/4.0/>), which permits unrestricted use, distribution, and reproduction in any medium, provided the original work is properly cited.

INTRODUCTION

Low-grade diffuse gliomas account for approximately 20% of all primary brain malignancies.¹ Gliomas have been sub-classified for the longest time based on their morphological similarity to the origin cell and differentiation degree. In 2016, the latest published update of the World Health Organization (WHO) classification of the central nervous system (CNS) tumours mandated the incorporation of molecular alterations along with the microscopic features for the complete diagnosis of gliomas.² Previously, all astrocytic tumours had a separate category, but both astrocytic and oligodendroglial tumours are currently grouped as diffusely infiltrating gliomas. The diffuse gliomas include astrocytoma, oligodendroglioma, oligoastrocytoma and glioblastoma. The classification considers the tumour growth pattern, clinical behaviour, and mutations of IDH1 and IDH2 genes.³ The behaviour of the majority of low-grade gliomas belonging to WHO Grade-II is considered more favourable than the more

aggressive high-grade gliomas. However, 50–75% of cases of low-grade gliomas tend to show accelerated growth and progression to a higher grade.⁴ In order to better stratify the risks of progression, molecular classification of CNS tumours was incorporated as enhanced understanding and insights of driving mutations of the tumours have become available.

2016 WHO classification of CNS tumours sub-classifies diffuse gliomas based on the mutational presence of Isocitrate Dehydrogenase (IDH), ATRX chromosome 1p and 19q (1p/19q) co-deletion. Other molecular markers of note include p53, Ki67 and TERT.⁵ IDH is a crucial enzyme of the Krebs cycle. IDH mutations are speculated as an initial preliminary event in glioma-genesis.⁶ Diffuse gliomas can harbour both IDH1 and IDH2 genetic mutations. Mutations in IDH1 are most prevalent, the commonest being in codon IDH1 (R132H), which occurs in most gliomas. The mutations in IDH are detected in all oligodendroglioma cases and 70–80% cases of astrocytomas.⁷ IDH mutant gliomas have improved prognostic outcomes compared to IDH wild type.⁸ IDH1/2 mutations can be identified by immunohistochemistry (IHC)

Correspondence: Dr Ayesha Arif, Department of Pathology, Armed Force Institute of Pathology, Rawalpindi-Pakistan

Received: 07 Jun 2021; revision received: 21 Oct 2020; accepted: 28 Oct 2021

staining and/or Polymerase Chain Reaction (PCR).⁹

TP53 is considered the guardian of the genome and an important tumour suppressor gene mutated in approximately 50% of astrocytomas and 10% of oligodendrogliomas. Concomitant IDH, ATRX and TP53 mutations can be regarded as a molecular signature of astrocytomas.¹⁰ TP53 mutation can be ascertained by immuno histochemistry staining and/or DNA sequencing.

This study aimed to classify low-grade diffuse gliomas based on immuno histochemical staining and expression of the IDH1, ATRX and p53 markers on tissue samples.

METHODOLOGY

After approval from the Review Board (FC-HSP17-23/READ-IRB/18/903) of the Armed Forces Institute of Pathology (AFIP), Rawalpindi Pakistan, this cross-sectional study was carried out at the Department of Histopathology, AFIP, from January 2020 to June 2020.

Forty-two patients were included in the study by non-probability, consecutive sampling. The sample size was calculated using the WHO sample size calculator.¹¹

Inclusion criteria: Patients aged 3-70 years, with low-grade diffuse glioma were included in the study.

Exclusion Criteria: Patients with inappropriately fixed tissue, patients who already received chemo or radiotherapy or recurrent tumours were excluded from the study.

Patient data like name, age, gender and tumour location were recorded. Initially, Hematoxylin and Eosin (H&E) slides were prepared from formalin-fixed paraffin-embedded (FFPE) tissue sections. Immuno histochemistry using IDH1, ATRX and p53 antibodies (DAKO) was performed per the manufacturer’s protocol. For IDH1, cytoplasmic staining in more than 10% of tumour cells was taken as an equivalent to IDH-mutant type.¹¹ Loss of nuclear staining of ATRX in >90% of tumour cells was considered as ATRX loss/ ATRX-mutant.¹² Nuclear positivity of p53 in more than 50% of tumour cells was labelled as p53 mutant.¹³

The cases were classified into diffuse astrocytoma and oligodendroglioma based on immuno histochemistry results for IDH1, ATRX and p53. All of the data was recorded in the proforma.

Statistical Package for Social Sciences (SPSS) version 22.0 was used for the data analysis. Mean and standard deviation was calculated for age. Frequency

and percentage were calculated for qualitative variables like gender, tumour type, tumour grade, and expression of IDH1, ATRX and p53 and the Chi-square test was applied. The *p*-value of ≤0.05 was considered statistically significant.

RESULTS

Out of 42 cases of low-grade diffuse glioma, the mean age of patients in our study was 35.31 ± 16.23 years, with an age range from 3 to 70 years. Thirty-three males (78.6%) and nine females (21.4%). The frontal lobe was the commonest affected site (n=14, 33.3%) followed by temporal lobe (n=11, 26.2%), fronto parietal region (n=5, 11.9%), cerebellum (n=4, 9.5%), temporoparietal region (n=3, 7.1%), and fronto temporal region, occipital lobe, parietal lobe and pineal region (n=1, 2.4% each). Based on results of immuno histochemistry, 26 cases (61.9%) were diagnosed as oligodendrogliomas, while 16 cases (38.1%) were diagnosed as diffuse astrocytoma. All cases were assigned WHO grade II out of IV. All oligodendro-gliomas (100%) cases were IDH1 mutants with the retained expression of ATRX and wild type p53 expression. Among the 16 cases of diffuse astrocytomas, IDH1 was mutant in 12 cases (75%) while IDH was wild type in 4 cases (25%), *p*=0.007. ATRX showed loss of expression in all cases. p53 was mutant in 6 cases (37.5%) and wild type in 10 cases (62.5%), *p*=0.001 as shown in the Table.

Table: Comparison of IDH1, ATRX, p53 with Low grade diffuse gliomas.

Immunohisto-chemistry	Diffuse Astrocytoma	Oligodendro-glioma	<i>p</i> -value
IDH1			
Mutant	12 (75%)	26 (61.9%)	0.007
Wild Type	4 (25%)	-	
ATRX			
Loss	16 (38.1%)	-	<0.001
Retained	-	26 (61.9%)	
p53			
Mutant	6 (37.5%)	-	0.001
Wild Type	10 (62.5%)	26 (61.9%)	

DISCUSSION

The WHO CNS classification, 2021, has recommended incorporating immuno histochemical analysis and molecular genetic evaluation studies as an integral component in the classification of diffuse gliomas. It facilitates the stratification of patients into prognostic subcategories, which allows the individualization and optimized augmentation of treatment.^{14,15}

The frontal lobe was the most common location (n=8, 50%) for diffuse astrocytoma, while the temporal

lobe was the most prevalent site for oligodendroglioma (n=9, 34.6%). This is in concordance with a study conducted at the same centre by Ahsan *et al.*¹⁶

Based on IHC analysis, 26 cases (61.9%) were diagnosed with oligodendroglioma while 16 cases (38.1%) had diffuse astrocytoma. All cases were graded as WHO grade II. Among the 16 cases of diffuse astrocytomas, IDH1 was mutant in 12 cases (75%), ATRX was lost in all cases, and p53 was mutant in six cases (37.5%). The pictorial view of a few cases of oligodendrogliomas was shown in Figures (A-D).

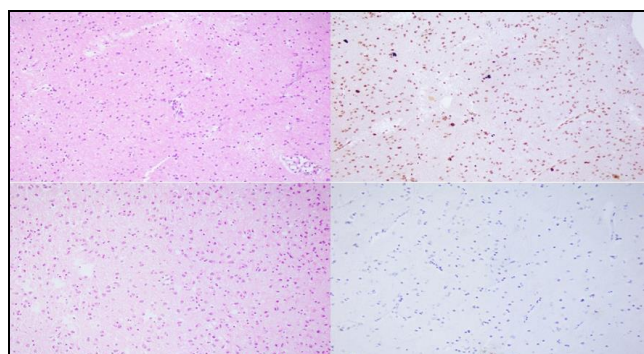


Figure (A-D): (A): SOL Frontal lobe Oligodendroglioma WHO grade-II, (B): IDH1, Mutant-Oligodendroglioma WHO grade II, (C): SOL Temporoparietal lobe-Diffuse glioma WHO grade-II, (D): ATRX Loss-Diffuse glioma WHO grade II.

Our results were comparable with the studies conducted in various parts of the world. In Lahore, Pakistan, the study showed IDH1 mutation by immunohistochemistry in 28/34 (82.4%) diffuse astrocytomas.¹⁷ In an Indian study, IDH1 mutation was observed in 80% (20/25), ATRX mutation was seen in 87% (20/23), and overexpression of p53 was found in 44% (11/25) of diffuse astrocytomas.¹³ The frequency of IDH1 mutation was 67.8%, ATRX mutation was 57.1%, and p53 overexpression was 48.24% in a study conducted in Guangzhou, China.¹⁵ In another Chinese study, IDH1 mutation was detected in 57.81%, while ATRX mutation was found in 76.56% of diffuse astrocytoma.¹⁸

In our study, all oligodendrogliomas were IDH1 mutants with the retained expression of ATRX and wild type p53. However, IDH1 mutation was observed in a Chinese study in 9/12 (75%) while ATRX mutation in 1/12 (8.33%) of oligodendrogliomas.¹⁸

The study showed that low-grade diffuse gliomas could be stratified and subclassified in accordance with the World Health Organization (WHO) classification of CNS tumours 2021 successfully by application of immunohistochemistry for IDH1, ATRX and p53. Addi-

tional studies like IDH PCR and FISH for 1p 19q co-deletion should be done for confirmation.

LIMITATIONS OF STUDY

In our setup lack of awareness of the current prognostic implications of these tests and the financial restraints, it was not always possible to do the complete workup. Routine immunohistochemistry cannot assess 1p19q co-deletion.

CONCLUSION

This study demonstrated that low-grade diffuse gliomas can be effectively categorized by immuno histochemistry according to the integrated approach recommended by the latest WHO classification of CNS tumours, 2021. Nevertheless, there is a greater emphasis on molecular markers in terms of classification and grading, so immuno histochemistry evaluation should also be validated by additional molecular testing.

Conflict of Interest: None.

Author's Contribution

AA:, AA: Writing, FA: Title selection, AA: Proof reading, HU: Final correction, RA: Correction.

REFERENCES

- Louis DN, Perry A, Reifenberger G. The 2016 World Health Organization classification of tumors of the Central Nervous System: a summary. *Acta Neuropathol* 2016; 131(6): 803-820.
- Louis DN, Ohgaki H, Wiestler OD, Cavenee WK. World Health Organization Histological Classification of Tumours of the Central Nervous System. International Agency for Research on Cancer, France. *Acta Neuropathol* 2016; 131(6): 803-820.
- Lai A, Kharbanda S, Pope WB, Tran A. Evidence for sequenced molecular evolution of IDH1 mutant glioblastoma from a distinct cell of origin. *J Clin Oncol* 2011; 29(34): 4482-4490.
- Chaichana KL, McGirt MJ, Lattner J, Olivi A, Hinojosa AQ. Recurrence and malignant degeneration after resection of adult hemispheric low-grade gliomas. *J Neurosurg* 2010; 112(1): 10-17.
- Mur P, Mollejo M. Molecular classification defines 4 prognostically distinct glioma groups irrespective of diagnosis and grade. *J Neuropath Exp Neurol* 2015; 74(3): 241-209.
- Watanabe T, Nobusawa S, Kleihues P, Ohgaki H. IDH1 mutations are early events in the development of astrocytomas and oligodendrogliomas. *Am J Pathol* 2009; 174(4): 1149-1153.
- Balss J, Meyer J, Mueller W, Korshunov A, Hartmann C, von Deimling A. Analysis of the IDH1 codon 132 mutation in brain tumors. *Acta Neuropathol* 2008; 116(6): 597-602.
- Santosh V, Sravya P, Gupta T, Muzumdar D, Chacko G, Suri V, et al. ISNO consensus guidelines for practical adaptation of the WHO 2016 classification of adult diffuse gliomas. *Neurol India* 2019; 67(1): 173-182.
- Liu X-Y, Gerges N, Korshunov A, Sabha N, Khuong-Quang DA, Fontebasso AM. Frequent ATRX mutations and loss of expression in adult diffuse astrocytic tumors carrying IDH1/IDH2 and TP53 mutations. *Acta Neuropathologica* 2012; 124(5): 615-625.
- Gillet E, Alentorn A, Doukouré B, Mundwiller E, van Thuijl HF. TP53 and p53 statuses and their clinical impact in diffuse low grade gliomas. *J Neurooncol* 2014; 118(1): 131-139.

Immunohisto Chemical Expression of IDH1, ATRX and P53

11. Takano S, Ishikawa E, Sakamoto N. Immunohistochemistry on IDH 1/2, ATRX, p53 and Ki-67 substitute molecular genetic testing and predict patient prognosis in grade III adult diffuse gliomas. *Brain Tumor Pathol* 2016; 33(2): 107-116.
 12. Ikemura M, Shibahara J, Mukasa A, Takayanagi S, Aihara K, Saito N. Utility of ATRX immunohistochemistry in diagnosis of adult diffuse gliomas. *Histopathology* 2016; 69(2): 260-267.
 13. Chatterjee D, Radotra BD. IDH1, ATRX, and BRAFV600E mutation in astrocytic tumors and their significance in patient outcome in north Indian population. *Surg Neurol Int* 2018; 9(1): 29.
 14. Weller M, Weber RG. Molecular classification of diffuse cerebral WHO grade II/III gliomas using genome-and transcriptome-wide profiling improves stratification of prognostically distinct groups. *Acta Neuropathol* 2015; 129(5): 679-693.
 15. Hu W-M, Wang F, Xi SY, Zhang X, Lai JP, Wu HY. Practice of the new integrated molecular diagnostics in gliomas: Experiences and new findings in a single Chinese center. *J Cancer* 2020; 11(6): 1371-1382.
 16. Ahsan J, Hashmi SN, Muhammad I, Din HU, Butt AH, Nazir S, et al. Spectrum of central nervous system tumours—a single center histopathological review of 761 cases over 5 years. *J Ayub Med Coll Abbottabad* 2015; 27(1): 81-84.
 17. Javed R, Akhtar N, Hassan U, Azam M, Asif Loya A, Hussain M, et al. IDH-1, ATRX and 1P19Q co-deletion in diffuse gliomas. *Pak Armed Forces Med J* 2020; 70(2): 571-577.
 18. Cai J, Zhu P, Zhang C, Wang Z, Li G. Detection of ATRX and IDH1-R132H immunohistochemistry in the progression of 211 paired gliomas. *Oncotarget* 2016; 7(13): 16384-1695.
-