

Effectiveness of Intralesional Triamcinolone Acetonide (TA) and Incision and Curettage (I & C) for Chalazia

Nazia Iqbal, Muhammad Haroon Sarfaraz*, Waqar Muzaffar, Hussnain Abbas**, Maryam Nisar, Amna Khan

Armed Forces Institute of Ophthalmology/National University of Medical Sciences (NUMS) Rawalpindi Pakistan, *POF Hospital/Wah Medical College, Wah/National University of Medical Sciences (NUMS) Rawalpindi Pakistan, **CMH Multan/National University of Medical Sciences (NUMS) Pakistan

ABSTRACT

Objective: To evaluate the efficacy of intralesional Triamcinolone Acetonide (TA) injection and incision and curettage (I&C) and their complications in chalazia.

Study Design: Quasi-experimental study.

Place and Duration of Study: Combined Military Hospital Multan Pakistan, from May to Nov 2019.

Methodology: We selected individuals with primary chalazion having a size of 2mm or more, with a duration of at least one month and not resolving with conservative treatment. Our sample was divided into two groups. Group-A was given a 5mg/ml Triamcinolone injection under aseptic conditions, and the group-B had incision and curettage.

Results: The overall frequency of lesion in the upper lid 53 (66%) was more than in the lower lid 27 (34%), $p=0.004$. The complete resolution of the lesions after the repetition of the procedure was found to be almost the same in the two groups. In comparison, the resolution duration was longer in group-A versus group-B. The complications were more in the surgical group 6 ($p=0.001$) than in the Triamcinolone Acetonide group 11, ($p=0.004$).

Conclusion: Our study signifies that intralesional Triamcinolone Acetonide injection is a safe procedure, having fewer complications. For individuals with poor compliance with conservative management, Triamcinolone Acetonide injections provide an alternative with an almost equal success rate and minimal complication.

Keywords: Chalazia, incision and curettage (I & C), Intralesional triamcinolone acetonide (TA).

How to Cite This Article: Iqbal N, Sarfaraz MH, Muzaffar W, Abbas H, Nisar M, Khan A. Effectiveness of Intralesional Triamcinolone Acetonide (TA) and Incision and Curettage (I & C) for Chalazia. *Pak Armed Forces Med J* 2022; 72(2): 431-434. DOI: <https://doi.org/10.51253/pafmj.v72i2.6541>

This is an Open Access article distributed under the terms of the Creative Commons Attribution License (<https://creativecommons.org/licenses/by-nc/4.0/>), which permits unrestricted use, distribution, and reproduction in any medium, provided the original work is properly cited.

INTRODUCTION

The eyes are an important organ involved in vision. They are shielded by eyelids that help protect the eyes from foreign bodies and play a role in maintaining the aqueous barrier over the cornea to prevent dryness. This aqueous barrier does not evaporate or spill over because there is an oily substance called "meibum," produced by sebaceous glands of the eyelids that keep the tears trapped between the lids and the eyeball. However, these glands (Meibomian and Zeis) are blocked due to secondary causes leading to a localized lipogranulomatous inflammation in the upper lid or the lower lid or sometimes both eyelids. Hence, they are often referred to as conjunctival granulomas. Several risk factors such as blepharitis, family history, environment, irritable bowel syndrome, vitamin A deficiency, constipation, smoking, viruses, and Demodex Brevis were found to be contributing to its recurrence.^{1,2,3} It is a frequent, benign and self-limiting condition seen in ophthalmology clinics, which causes cosmetic distress, but chronicity leads to complications

such as visual disturbance (visual axis disruption and astigmatism) due to pressure and weight. They may lead to infection and pain. Visual obstruction in larger or multiple lesions leads to annoyance in patients due to the pupillary axis being hindered by mechanical ptosis.^{4,5,6}

Although the first-line treatment of chalazion is conservative, including hot compresses (resolution rate up to 50%), antibiotic and steroid drops are included for infected cases. If they fail, intralesional steroid injects and incision and curettage are conducted.⁷

Patients often support conservative measures to avoid the pain and apprehensions of surgery. Triamcinolone injections are affordable, more effective in the resolution of chalazia than conservative treatments, and help avoid surgical scars and disfigurement.^{8,9} Singhania *et al*, also highlighted the TA injections' effectiveness for medium and large size chalazion, thus treating the cosmetic and visual disturbances without a surgical procedure.¹⁰ Hence the rationale was to identify a non-surgical treatment that could help resolve chalazia more effectively than surgical or conservative measures to increase patient compliance and comfort. Our study aimed to compare the efficacy of TA versus

Correspondence: Dr Nazia Iqbal, Department of Ophthalmology, Armed Forces Institute of Ophthalmology Rawalpindi Pakistan
Received: 06 Apr 2021; revision received: 01 Aug 2021; accepted: 05 Aug 2021

I & C and the frequency of complications in both the procedures to highlight the efficacy of this alternative procedure in place of surgery in chalazion patients.

METHODOLOGY

The quasi-experimental study was conducted from May to November 2019 at Combined Military Hospital, Multan. This study approved by the Institutional Ethics Committee and informed written consent was taken from all patients. Data was collected through convenience sampling. The sample size was determined through the WHO calculator as 80 patients, considering the significance level as 95% and effect size of 0.64 with a standard deviation of 1.0 and 80% power of the study.¹⁰

Inclusion Criteria: All the patients of either gender, aged more than 18 years with a diagnosis of a primary chalazion (2mm or more), duration of at least one month and not resolving with conservative treatment planned for either surgical intervention or Triamcinolone injection were included in the study..

Exclusion Criteria: Patients having multiple chalazia, recurrent chalazia, infected chalazia, Steroid responses, allergy to Xylocaine, or usage of anticoagulants or patients with acne rosacea were excluded from the study.

Detailed history and ophthalmic examination were conducted to rule out primary chalazion cases. All the patients considered for incision and drainage or TA injection had undergone a detailed pre-operative assessment, including the span of lid swelling and trial of conservative treatment, visual acuity (VA) assessment by Snellen VA chart with refraction, and intraocular pressure measured through Goldman applantation tonometry. Patients were divided into two groups. Group-A included all the patients for intralesional Triamcinolone injection, and group -B included all the patients undergoing incision and curettage. A total of 40 patients in each group were assigned through convenience sampling.

In group-A (TA group), Triamcinolone injection was diluted with 3ml of normal Saline to make 10 mg/ml and then mixed with 2% Lignocaine to give a final concentration of 5mg/ml. The injection was given using an insulin syringe, keeping the direction away from the globe under aseptic conditions. Both groups were given a cover of Tobramycin ointment postoperatively and analgesia for pain. The injection was repeated for non-resolved cases after two weeks in group-B and suggested surgical removal for persistence after four weeks.

In group-B (ST group), simple trans conjunctival curettage with a single vertical incision was performed after injecting 2% Lignocaine with Adrenaline. The material was curetted, and the base was washed with normal Saline. The eye was padded for four hours with antibiotic ointment. If recurrence occurred or no resolution took place, the repetition of surgery was conducted after four weeks.

Patients were followed up for two weeks to see the resolution of the lesion. If not, a second trial was given and observed after a further wait of two weeks. Size of each chalazion, recurrence, IOP, pigmentary changes, hematoma formation, and granuloma formation was noted to compare the effectiveness of the two procedures. The success rate was determined by measuring the chalazia size, resolution of 80%, or complete resolution of the lesion.

Statistical Package for Social Sciences (SPSS) version 26 was used for the data analysis. Quantitative variables were summarized as mean \pm SD and qualitative variables were summarized as frequency and percentages. Chi-square test was applied to find out the association. Independent sample t-test was applied to find the mean differences among the groups. The *p*-value of ≤ 0.05 was considered statistically significant.

RESULTS

A total of 80 patients were enrolled in this study. All the patients were followed up during the study; hence there was no fall-out or failure to follow up. In group-A (TA-group), the number of male patients was 12 (30%), while females were 28 (70%), with the mean age of 37.7 ± 14 years. In group-B (ST-group), the number of male patients was 13 (32.5%), while females were 27 (67.5%), with the mean age of 35.8 ± 14 years.

The overall frequency of lesion in the upper lid 53 (66%) was more than in the lower lid 27 (34%), *p*=0.004 in the total study sample. In group-A, the upper lid chalazia 27 (68%) was more than the lower lid 13 (32%). Likewise, in group-B, the upper lid chalazia 32 (80%) was more than the lower lid 8 (20%).

The mean size of the chalazia in group-A was 4.62 ± 1.5 mm and in group- B was 4.75 ± 1.8 mm with the *p*-value of 0.273 (Table-I).

After two weeks of follow-up, the complete resolution of the lesions was found to be slightly more in group-B than in group-A (Table-II). In contrast, the success of the resolution of the unresolved lesions after

the repetition of the second dose was found to be almost equal (Table-III).

Table-I: Mean resolution period of chalazia with triamcinolone versus incision & curettage.

| | Group A (TA Group) | Group B (ST Group) | p-value |
|--------------------------------|--------------------|--------------------|---------|
| Mean Resolution Period (weeks) | Mean = 2.2 ± 1.7 | Mean = 1.2 ± 0.9 | <0.001 |

Table-II: Frequency of resolution of lesions two weeks after intervention.

| | Group A | Group B | p-value |
|--|----------------------|---------------------|---------|
| Resolution Frequency After Two Weeks (n) | 28 (70%) 12 (30%) | 31 (78%) 9 (22%) | 0.446 |

Table-III: Frequency of non-resolved chalaza.

| | Group A | Group B | p-value |
|--|---------|---------|---------|
| Failure to Resolve after Repetition of Treatment (n) | 4 (33%) | 2 (22%) | 0.369 |

Repetition of the procedure was done in 12 patients in group-A and nine patients in group-B. Out of which four patients of group-A while two patients of group-B did not show any improvement.

Out of the six patients who showed complications in the TA-group, skin depigmentation was found in 5 (83%) patients, while one (17%) showed sub conjunctival haemorrhage.

In the ST-group, out of the 11 patients, subconjunctival haemorrhage was seen in six patients (55%), three patients (27%) developed granuloma, and two had slight lid notching (18%).

The success of procedures was measured by the resolution time and the need for repetition of the procedure along with 80% resolution of the lesion or complete resolution (Figure-1).

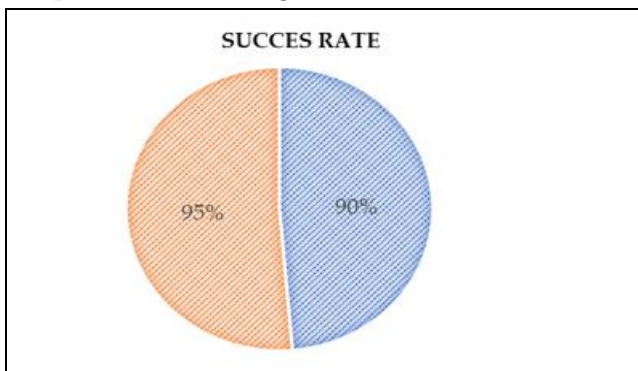


Figure-1: Success rate of the Triamcinolone injection versus Incision and drainage in the two groups.

Success rate of both the procedures was found to be more or less the same with a p-value of 0.369. The complications were found to be more or less same with

slightly more in the surgical group 6 (15%) than in the TA-group 11 (28%) ($p=0.1.72$) as shown in the Figure-2.

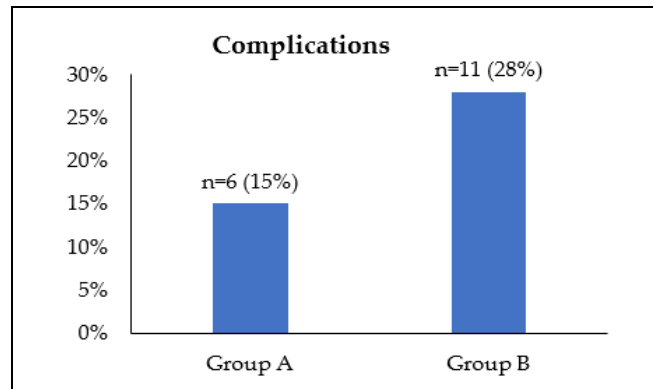


Figure-2: Over all Complications among Triamcinolone injection group and Surgical intervention group.

DISCUSSION

Our study highlighted that in tralesional TA injection is a safe procedure that saves the patients from surgical procedure anxiety. Although conservative management is the first-line treatment, in patients with non-resolving chalazia and those with poor compliance to conservative management, TA injections provide an alternative with an almost equal success rate and fewer complications than the surgical approach.

In our study, more females (67%) were found to be affected than males, consistent with the findings of Bhattarai *et al*. The mean age affected in our study was 35-37 years, having a likely cause of more sebum production due to hormonal changes. The lesions were more dominant in the upper lid than the lower lid, the possible cause explained by Bhattarai *et al*, is the anatomical location of the glands in the upper lid predisposing to more retention of sebum due to secondary causes.¹¹

The overall effectiveness of both procedures was almost equal, with a success rate of 90% and 95% in group-A and group-B, respectively, supported by the results of Tahir *et al*,¹² who highlighted the effectiveness of intralesional Triamcinolone injection for chalazia having size 2mm to 11mm and being more effective in less than 6mm lesions. Consistent with our findings of an approximate size of 4.5 to 4.7mm. Another study highlighted the equal effectiveness of both procedures in the resolution of the chalazia while still emphasizing the higher success rate of incision and curettage.¹³

In another research conducted by Aycinena *et al*,¹⁴ the effectiveness of I&C as superior in resolving the

lesion in one procedure, is consistent with our results of the two weeks resolution rate of group-B being slightly higher than group-A. Further highlighting facts like our results, the procedure repetition leads to almost comparable results in both the procedures. The resolution time in our study was found to be more for the TA-group than the ST-group, consistent with the results of other research in the literature. More likely, due to the complete removal of the lesion after I&C, which helps in early recovery.¹⁰ Contrary to our results, a study highlighted that among the three methods of treatment of chalazion, TA injection, I&C, and a combination of both, TA injection is the most rapid and most effective treatment methodology.¹⁵

TA injections have the least complications that have been highlighted in the literature.¹⁶ Even though I&C is more reliable regarding success rate, intralesional Steroid injection has the benefits of not requiring additional anaesthetic injection and having prolonged anti-inflammatory effects, does not cause bleeding and scarring, can be easily performed in the clinic setting, is helpful for multiple chalazia. Potential complications highlighted in literature for intralesional TA injections include discolouration at the injection site, consistent with our study results. Elevated IOP, globe perforation, and traumatic cataracts may happen in TA injection,^{17,18} but our patients did not show any rise in IOP post-treatment.

CONCLUSION

Our study signifies that in tralesional Triamcinolone Acetonide injection is a safe procedure, having fewer complications. For individuals with poor compliance with conservative management, Triamcinolone Acetonide injections provide an alternative with an almost equal success rate and minimal complication.

Conflict of Interest: None.

Authors' Contribution

NI: Conception, data collection and analysis, MHS: Statistical analysis and interpretation, WM: Research supervision and approval, HA: Conception and research analysis, MN: Data collection and manuscript drafting, AK: Data collection and manuscript drafting.

REFERENCES

1. Fukuoka S, Arita R, Shirakawa R. Changes in meibomian gland morphology and ocular higher-order aberrations in eyes with chalazion. *Clin Ophthalmol* 2017; 11(1): 1031-1038.

2. Evans J, Vo KBH, Schmitt M. Chalazion: racial risk factors for formation, recurrence, and surgical intervention. *Can J Ophthalmol* 2021; S0008-4182(21): 167-168.
3. Malekhamdi M, Farrahi F, Tajdini A. Serum Vitamin A Levels in Patients with Chalazion. *Med Hypothesis Discov Innov Ophthalmol* 2017; 6(3): 63-66.
4. Jordan GA, Beier K. Chalazion. 2020. In: *Stat Pearls*. Treasure Island (FL): StatPearls Publishing; 2021. [Internet] Available at: <https://www.ncbi.nlm.nih.gov/books/NBK499889/>
5. Das AV, Dave TV. Demography and clinical features of chalazion among patients seen at a multi-tier eye care network in India: An Electronic Medical Records Driven Big Data Analysis Report. *Clin Ophthalmol* 2020; 14(1): 2163-2168.
6. Wu AY, Gervasio KA, Gergoudis KN, Wei C, Oestreicher JH, Harvey JT. Conservative therapy for chalazia: is it really effective? *Acta Ophthalmol* 2018; 96(4): 503-509.
7. LoBue SA, Giovane RA, Bahl N, Schaefer E, LoBue TD. A simple anesthetic technique to eliminate pain and optimize patient satisfaction for chalazion incision and curettage. *Adv Ophthalmol Vis Syst* 2017; 7(7): 471-474.
8. Das N, Nasir AS. Comparison of Intralesional Kenacort Injection Versus Surgical Intervention for Primary Chalazion. *Pak J Ophthalmol* 2019; 35(3): 179-183.
9. Brundavanam S, Deepthi R, Kumar A. Treatment of chalazia by incision and curettage versus intralesional triamcinolone acetonide injection. *Int J Ocul Oncol Oculoplasty* 2019; 5(3): 133-135.
10. Singhania R, Sharma N, Vashisht S, Dewan T. Intralesional Triamcinolone Acetonide (TA) Versus Incision and Curettage (I & C) for Medium and Large Size Chalazia. *Nepal J Ophthalmol* 2018; 10(19): 3-10.
11. Bhattarai B, Shrestha K, Patel S, Manandhar LD, Karki R, Gurung N. Treatment of chalazion: a comparative cross-sectional study. *Europasian J Med Sci* 2019; 1(1): 5-9.
12. Tahir MZ, Rehman M, Ahmad I, Iqbal A, Hussain I. Effectiveness of Intralesional Triamcinolone Acetonide in the treatment of chalazion. *Pak J Ophthalmol* 2015; 31(1): 9-14.
13. Nabie R, Soleimani H, Nikniaz L, Raoufi S, Hassanpour E, Mamaghani S, et al. A prospective randomized study comparing incision and curettage with injection of triamcinolone acetonide for chronic chalazia. *J Curr Ophthalmol* 2019; 31(3): 323-326.
14. Aycinena AR, Achiron A, Paul M, Burgansky-Eliash Z. Incision and curettage versus steroid injection for the treatment of chalazia: a meta-analysis. *Ophthalmic Plast Reconstr Surg* 2016; 32(3): 220-224.
15. Khan TH, Zafar S. Efficacy of intralesional triamcinolone acetonide for the treatment of chalazion. *Pak J Ophthalmol* 2017; 33(1): 46-50.
16. Wolkow N, Jakobiec FA, Hatton MP. A Common procedure with an uncommon pathology: triamcinolone acetonide eyelid injection. *Ophthalmic Plast Reconstr Surg* 2018; 34(3): 72-73.
17. Lee JW, Yau GS, Wong MY, Yuen CY. A comparison of intralesional triamcinolone acetonide injection for primary chalazion in children and adults. *Sci World J* 2014; 2014: 413729. doi: 10.1155/2014/413729.
18. Wong MY, Yau GS, Lee JW, Yuen CY. Intralesional triamcinolone acetonide injection for the treatment of primary chalazions. *Int Ophthalmol* 2014; 34(5): 1049-1053.