

Analysis of C- Shaped Root Canal Morphology in Mandibular Second Molar using Cone Beam Computed Tomography

Marina Shah, Shahbaz Ahmed Jat, Fazal ur Rehman Qazi, Hira Akhtar, Prena Moorpani, Munazza Aziz

Department of Operative Dentistry, Dr Ishrat ul Ebad Khan Institute of Oral Health Sciences/Dow University of Health Sciences, Karachi Pakistan

ABSTRACT

Objective: To analyse the C-shaped canal configuration in the mandibular second molar in a Pakistani subpopulation using cone beam computed tomography (CBCT).

Study Design: Cross-sectional study.

Place and Duration of Study: Department of Radiology, Dow University of Health Sciences, Karachi Pakistan, from Feb to Jul 2020.

Methodology: Cone-beam computed tomography (CBCT) scans of the mandibular second molar that were taken for some other purpose were included in the study. One hundred fifty mandibular second molar teeth were assessed for C-shaped canal morphology. The c-shaped canal was then further examined at three different levels classifying according to Fan criteria, a modification of Melton's classification. Differences between gender left and right sides, unilateral and bilateral, were determined.

Results: Out of 150 mandibular second molars, a C-shaped canal was found in 13(8.7%) of the teeth examined, in which 9(69.2%) were in females, and 4(30.8%) were in males. Bilateral distribution was found to be 11(92.3%).

Conclusion: A high frequency of C-shaped canal in the mandibular second molars was observed in the present study. Therefore the variations in the morphology of the root canal system of the mandibular second molars should be considered when performing root canal treatment.

Keywords: Cone beam computed tomography (CBCT), C-shaped root canal morphology, Karachi pakistan subpopulation, Mandibular second molar.

How to Cite This Article: Shah M, Jat SA, Qazi FUR, Akhtar H, Moorpani P, Aziz M. Analysis of C- Shaped Root Canal Morphology in Mandibular Second Molar using Cone Beam Computed Tomography. Pak Armed Forces Med J 2023; 73(4): 1149-1152. DOI: <https://doi.org/10.51253/pafmj.v73i4.6390>

This is an Open Access article distributed under the terms of the Creative Commons Attribution License (<https://creativecommons.org/licenses/by-nc/4.0/>), which permits unrestricted use, distribution, and reproduction in any medium, provided the original work is properly cited.

INTRODUCTION

C-shaped canal system was observed in multiple teeth, such as mandibular premolars and mandibular third molars. It was also found in maxillary first molars.¹ However, its highest incidence was associated with mandibular second molars.^{2,3} This distinctive anatomy has great significance as it is extremely difficult to manage such variation when it comes to cleaning and shaping procedures. The debridement of teeth with C-shaped canal morphology is the biggest challenge for a clinician because of its complexity and variation throughout the root length.⁴ Higher prevalence was found to be in the Asian population when it was compared with other regions of the world. The ethnic influence was observed on the prevalence of C-type canal configurations, as reported by a few authors.⁵

Cone beam computed tomography (CBCT) is a very useful diagnostic aid. It is particularly for imaging the facial region, indicating a shift from a two-dimensional (2D) image to a three-dimensional (3D)

image. It has been widely used in endodontics in recent years.^{6,7} It is a non-invasive technique, and it permits the reconstruction of images. It reconstructs images in all three planes, namely, axial, coronal and sagittal. Three-dimensional radiographic techniques are more accurate and reliable in assessing root canal morphology.^{8,9} It eliminates the superimposition problem, a major drawback encountered in two-dimensional radiographic images.

Limited scientific literature was available for C-shaped canal morphology using CBCT of mandibular second molar teeth in Karachi. Few kinds of literature are presently related to the previous diagnostic techniques, i.e. two-dimensional radiography, use of stereomicroscope, staining etc. Therefore, the rationale of the current research was to illustrate the C-shaped root canal morphology of the mandibular second molar in the subpopulation of Karachi, Pakistan using CBCT.

METHODOLOGY

The cross-sectional study was conducted at the Department of Radiology, Dow University of Health Sciences, Karachi Pakistan, from February to July 2020, after obtaining ethical approval from Institutional

Correspondence: Dr Marina Shah, Operative Dentistry, Dr Ishrat ul Ebad Khan Institute of Oral Health Sciences/DUHS, Karachi Pakistan
Received: 26 Feb 2021; revision received: 23 Feb 2022; accepted: 25 Feb 2022

Review Board (IRB-1139/DUHS/Approval/2018/188). The sample size was calculated using PASS version 11, taking the prevalence of 1.2% C-shaped root canal configuration using CBCT as reference.¹⁰

Inclusion Criteria: Patients who got their CBCT scans done for diagnostic purposes, mainly for surgical procedures such as implant placement or to determine the location of the impacted third molar having a sound mandibular second molar, were included in the study.

Exclusion Criteria: Unclear canal morphology of the lower second molar due to pathologic lesion was excluded from the study.

The CBCT scans were collected and observed in the Department of Radiology of three Dental Institutes of Dow University of Health Sciences (DUHS), namely, Dr Ishrat ul Ebad Khan Institute of Oral Health Sciences, Dow Dental College and Dow International Dental College. The selected CBCT scans were imaged by a CBCT device (Care Stream 9300) with exposure parameters of 90kV and 4mA. The 10×10 cm field of view (FOV), a voxel size 1mm with the duration of exposure of 08 seconds. The volumetric data set was converted into study images via CS 3D imaging software; each sample image was viewed on all three planes, i.e. sagittal, coronal and axial.

All mandibular second molar teeth were observed to assess the number of roots and root canals and the presence of a C-shaped root canal configuration. Teeth that showed a C-type canal system were further observed at three levels on an axial plane. The three levels were coronal, middle and apical. The coronal level was 2mm below the root canal orifice. The middle level was the mid-distance from the canal orifice, and the anatomic apex and apical were taken 2mm above the anatomic apex.

At three levels, the canal shape was classified according to Melton's classification, which was initially proposed by Fan *et al.*¹¹ C1: Continuous uninterrupted "C" with no separation, C2: Semicolon. However, either the α or the β angle should be not $<60^\circ$, C3: 2 or 3 separate canals with both angles α and $\beta < 60^\circ$, C4: 1 round / oval canal, C5: No canal lumen (Figure-1).

The data was collected by observing mandibular second molar teeth in sagittal, coronal and axial planes. Several roots and a number of canals were counted. Mandibular second molar teeth with fused roots or single roots were checked for the presence or absence of a C-shaped canal system. Mandibular second molar teeth with a C-shaped canal system were further studied at three levels of an axial plane that were

coronal, middle & apical. Canal shapes at these levels were observed and classified according to Fan criteria.

C1		The shape is an uninterrupted "C" with no separation or division
C2		The canal shape resembles a semicolon resulting from a discontinuation of the "C" outline, but either angle α or β should be no less than 60°
C3		Two or three separate canals and both angles, α or β are less than 60°
C4		Only one round or oval canal in that cross-section
C5		No canal lumen can be observed (which is usually seen near the apex only)

Figure-1: Fan *et al.* Anatomic Classification of C-shaped Canal Configuration

Data was analysed using Statistical Package for the Social Sciences (SPSS) version 23.00 and MS Excel 2016 software. Frequency and percentages were calculated for categorical variables. The Chi-square test was used to observe the presence of a C-shaped canal in accordance with gender. The p -value ≤ 0.05 was considered significant.

RESULTS

Out of 150 teeth, a C-shaped root canal configuration was found in 13(8.7%). 9(69.2%) were in females, and 4(30.8%) were in males. No significant difference was found in the distribution of the C-shaped canal with respect to gender ($p=0.079$) (Table). Bilateral distribution in the same arch was observed in 11(92.3%) teeth. Most teeth were classified as C1 at the coronal level, whereas C2 at the middle and apical level, as shown in Figure-2.

Table: Analysis of Root Canals and C-shaped Canal type in Mandibular 2nd Molar with respect to Gender (n=150)

Number and canal type	Male	Female	Total	p -value
C-shaped	4(2.7%)	9(6.0%)	13(8.7%)	0.079
1	4(2.7%)	0(0%)	4(2.7%)	0.105
2	0(0%)	1(0.7%)	1(0.7%)	
3	56(37.3%)	47(31.3%)	103(68.7%)	
4	17(11.3%)	12(8.0%)	29(19.3%)	

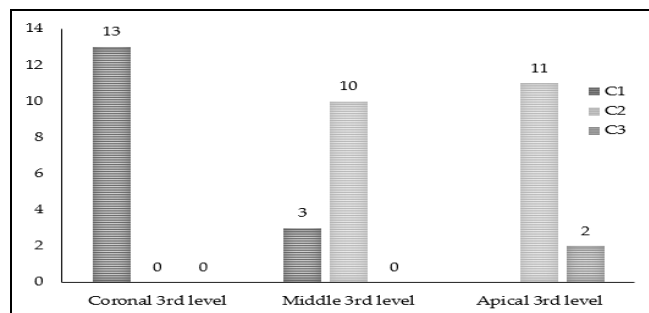


Figure-2: C-shaped Canal Classified according to Fan *et al.* at three Different Root Levels

DISCUSSION

A detailed knowledge of the anatomy of a root canal is very important for a dentist to understand the complexity and variations in the root canal systems. C-shaped root canal morphology is mostly observed in mandibular second molar teeth.¹²

In relation to shape, the entire length of the C-shaped root canal system exhibits changes, as observed by Fan *et al.*¹¹ The morphology seen at the orifice level may differ at the mid-root or apical level. Different techniques were used for this purpose, for instance, sectioning the root of an extracted root at different levels and injection of a dye after cleaning the canal space. In this study, it was viewed under CBCT, which is an effective and non-invasive technique. It provides volumetric data that can be viewed in different planes and levels. Therefore, in this study, the root canal was evaluated in an axial plane at three different root levels that were coronal, mid-level and apical level using CBCT on non-extracted teeth.

It is observed from the literature that the presence of a C-shaped canal configuration is an ethnic variation.¹³⁻¹⁵ Its prevalence ranges from 2.7% to 8.1% in Americans,¹⁶ and up to 44.5% among the Asian population. It was found to be 9.1% in the Saudi Arabia study,¹⁷ 13.2% in the Indian population,¹⁸ 1% in the Lebanese study,¹⁹ 22.4% was found in the Burmese study,¹⁹ and 29% to 41% were found in the Chinese population. The highest was up to 48.7% among the Malaysian population.²⁰ According to the present study, the prevalence of C type of canal system was 8.7% in the sample of Karachi subpopulation. This result was similar to the findings of previous studies that were done around the globe.¹¹

Previous studies showed that the prevalence of C-shaped canal was associated with ethnicity. The lack of evaluation of the occurrence and variations of C-type canal morphology in other regions of Karachi, Pakistan, is one of the limitations of this study. This data indicates that it is essential for an endodontist to consider the likelihood of C type canal system on the contralateral mandibular second molar, also if it is found on one side.

C-shaped canal has multiple variations along the entire length of the root.¹³ The canal shape at the orifice level may not remain the same at the mid-root level and may vary at the apical level. The cleaning of such variations at different levels is challenging for an endodontist. In this study, the C1 type was the most frequent in the coronal third, similar to the previous

study,¹⁰ whereas type C2 was mostly observed at the mid-level and apical levels. Therefore, the analysis of C-type canal systems at different root levels helps the clinician pre-plan the procedure accordingly.

The discrepancies and variations in these results could be due to differences in the sample size and subjects. More data, including different ethnic groups and a larger sample size, may explain these variations better.

CONCLUSION

A reflective knowledge of intricate root canal anatomy leads to a successful endodontic treatment. According to the present study, a higher prevalence of C-type root canal configuration was observed in the Pakistani subpopulations. Variations in the entire length of the root of the C-type canal and its bilateral distribution should be considered while performing root canal treatment.

Conflict of Interest: None.

Author's Contribution

Following authors have made substantial contributions to the manuscript as under:

MS & SAJ: Data acquisition, data analysis, critical review, approval of the final version to be published.

FURQ & HA: Study design, drafting the manuscript, data interpretation, approval of the final version to be published.

PM & MA: Concept, data acquisition, drafting the manuscript, approval of the final version to be published.

Authors agree to be accountable for all aspects of the work in ensuring that questions related to the accuracy or integrity of any part of the work are appropriately investigated and resolved.

REFERENCES

- Kalaitzoglou ME, Kantilieraki E, Beltes C, Angelopoulos C, Beltes P. second root canal in mandibular incisors: An ex vivo cone-beam computed tomography (CBCT) study. *Balk J Dent Med* 2018; 22(1): 38. <http://dx.doi.org/10.2478/bjdm-2018-0007>
- Martins JN, Mata A, Marques D, Caramês J. Prevalence of C-shaped mandibular molars in the portuguese population evaluated by cone-beam computed tomography. *Eur J Dent* 2016; 10(04): 529-535. <https://doi.org/10.4103/1305-7456.195175>
- von Zuben M, Martins JN, Berti L, Cassim I, Flynn D, Gonzalez JA, et al. Worldwide prevalence of mandibular second molar C-shaped morphologies evaluated by cone-beam computed tomography. *J Endod* 2017; 43(9): 1442-1447. <https://doi.org/10.1016/j.joen.2017.04.016>
- Tassoker M, Sener S. Analysis of the root canal configuration and C-shaped canal frequency of mandibular second molars: a cone beam computed tomography study. *Folia Morphol (Prava)* 2018; 77(4): 752-757. <https://doi.org/10.5603/fm.a2018.0040>
- Hargreaves KM, Cohen S, Berman LH, Cohen's path-ways of the pulp. 12th Edition. Elsevier, St. Louis, Missouri; 2021, [Internet] available at: https://amu.edu.az/storage/files/22/D_%C9%99rslk1%C9%99r/Cohen's%20Pathways%20of%20the%20Pulp.pdf

Analysis of C- Shaped Root Canal Morphology

6. Celikten B, Tufenkci P, Aksoy U, Kalender A, Kermeoglu F, Dabaj P, et al. Cone beam CT evaluation of mandibular molar root canal morphology in a Turkish Cypriot population. *Clin Oral Invest* 2016; 20(8): 2221-2226. <https://doi.org/10.1007/s00784-016-1742-2>
7. Fayad MI, Nair M, Levin MD, Benavides E, Rubinstein RA, Barghan S, et al. AAE and AAOMR joint position statement: use of cone beam computed tomography in endodontics 2015 update. *Oral Surg Oral Med Oral Pathol Oral Radiol* 2015; 120(4): 508-512.
8. Sherwood IA, Gutmann JL, Kumar S, Evangelin J, Nivedha V, Sadashivam V, et al. CBCT analysis of the anatomy of C-shaped root canals in mandibular second molars from a southern Indian population in Tamil Nadu. *Endod Prac* 2019; 13(1): 61-70.
9. Donyavi Z, Shokri A, Khoshbin E, Khalili M, Faradmal J. Assessment of root canal morphology of maxillary and mandibular second molars in the Iranian population using CBCT. *Dent Med Probl* 2019; 56(1): 45. <https://doi.org/10.17219/dmp/101783>
10. Janani M, Rahimi S, Jafari F, Johari M, Nikniaz S, Ghasemi N, et al. Anatomic features of c-shaped mandibular second molars in a selected Iranian population using CBCT. *Iran Endod J* 2018; 13(1): 120. <https://doi.org/10.22037/iej.v13i1.17286>
11. Fan W, Fan B, Gutmann JL, Fan M. Identification of a C-shaped canal system in mandibular second molars –Part III: Anatomic features revealed by digital subtraction radiography. *J Endod* 2008; 34(10): 1187-1190. <https://doi.org/10.1016/j.joen.2008.06.010.32265463>
12. Kim H-S, Jung D, Lee H, Han Y-S, Oh S, Sim H-Y, et al. C-shaped root canals of mandibular second molars in a Korean population: a CBCT analysis. *Restor Dent Endod* 2018; 43(4): 12-15. <https://doi.org/10.5395/rde.2018.43.e42>
13. Fan B, Cheung GS, Fan M, Gutmann JL, Bian Z. C-shaped canal system in mandibular second molars: part I –anatomical features. *J Endod* 2004; 30(12): 899-903. <https://doi.org/10.1097/01.don.0000136207.12204.e4>
14. Wadhvani S, Singh MP, Agarwal M, Somasundaram P, Rawtiya M, Wadhvani P, et al. Prevalence of C-shaped canals in mandibular second and third molars in a central India population: A cone beam computed tomography analysis. *J Conserv Dent* 2017; 20(5): 351. https://doi.org/10.4103/jcd.jcd_273_16
15. Martins JN, Gu Y, Marques D, Caramês J. Differences on the root and root canal morphologies between Asian and white ethnic groups analyzed by cone-beam computed tomography. *J Endod* 2018; 44(7): 1096-1104. <https://doi.org/10.1016/j.joen.2018.04.010>
16. Ladeira DBS, Cruz AD, Freitas DQ, Almeida SM. Prevalence of C-shaped root canal in a Brazilian subpopulation: a cone-beam computed tomography analysis. *Braz Oral Res* 2014; 28(1): 39-45. <https://doi.org/10.1590/s1806-83242013005000027>
17. Al-Fouzan K. C-shaped root canals in mandibular second molars in a Saudi Arabian population. *Int Endod J* 2002; 35(6): 499-504.
18. Pawar AM, Pawar M, Kfir A, Singh S, Salve P, Thakur B, et al. Root canal morphology and variations in mandibular second molar teeth of an Indian population: an in vivo cone-beam computed tomography analysis. *Clin Oral Invest* 2017; 21(9): 2801-2809. <https://doi.org/10.1007/s00784-017-2082-6>
19. Gulabivala K, Aung T, Alavi A, Ng YL. Root and canal morphology of Burmese mandibular molars. *Int Endod J* 2001; 34(5): 359-370. <https://doi.org/10.1046/j.1365-2591.2001.00399.x>
20. Pan JYY, Parolia A, Chuah SR, Bhatia S, Mutalik S, Pau A. Root canal morphology of permanent teeth in a Malaysian subpopulation using cone-beam computed tomography. *BMC Oral Health* 2019; 19(1): 14. <https://doi.org/10.1186/s12903-019-0710-z>