

**Renal Hydatid Cyst Mimicking Renal Cell Carcinoma; A Case Report**

Bilal Habib, Khurshheed Anwar, Mohammad Roman, Irfan Ullah Khan, Saeed Iqbal

PAEC General Hospital, Islamabad Pakistan

**ABSTRACT**

Renal hydatid cyst is a rare entity as compared to hepatic hydatid cyst. However, literature manifests case reports of renal hydatid cysts. The establishment of diagnosis becomes difficult in non-endemic areas. The tumour is well-considered on clinical examination and radiological investigations for this condition. We presented a case of renal hydatid cyst in a 45-years-old male patient who presented with hematuria and was labelled as renal cell carcinoma clinically and radiologically. However, histopathology confirmed the diagnosis of renal hydatid cyst.

**Keywords:** Hydatid disease, Renal cell carcinoma, Renal hydatid cyst.

**How to Cite This Article:** Habib B, Anwar K, Roman M, Khan IU, Iqbal S. Renal Hydatid Cyst Mimicking Renal Cell Carcinoma; A Case Report. Pak Armed Forces Med J 2022; 72(2): 723-724. DOI: <https://doi.org/10.51253/pafmj.v72i2.6259>

This is an Open Access article distributed under the terms of the Creative Commons Attribution License (<https://creativecommons.org/licenses/by-nc/4.0/>), which permits unrestricted use, distribution, and reproduction in any medium, provided the original work is properly cited.

**INTRODUCTION**

Humans are less infected by the Echinococcus granulosus parasite as an intermediate host.<sup>1</sup> Lung and liver are the most typical sites of disease. However, it can affect any organ of the human body.<sup>2,3</sup> Kidney is one of the rare sites for this disease. Incidence varies from 2-5%.<sup>4,5</sup> It is difficult to establish an accurate pre-operative diagnosis of renal hydatid cyst even in the endemic areas while the radiological evidence may misinterpret as renal malignancy. Although serological studies may help in the diagnosis, however histopathology gives confirmatory diagnosis. Herein, we present our experience of treating a case of renal hydatid cyst, which was misdiagnosed as renal malignancy.

**CASE REPORT**

In 2012, a 45 years old male patient presented at PAEC Hospital with dull and slow onset left flank pain over the two months associated with on and off vomiting and hematuria. However, he developed a high-grade fever for the last few days. His history was significant for uncontrolled hypertension. He had leukocytosis and urinary pus cell in the laboratory on urine complete examination. Initial ultrasonography showed a large cystic mass in the left kidney. The sequential CT scan showed a complex cystic enhancing exophytic mass measuring 11x13x11 cm (Figure-1) along the interpolar region and lower pole of the left kidney, raising strong suspicion of renal cell carcinoma. An initial diagnosis was made of the renal tumour, and surgical treatment was planned. However, the patient left against medical advice and refused

surgery.

In 2020, the patient again presented with hematuria and deranged renal functions (serum creatinine: 1.62 mg/dl). Ultrasound abdomen showed a large well defined heterogeneous mass (predominantly solid) rising from the antero-medial part of the left kidney (13.4 x 12.4 x 10.9 cm) (Figure-2).

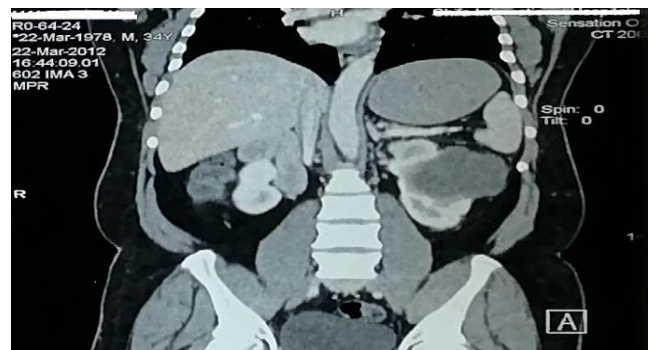


Figure-1: Abdominal computed tomography coronal view.

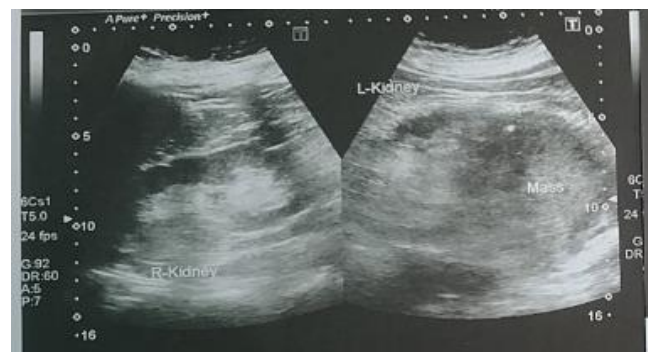

Figure-2: Ultrasonography of left kidney.

CT scan was not performed due to raised serum creatinine. Considering the high suspicion of renal cell carcinoma in the previous CT scan report, a left radical

**Correspondence:** Dr Bilal Habib, Department of Urology, PAEC General Hospital, Islamabad Pakistan

Received: 06 Feb 2021; revision received: 05 May 2021; accepted: 19 Jul 2021

nephrectomy was performed. Per-operatively, a large cystic mass along with 3 litres of brownish fluid was noted (Figure-3). Postoperatively, histopathology labelled that renal mass as a hydatid cyst.

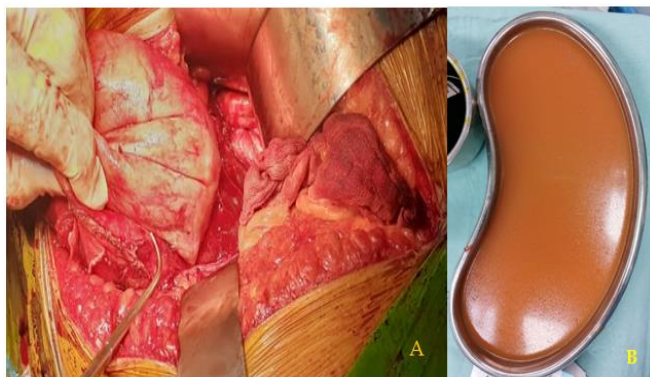


Figure-3: (A) Left renal cyst, (B) Aspirated Brownish fluid of cyst.

### DISCUSSION

Renal cysts are linked to benign and malignant renal pathologies. Renal hydatid cyst is a benign pathology. However, variations in its clinical and radiological presentations make it challenging to demarcate from renal malignancies.

Similar to our case, Sidani *et al*,<sup>5</sup> and Singh *et al*,<sup>2</sup> reported cases of renal hydatid cyst in the middle-aged men. However, Choi *et al*,<sup>6</sup> and Bhaya *et al*,<sup>7</sup> reported renal hydatid cyst in older females. Chronic flank pain with urine colour changes was the most typical presentation in all the cases.<sup>2,5-7</sup> Radiological imaging in all the cases misled the diagnosis by tagging it renal malignancy that came out to be hydatid cyst on histopathological examination.<sup>2,5-7</sup> The classical CT findings for renal hydatid disease, including a cyst with the calcified wall, a detached membrane in a unilocular cyst, a multi-loculated cyst with daughter cysts, could not be recognized on initial CT scan reporting. Another diagnosis could have been hydraturia (present in 10-20% cases) which was not observed in our patient.<sup>8</sup> Another diagnostic challenge was the isolation of the disease. In our case, it only involved the left kidney while sparing the other organs. A clue negating the malignancy was the chronicity of the problem. The patient presented again after eight years of an untreated malignant condition. For a malignant condition, it was surprising to remain sited at the primary organ without having a distant spread. Unusually, Maghbool *et al*,<sup>4</sup> reported a renal hydatid cyst co-existed with renal cell carcinoma in 47 years old Iranian male on

histo-pathological examination. Histopathology is still the gold standard for the diagnosis. Various serological tests have been devised, including the Casoni test, the Weinberg test, and more recent Echinococcus IgG ELISA (for antibody detection), which may aid in diagnosis in many cases. However, these were not utilized in our case due to not suspecting the hydatid cyst on CT scan findings.<sup>9</sup>

Our decision of performing a nephrectomy was favourable for the patient keeping in mind the poor renal functioning. Later on, the patient did well on routine oral Albendazole (at a dose of 10-15 mg/kg/day in two divided doses) for 28 days.

An isolated hydatid cyst of the kidney is infrequent and can be easily misdiagnosed as a renal tumour. Hence, hydatid cyst should always be included in the differential diagnosis of a cystic renal mass in endemic areas to manage the treatment safely and with less mortality and morbidity.

**Conflict of Interest:** None.

### Authors' Contribution

BH: Conception of Work data collection, discussion, KA: Final approval, MR: Literature search, IK: Introduction, SI: Data Interpretation.

### REFERENCES

- Zmerli S, Ayed M, Horchani A, Chami I, El Ouakdi M, Ben Slama MR. Hydatid cyst of the kidney: diagnosis and treatment. *World J Surg* 2001; 25(1): 68-74.
- Singh V, Devana SK, Gorski U, Bal A. Isolated Renal Hydatid Cyst Masquerading as Cystic Renal Tumor *Urol* 2019; 133(11): 11-12.
- Gadelkareem RA, Elqady AA, Abd-Elshafy SK, Imam H, Abolella HA. Isolated renal hydatid cyst misdiagnosed and operated as a cystic renal tumor. *Med Princ Pract* 2018; 27(3): 297-300.
- Maghbool M, Alivand A, Zolmajdi N, Kharmandar A. Co-existence of renal hydatid cyst and renal cell carcinoma in one kidney: A case report. *Asian Pac J Trop Dis* 2020; 13(2): 91-93.
- Sidani MN, Graziano CE, Soni SD, Smith TG. Renal Hydatid Cyst Mimicking Renal Cell Carcinoma. *Austin J Urol* 2015; 2(3): 1028.
- Choi H, Park JY, Kim JH, Moon DG, Lee JG, Bae JH. Primary renal hydatid cyst: mis-interpretation as a renal malignancy. *Korean J Parasitol* 2014; 52(3): 295-298
- Bhaya A, Shinde AP. Isolated renal hydatid presenting as a complex renal lesion followed by spontaneous hydraturia. *World J Radiol* 2015; 7(7): 180-183.
- Mongha R, Narayan S, Kundu AK. Primary hydatid cyst of kidney and ureter with gross hydraturia: A case report and evaluation of radiological features. *Ind J Urol* 2008; 24(1): 116-117.
- Razzaghi MR, Mazloomfard MM, Bahrami-Motlagh H, Javanmard B. Isolated renal hydatid cyst: diagnosis and management. *Urol J* 2012; 9(4): 718-720.