

CASE REPORTS

MALAKOPLAKIA OF APPENDIX: A CASE REPORT

Syed Salman Ali, Rabia Ahmed, Shoaib Naiyar Hashmi

Armed Forces Institute of Pathology (AFIP)/National University of Medical Sciences (NUMS) Rawalpindi Pakistan

ABSTRACT

We report a case of an extremely rare inflammatory condition of appendix, malakoplakia, in a 22 years old female, who presented with chronic abdominal pain. The clinicopathological features of this condition will be discussed, along with a review of the literature.

Keywords: Appendix, Malakoplakia.

This is an Open Access article distributed under the terms of the Creative Commons Attribution License (<http://creativecommons.org/licenses/by/4.0>), which permits unrestricted use, distribution, and reproduction in any medium, provided the original work is properly cited.

INTRODUCTION

Malakoplakia is a rare inflammatory condition affecting gastrointestinal tract having distinct histopathological characteristics. To the best of our knowledge it is the seventh reported case of malakoplakia of the appendix¹.

CASE REPORT

A 22 years old female, presented to Military Hospital, Rawalpindi in March 2016 with history of colicky abdominal pain for the last 3 years. She was treated as a case of intestinal tuberculosis and completed a nine month course of antituberculous drugs. Her symptoms persisted despite this treatment. Abdominal examination revealed mild tenderness in the paraumbilical region.

Colonoscopy was done and showed irregular, erythematous, friable mass in the appendicular orifice, from which multiple biopsies were taken and sent to Armed Forces Institute of Pathology (AFIP) for histopathological examination. The microscopic examination revealed appendiceal mucosa showing focal crypt distortion. The lamina propria showed dense mixed inflammatory infiltrate comprising sheets of foamy histiocytes, neutrophils, eosinophils, lymphocytes and plasma cells. Histiocytes containing laminated

calcified spherules, commonly known as Michaelis-Gutmann (MG) bodies, were also seen (fig-1). Special stains including Periodic acid Schiff (PAS) with diastase, Perl's stain, von Kossa stain were applied which highlighted MG bodies (fig-1b,c,d,e). There was no evidence of malignancy in the sections examined. Keeping in view the findings of microscopic examination and results of special stains, a diagnosis of malakoplakia was made.

Based on our diagnosis, right sided limited hemicolectomy was done and resected specimen (fig-2) was sent to our institute for histopathology. Grossly, there was erythematous mass at the base of appendix, and its microscopy revealed MG bodies in an inflammatory background, thus confirming the initial diagnosis. Patient was advised follow up.

DISCUSSION

Malakoplakia is a benign inflammatory condition, malignant transformation of which has not been reported yet, that can mimic abscess or tumour¹. It was first described in 1902 by Michaelis and Gutmann. In 1903 von Hansemann coined the term 'malakoplakia' derived from the Greek malakos (soft) and plakos (plaque). It has been reported in conjunction with tumors, infections, sarcoidosis and various immunocompromised states².

The most common site of involvement is urinary bladder and rarely it involves pelvis of the kidney, ureter, urethra, stomach, small and

Correspondence: Dr Syed Salman Ali, House No 16 Lane 27 Phase-II Wah Model Town Wah Cantt Pakistan

Email: syedsalmanali85@gmail.com

Received: 22 Nov 2016; revised received: 20 Dec 2016; accepted: 28 Feb 2017

large intestines, appendix, anal canal, perianal region, retroperitoneum, adrenal gland, prostate, epididymis, cervix, vagina, skin, breast, muscle, lymph nodes, bone and brain. Several organs may be involved at the same time².

Microscopically, the lesion is characterized

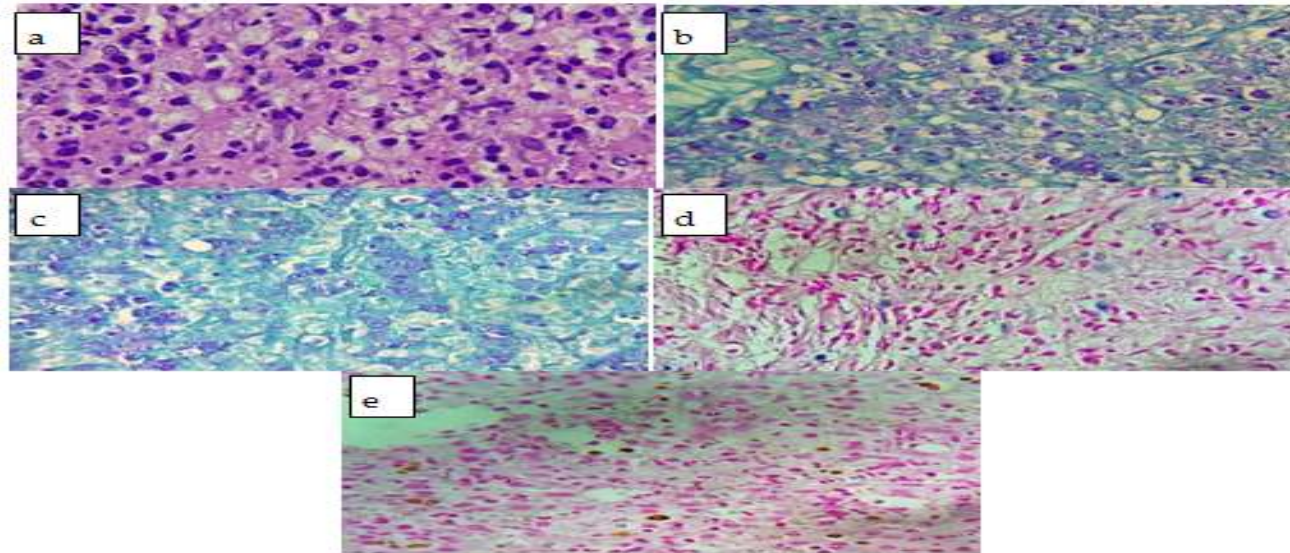


Figure-1: Photomicrograph of Malakoplakia.

(a): Haematoxylin-Eosin (original magnification 10x), (b): PAS (original magnification 10x), (c): PAS diastase (original magnification 10x), (d) Perl's Prussian Blue (original magnification 10x), (e): Von Kossa (original magnification 10x).

by dense aggregates of large mononuclear histiocytes (the 'von Hansemann' cells) admixed with intracellular and extracellular calcified granular inclusions known as Michaelis-Gutmann bodies and lymphoplasmacytic infiltrate. The lesion evolves through 3 phases: an early phase, in which MG bodies are not seen but plasma cells and histiocytes are present in the edematous stroma; a classic phase, in which MG bodies are present in histiocytes alongwith few lymphocytes and plasma cells; and a fibrosing phase, in which occasional MG bodies are present in histiocytes among fibroblasts and collagen in well-defined bundles².

The presence of MG bodies is required for the diagnosis of malakoplakia. These mineralized bodies range in diameter from 5 mm to 10 mm, look like owl eyes or ring particles and are present in intact histiocyte phagosomes. Ultrastructurally, they are composed of concentric crystalline laminations with a thick

inner zone and a fine outer zone. Partially digested bacteria with iron and calcium phosphate are present in the central zone. Gradual deposition of calcium leads to the typical concentric laminations of MG bodies². MG bodies are stained with PAS diastase, von Kossa and

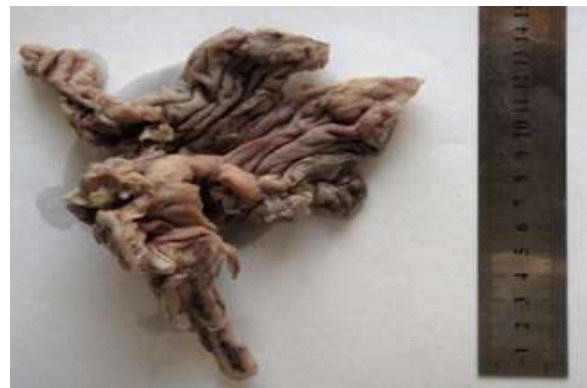

Figure-2: Gross morphology of right sided limited hemicolectomy.

Perl's Prussian blue stains. Immunohistochemically, the cells are positive for CD 68, lysozyme and α -chymotrypsin¹.

The pathophysiology of malakoplakia is not well understood. It has been suggested that the underlying defect is a deficiency of 39, 59-guanosine monophosphate dehydrogenase, resulting in diminished lysosomal breakdown

and decreased bacterial killing. It begins when organisms (bacteria and fungi) penetrate the macrophages. The organisms are then partially digested in the phagolysosomes and eventually damage these structures, resulting in calcification. Recently, impairment of the immunoregulatory effector system has been implicated². Malakoplakia may result from microtubular/microfilamental dysfunction³.

Multimodality treatment has been suggested which varies according to the extent of the disease and condition of the patient. Medical treatment is the first line of management. Ciprofloxacin is the most effective drug. Rifampacin, ascorbic acid, bethanicol and trimethoprim-sulfamethoxazole also have a role in treating malakoplakia. However, in case of extensive disease or association with tumor, surgical debulking followed by ciprofloxacin for residual disease is a preferred treatment⁴.

Malakoplakia has a good prognosis, if it is localized².

CONCLUSION

Malakoplakia of appendix is a rare disease, malignant transformation of which has not been reported yet. The role of pathologist is fundamental in the diagnosis of malakoplakia. Biopsy is useful in excluding other diagnoses and special stains have a vital role in it. It may mimic or coexist with other diseases, so an enhanced awareness is necessary for its optimal management.

CONFLICT OF INTEREST

This study has no conflict of interest to declare by any author.

REFERENCES

1. Shaktawat SS, Sissons MCJ. Malakoplakia of the appendix, an uncommon entity at an unusual site: a case report. *J Med Case Rep* 2008; 2: 181.
2. Jain M, Arora VK, Singh N, Bhatia A. Malakoplakia of the appendix an unusual association with eggs of taenia species. *Arch Pathol Lab Med* 2000; 124: 1828-9.
3. McClure J. Malakoplakia of the gastrointestinal tract. *Postgrad Med J* 1981; 57: 95-103.
4. Pirzada MT, Haider J, Iqbal M, Malik KA. Malacoplakia of rectum. *Pak J Med Sci* 2011; 27: 1191-3.