

Ewing Sarcoma of Chest Wall: Analysis of 19 Patients

Farhan Ahmad Majeed, Ghazanfar Ali, Muhammad Nadeem Paraccha*, Shahid Hameed, Yasser Saeed Khan**, Zahid Hussain**

Combined Military Hospital Multan/National University of Medical Sciences (NUMS) Pakistan, *Combined Military Hospital/National University of Medical Sciences (NUMS) Rawalpindi Pakistan, **Combined Military Hospital Sialkot/National University of Medical Sciences (NUMS) Pakistan

ABSTRACT

Objective: To share the short and long term outcomes of the patients having Ewing Sarcoma of the chest wall.

Study Design: Prospective longitudinal study.

Place and Duration of Study: Thoracic Departments of Combined Military Hospital Rawalpindi, Combined Military Hospital Lahore and Combined Military Hospital Multan from Jan 2010 to Jun 2020.

Methodology: In total, 19 patients were enrolled. Inclusion criteria were physiologically fit patients for one-lung ventilation with proven true-cut histopathology. Exclusion criteria were poor performance status and non-compliance to chemotherapy.

Results: Out of 19 cases, 13 males (68.42%) and six females (31.58%) patients. The age range was from 8 to 29 years, with a mean age of 17.6 + 4.16 years. The most common symptom was palpable mass 19, followed by chest pain 8 and one patient presented with fungating mass. All patients showed partial response to neo-adjuvant chemotherapy as per RECIST criteria. Following resection and confirmation of negative margins, primary reconstruction was done. The soft tissue coverage was provided using Latissimus Dorsi Muscle Flap in 16 Cases (84.21%) and in 03 patients (15.79%) Rectus Abdominis muscle was used. Post operatively, less than 02 blood transfusions were needed in six patients. There was no post-operative ventilatory support required, and mortality was zero.

Conclusion: Ewing Sarcoma of the chest wall is a rare tumour in the adult population. An excellent outcome can be achieved through early diagnosis, meticulous surgical technique and good teamwork in a multi-disciplinary setting.

Keywords: Chest wall, Ewing tumor, Malignant, Reconstruction.

How to Cite This Article: Majeed FA, Ali G, Paraccha MN, Hameed S, Khan YS, Hussain Z. Ewing Sarcoma of chest wall: Analysis of 19 patients. *Pak Armed Forces Med J* 2022; 72(3): 971-974. DOI: <https://doi.org/10.51253/pafmj.v72i3.5738>

This is an Open Access article distributed under the terms of the Creative Commons Attribution License (<https://creativecommons.org/licenses/by-nc/4.0/>), which permits unrestricted use, distribution, and reproduction in any medium, provided the original work is properly cited.

INTRODUCTION

Despite developments in all fields of science, human beings remain vulnerable to multiple maladies. Among these maladies, cancer is one of the leading causes of morbidity and mortality.¹⁻² Common sites for cancer include; breast, lungs and prostate.^{3,4} Chest wall constitutes 1% of the total population having malignancies and 5% of the thoracic neoplasms. They can be grouped according to their origin or type of tumour. About 50-80% of the primary tumours are malignant, and 55% are skeletal in origin.⁵⁻⁶

Ewing Sarcoma is a rare, aggressive malignancy of skeletal and soft tissues. Ewing Sarcoma was first reported by a pathologist James Ewing in 1921 and was named after his work. Histologically, it consists of small round blue cells with CD99 expression. It is caused by translocation of the EWS gene, t (11;22) (q24; q22). Based on the tissue of origin, the Ewing Family of tumours can be divided into Ewing's Sarcoma of bone, extra-osseous, primitive Neuroectodermal tumour, and Askin's tumour of the chest wall and atypical Ewing's

Sarcoma.⁷ It mainly occurs in adolescents and young adults. Ewing Tumor of the chest wall represents a rare tumour in the adult population. Chest wall Ewing's sarcoma constitutes only 15%-20% of total patients with Ewing sarcoma. Ewing sarcoma of the chest wall usually presents with a palpable mass. Patients complain of pain when there is the involvement of the deeper structures in the chest wall like the rib periosteum.^{8,9} Like other chest wall malignancies, Ewing Sarcoma involves deeper structures and resection of the mass invariably results in extensive soft tissue and skeletal tissue defect. Neo-adjuvant chemotherapy has been very effective in down staging the tumour and decreasing the size of the resultant defect. These defects require reconstruction using synthetic mesh reinforced with soft tissue coverage using musculocutaneous flaps. We have been sharing our experience of these rare tumours in our set for over a decade.

METHODOLOGY

This prospective longitudinal study was carried out at the Thoracic Departments of CMH Rawalpindi, CMH Lahore and CMH Multan from January 2010 to June 2019, over ten years after the approval of the Institutional Ethical Review Board and obtaining

Correspondence: Dr Ghazanfar Ali, Department of Plastic Surgery, Combined Military Hospital Multan-Pakistan

Received: 02 Dec 2020; revision received: 04 Aug 2021; accepted: 06 Aug 2021

informed consent from the patients. A sample size of 19 patients was estimated via the EpiTools Epidemiological calculator while keeping the significance level of 5% and confidence level of 95%.¹⁰

Inclusion Criteria: All the physiologically fit patients for one-lung ventilation with proven truecut histopathology and immunohistochemistry typical of Ewing's sarcoma with CD 99 positivity were included in the study. FISH for EWS-Gene was obtained wherever available.

Exclusion Criteria: Patients with metastatic disease at diagnosis, poor performance status and non-compliance to chemotherapy were excluded from the study.

In all patients, lung function tests, Echocardiography, CT scan chest, abdomen and pelvis with IV contrast and bone scan were carried out to assess the local extent of the tumour and distant metastatic status. Workup also included MRI with IV contrast and PET scan in selected cases depending upon the availability. A multi-disciplinary approach was used. In all patients, neoadjuvant chemotherapy comprised the standard protocol of Vincristine, Doxorubicin and Cyclophosphamide alternating with Ifosfomide and Etoposide in three weekly cycles.

All the patients were reassessed with contrast-enhanced CT scan and bone scan to see the tumour's residual disease size and location after four cycles and after planned chemotherapy cycles. Patients with the expected good response as per RECIST criteria were discussed in MDT before surgery. A unipolar cautery and energy source device was used for tumour resection. The resection was carried out with a 4 cm healthy margin. On both cephalid and caudal sides, one normal rib was also excised. The primary reconstruction of the chest wall defect was carried out following confirmation of negative margins on the frozen section in 12 cases only because of limitations of the facility. The structural support was provided using darn of Proline with re-enforcement with Proline mesh 4cm around, and then soft coverage was provided with regional Musculo-cutaneous flaps. The epidural block was used for post-operative pain management in an intensive care setup. They were discharged after one week, and follow up visits were carried out fortnightly for the first two months and then three months for one year.

Statistical Package for Social Sciences (SPSS) version 23.0 was used for the data analysis. The data was described as numbers and percentages.

RESULTS

Out of 19 cases, 13 male (68.42%) and six female (31.58%) patients. The age range was from 8-29 years, with mean age of 17.6 ± 4.16 years. The most common symptom was palpable mass (19), followed by chest pain (8) and one patient presented with fungating mass (Figure-1).

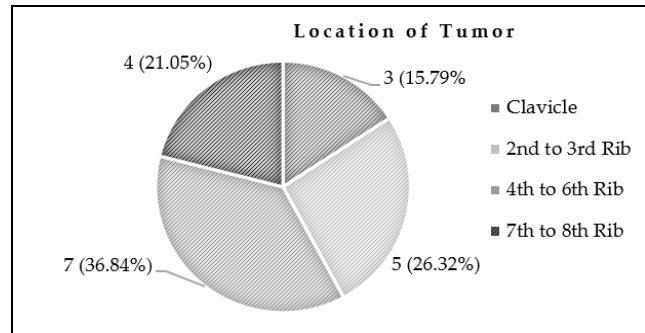


Figure-1: Location of tumor on the chest wall.

All patients showed partial response to neoadjuvant chemotherapy as per RECIST criteria. However, no complete response was seen. Primary reconstruction was done following resection of the tumour and confirmation of negative margins. The soft tissue coverage was provided using Latissimus Dorsi Muscle Flap in 16 cases (84.21%) and in 3 patients (15.79%) Rectus Abdominis muscle was used. Most of the patients had eventless recovery with post-operative morbidity (Figure-2).

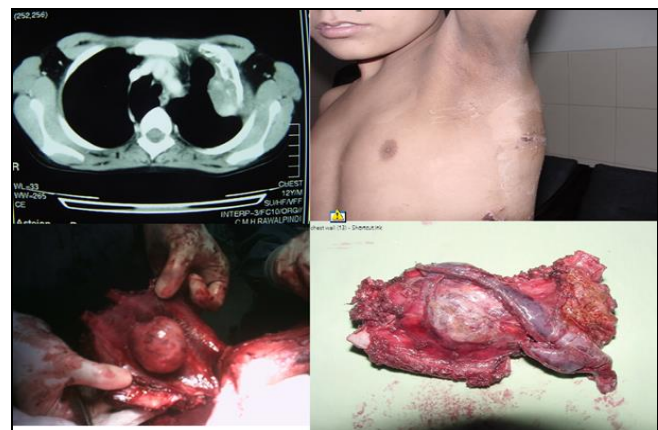

Figure-2: Patient ewing sarcoma chest (CT Scan on the upper left corner and resected specimens in lower two pictures).

Post operatively, less than 2 blood transfusions were needed in six patients. There was no post-operative ventilatory support required, and mortality was zero (Figure-3).

DISCUSSION

The chest wall is not a common site for benign and malignant tumours. Primary Malignant chest wall tumours are more common than benign tumours. Although most malignant chest wall tumours occur in the 3rd and fourth decades of life, there is no age immune to these malignant tumours. Chest wall tumours can present with a wide range of symptoms; Palpable mass, chest pain, breathlessness, anaemia and fungating mass. In our study, all of the patients presented with palpable chest mass. Rarely patients can present with chest pain (8 of our patients) due to the involvement of deeper structures, and in neglected cases fungating mass may be the presenting symptom. A study conducted by Salim *et al*,⁸ reported that 75% of patients presented with painless palpable chest mass and 25 patients with painful mass. However, their study was not limited to Ewing's Sarcoma. The literature is scarce on treating Ewing's Sarcoma of the chest wall.

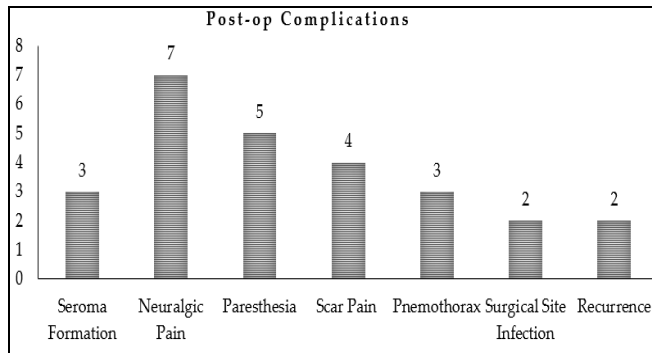


Figure-3: Post-operative complications.

Like other malignancies, the management of Ewing sarcoma of the chest wall requires a multi-disciplinary approach. After establishing the diagnosis, neo-adjuvant chemotherapy is started on the down-stage tumour. For eradication of systemic micro-metastasis, which is not detectable, the use of chemotherapy has become standard. However, there have been debates about the most appropriate chemo therapeutic agents. In the past, multiple regimens of chemo therapy were tried in Ewings sarcoma. However, now it is established that the combination protocol VAC-IE is the standard. In a study conducted in early 2001, Shamberger *et al*,⁹ reported that chemo therapy for chest wall Ewing's Sarcoma could increase the rate of complete resection, and radio therapy can be avoided. There was residual disease and no case of complete regression in our cases. Likewise, a study was conducted by Huvos *et al*,¹⁰ regarding Ewing sarcoma and

Osteosarcoma. They used multiagent chemo therapy, including Doxorubicin, Etoposide, cyclophosphamide and/or Ifosfamide. They reported tumour regression and necrosis in $\geq 90\%$ of cases. This study was conducted in the radiology department, and further details are not available. In another study of Ewing sarcoma of rib, it was found that the addition of etoposide and ifosfamide improved outcomes in the overall group proceeding to surgery. Similarly, this study also showed that the chest wall lesions responded better than other sites as initial surgical resection post-chemotherapy was possible compared to a delayed approach.¹¹

We also saw that all patients did respond to chemotherapy and the initial surgical attempt was possible. No patient was deferred for delayed approach or radiotherapy consolidation.

In our study higher percentage of cases was noted in patients in the 11-20 year age bracket. A study conducted by Jacobs *et al*,¹² reported that 48.7% of cases occurred in the 11-17 years age group. The same trend has been seen in North American,¹³ and European,¹⁴ studies. In our study, no patient had metastasis at the time of presentation. Different findings were reported in a study carried out by Denbo *et al*,¹⁵ at St Jude Research Hospital, where about 39% of patients had metastasis. However, a study conducted by Duchman *et al*,¹⁶ reported that 32% of patients had systemic metastasis at the time of presentation. A study conducted by Jacobs *et al*,¹² reported that 37% of patients had systemic metastasis at the time of presentation. All these findings are not much diverse but different from our study as no patients in our study had metastatic disease.

A study conducted by Bagheri *et al*,¹⁷ reported a 4 cm healthy margin during the tumour resection. Therefore, we used a 4 cm healthy margin to excision the tumour for clearance. The same method has been reported in many studies.

Post operatively reconstruction of the chest wall is dependent on the size, location, extent of the chest wall defect and general condition of the patient. Reverse planning is done after resection of the tumour. For a defect involving three or more ribs, reconstruction of the chest wall was carried out using synthetic mesh and soft tissue coverage using a local myo-cutaneous flap. Our study provided soft tissue coverage using Lat Dorsi Flap in 16 (84.21%), and Rectus abdominis Muscle Flap was used in only 3 (15.79%) patients. Due to reliable vascularity, supple soft tissue coverage, and minimal donor site morbidity, the Lat Dorsi Muscle

flap has been used as the preferred option for providing soft tissue coverage in chest wall reconstruction in many studies. Other options like Rectus Abdominis Muscle, Omentum or free flap are also valuable tools in the armamentarium for reconstruction. The use of synthetic mesh is common in chest wall reconstruction. Ito *et al.*¹⁸ reported in a mini-review for chest wall reconstruction in 41.3% of cases using material ePTFE or Polypropylene mesh with an excellent outcome. Like these scientific studies, Rahman *et al.*¹⁹ conducted a study on primary chest wall tumour outcomes. They reported that pain was the most common presenting symptom in Ewing Sarcoma of the chest (75%). They carried out chest wall reconstruction with synthetic mesh and local muscle flaps for soft tissue coverage and reported a similar complication rate to our study.

Neuralgic pain was the most common complication, followed by Paresthesia, i.e., 07 (36.84%) and 05 (26.32%), respectively. Seroma formation was noted only in 15.79% of patients. A study conducted by Wu *et al.*²⁰ reported Seroma formation in 31% of patients. They used 3D printing technology in chest wall reconstruction following resection. However, their study was not limited to the Ewing sarcoma of the chest wall. Only 18% of the Ewing tumours were located in the chest wall in their study. Therefore, the complication rate was almost the same as in our study.

As the Ewing sarcoma of the chest is a rare entity, more studies are required to document all aspects of the tumour behaviour. Therefore, a multi-disciplinary approach is required to achieve excellence.

ACKNOWLEDGEMENT

The authors highly appreciate the valuable support provided by the Lt Col Tariq CI HCA, CMH Multan, at all stages in writing this article.

LIMITATIONS OF THE STUDY

Ewing tumour of the chest wall is a rare tumour in adults. Only 19 cases were treated over ten years. Moreover, the literature search does not show much work on this topic and further studies are needed on this topic.

FUNDING SOURCE

There is no outside funding source for this study to be revealed.

CONCLUSION

Ewing Sarcoma of the chest wall is a rare tumour in the adult population. An excellent outcome can be achieved through early diagnosis, meticulous surgical technique and good teamwork in a multi-disciplinary setting.

Conflict of Interest: None.

Authors' Contribution

FAM: Main author, GA:, MNP:, SH:, YSK:, ZH: Data analysis and interpretation.

REFERENCES

1. Coste J. Suffering and Disease in History - The relevance of their study to contemporary medicine and public health. *Med Sci* 2015; 31(3): 329-334.
2. Torre LA, Siegel RL, Ward EM, Jemal A. Global cancer incidence and mortality rates and trends - an update *Cancer Epidemiol Biomarkers Prev* 2016; 25(1): 16-27.
3. Davenport JR, Vo KT, Goldsby R, West DC, DuBois SG. Conditional survival and Predictors of late death in patients with ewing sarcoma. *Pediatr Blood Cancer* 2016; 63(6): 1091-1095.
4. Smittenaar CR, Petersen KA, Stewart K, Moitt N. Cancer incidence and mortality projections in the UK until 2035. *Br J Cancer* 2016; 115(9): 1147-1155.
5. Bueno J, Lichtenberger JP 3rd, Rauch G, Carter BW. MR Imaging of Primary Chest Wall Neoplasms. *Top Magn Reson Imaging* 2018; 27(2): 83-93.
6. Carter BW, Benveniste MF, Betancourt SL, de Groot PM, Lichtenberger JP 3rd, Amini B, et al. Imaging Evaluation of Malignant Chest Wall Neoplasms. *Radiographics* 2016; 36(5): 1285-306.
7. Askin FB, Rosai J, Sibley RK, Dehner LP, McAlister WH. Malignant small cell tumor of the thoracopulmonary region in childhood: a distinctive clinicopathologic entity of uncertain histogenesis. *Cancer* 1979; 43(6): 2438-2451.
8. Salim M, Bilal A, Nabi MS. Primary chest wall neoplasms-an experience of 39 patients. *Ann King Edward Med Uni* 2004; 10(1): 49-51.
9. Shamberger RC. Ewing's sarcoma/primitive neuroectodermal tumor of the chest wall. *Semin Pediatr Surg* 2001; 10(3): 153-160.
10. Huvos AG, Schwartz LH, Thaler HT, Tofts PS, Gorlick R, Koutcher JA, et al. Osteogenic and Ewing sarcomas: estimation of necrotic fraction during induction chemotherapy with dynamic contrast-enhanced MR imaging. *Radiol* 2003; 228(1): 271-278.
11. Shamberger RC, Laquaglia MP, Krailo MD, Miser JS, Pritchard DJ, Gebhardt MC, et al. Thoracic wall lesion in children. *J Thorac Cardiovasc Surg* 2000; 119(6): 1154-1161.
12. Jacobs AJ, Fishbein J, Levy CF, Glick RD. Chest wall Ewing sarcoma: a population-based analysis. *J Surg Res* 2016; 204(2): 475-480.
13. Indelicato DJ, Keole SR, Lagmay JP, Morris CG, Gibbs CP Jr, Scarborough MT, et al. Chest wall Ewing sarcoma family of tumors: long-term outcomes. *Int J Radiat Oncol Biol Phys* 2011; 81(1): 158-166.
14. Stiller CA, Bielack SS, Jundt G, Steliarova-Foucher E. Bone tumours in European children and adolescents, 1978-1997. Report from the Automated Childhood Cancer Information System project. *Eur J Cancer* 2006; 42(13): 2124-2135.
15. Denbo JW, Shannon Orr W, Wu Y, Wu J, Billups CA, Navid F, et al. Timing of surgery and the role of adjuvant radiotherapy in ewing sarcoma of the chest wall: a single-institution experience. *Ann Surg Oncol* 2012; 19(12): 3809-3815.
16. Duchman KR, Gao Y, Miller BJ. Prognostic factors for survival in patients with Ewing's sarcoma using the surveillance, epidemiology, and end results (SEER) program database. *Cancer Epidemiol* 2015; 39(2): 189-195.
17. Bagheri, R Haghi, SZ Kalantari, MR Primary malignant chest wall tumors: analysis of 40 patients. *J Cardiothorac Surg* 2014; 19(9): 106.
18. Ito T, Suzuki H, Yoshino I. Mini review: surgical management of primary chest wall tumors. *Gen Thorac Cardiovasc Surg* 2016; 64(12): 707-714.
19. Rahman AR, Rahouma M, Gaafar R, Bahaa S, Loay I, Kamel M, et al. Contributing factors to the outcome of primary malignant chest wall tumors. *J Thorac Dis* 2017; 9(12): 5184.
20. Wu Y, Chen N, Xu Z, Zhang X, Liu L, Wu C, et al. Application of 3D printing technology to thoracic wall tumor resection and thoracic wall reconstruction. *J Thorac Dis* 2018; 10(12): 6880.