

## URETHRAL DUPLICATION A RARE CAUSE OF EVEN RARER DORSAL CHORDEE

Naveed Ahmed, Mian Sarfraz Gul\*, Iftikhar Ahmed\*\*, Shafqat Rehman\*\*, Omar Fraz\*\*, Zahid Anwar\*\*

Combined Military Hospital Quetta/National University of Medical Sciences (NUMS) Pakistan, \*Muhammad College of Medicine, Peshawar Pakistan, \*\*Pak Emirates Military Hospital/National University of Medical Sciences (NUMS) Rawalpindi Pakistan

### ABSTRACT

Chordee is a condition in which the penile head has a curvature. It can be towards ventral or dorsal aspect. Dorsal chordee is very rare. In many normal males mild degrees of curvature can exist. Causes of dorsal chordee can be diverse but urethral duplication as its etiology is even rarer. We report a case of six year old boy who presented with severe dorsal chordee with associated double urethra and cleft of the glans dorsally without hypospadias.

**Keywords:** Chordee, Hypospadias, Urethra.

This is an Open Access article distributed under the terms of the Creative Commons Attribution License (<https://creativecommons.org/licenses/by-nc/4.0/>), which permits unrestricted use, distribution, and reproduction in any medium, provided the original work is properly cited.

### INTRODUCTION

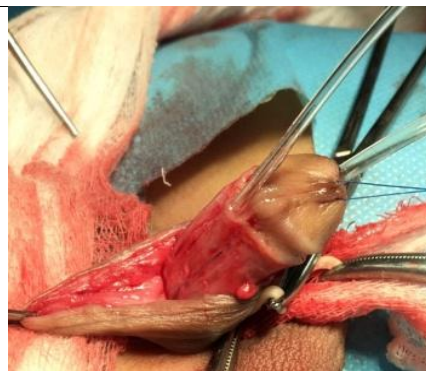
Chordee is a condition in which the penile head has a curvature. It can be either towards ventral aspect or dorsal aspect. It generally occurs at the junction of the head and shaft of the penis. It usually becomes most obvious and noticeable during erection. The underlying causative factors for chordee can be many like hypospadias, disorder of sexual development and differentiation or trauma. It may also result as a complication of circumcision<sup>1,2</sup>. It is usually considered a congenital malformation without any known cause. Chordee may result from arrest in penile development during fetal life or as a result of a vascular accident. Conditions like hypospadias are usually associated with sev-

### CASE REPORT

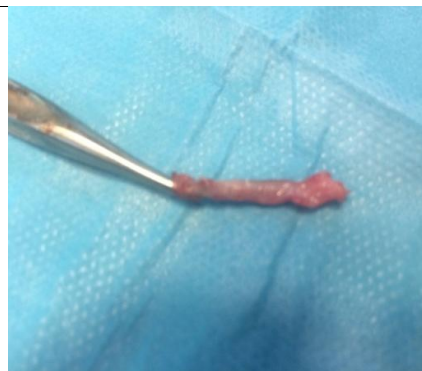
A 6-year old boy presented with history of urinary stream directed upward since birth. Examination revealed upward curvature (dorsal chordee) of the penile shaft. He had been circumcised at birth. On dorsal aspect an opening was visible at coronal sulcus associated with cleft of the glans dorsally (fig-1). Urethral meatus was at its normal location and child was passing urine from urethral meatus with no history of passage of urine from opening on dorsal aspect of penis. Radiological workup was unremarkable. After detailed parental counselling surgery was planned. During surgery a feeding tube was passed through the opening at dorsal aspect but it was blind ending at the level



**Figure-1: Dorsal chordee with cleft of the glans.**



**Figure-2: Degloving and duplicated urethra.**



**Figure-3: Excised duplicated urethra.**

*Note: Pictures are posted after detailed explanation to parents of the child and seeking their consent.*

ere degrees of chordee, however, a milder form of curvature is even possible in otherwise normal males who do not have hypospadias<sup>3</sup>. However, urethral duplication is rarely found as a cause of dorsal chordee.

of symphysis pubis. Another tube was passed through urethral meatus and it drained the urine. Penile shaft was degloved (fig-2) and that blind ending tubular structure was found to be the causative factor for the chordee due to fibrotic tissue along with it applying a pulling force on penile shaft causing severe dorsal chordee. The tract along with fibrotic tissue was excised till its origin at the level of symphysis pubis (fig-3)

**Correspondence:** Dr Naveed Ahmed, Classified Paediatric Surgeon, Combined Military Hospital, Quetta Pakistan

Received: 17 Nov 2020; revised received: 26 Apr 2021; accepted: 03 May 2021

and chordee was corrected and was confirmed by artificial erection. Cleft of the glans was repaired and wound closed formally. Histopathology of the blind ending tract revealed that it was a blind ending urethra, denoting double urethra.

### DISCUSSION

Duplication of urethra is a rare anomaly seen in males. It is often associated with other congenital anomalies especially involving the gastro-intestinal and genitourinary tracts<sup>4</sup>. Not much is known about embryogenesis of urethral duplication and various hypotheses exist<sup>5</sup>. The spectrum of presentation can vary depending upon the type of anomaly according to Effmann classification system<sup>6</sup>. If we talk about chordee, it is more common on ventral side and often associated with hypospadias. Although one study demonstrated that chordee can be seen in boys with meatus in its orthotopic position<sup>7</sup>, duplication of urethra and dorsal chordee are both rare anomalies at their own and they mostly exist in isolation but very occasionally, like in our case, they can co-exist. A 10 years old boy with coronal hypospadias was reported to have dorsal chordee<sup>8</sup> contrary to our patient who had orthotopic meatus which tells rarity of this condition. Another case was reported in which a 9 years old male child presented with double urinary stream along with dorsal chordee. One meatus was at its orthotopic position as in our case while duplicated urethra was located on dorsal aspect 1 cm proximal to normal meatus having a communication with genitourinary tract that was not seen in our case<sup>9</sup>. At the same time there is another spectrum of presentation of urethral duplication in which a 15 years old boy presented with double urinary stream with two urethral openings, one located normally and one located 1 cm proximally on dorsal aspect without any other abnormality. The patient was not offered any

treatment<sup>10</sup>. In this patient also, duplication of urethra was noted in isolation without evidence of chordee.

### CONCLUSION

Urethral duplication can have varied presentations. Its rarity, either in isolation or in association with other congenital anomalies warrants that the clinician must be conversant with its different manifestations. Timely recognition of this anomaly and its associated conditions especially dorsal chordee is important. Aim of treatment is to correct the abnormality in order to have a cosmetically and functionally normal penis.

### CONFLICT OF INTEREST

This study has no conflict of interest to be declared by any author.

### REFERENCES

1. American academy of pediatrics: circumcision policy statement. *Pediatr* 1999; 103: 686-93.
2. Kaplan MD, George W. Complications of circumcision. *Urol Clin N Amer* 1983; 10: 543-49.
3. Singh S, Rawat J, Kureel S, Pandey A. Chordee without hypospadias: operative classification and its management. department of pediatric surgery, CSM Medical University, Lucknow, India.
4. Arena S, Arena C, Scuderi MG, Sanges G, Arena F, Di Benedetto V. Urethral duplication in males: our experience in ten cases. *Pediatr Surg Int* 2007; 23: 789-94.
5. Bhadury S, Parashari UC, Singh R, Kohli N. MRI in congenital duplication of urethra. *Indian J Radiol Imag* 2009; 19: 232-34.
6. Lopes R, Giron AM, Mello MF, Barbosa CM, Santos J, Moscardi PR, et al. Urethral duplication type influences on the complications rate and number of surgical procedures. *Int Braz J Urol* 2017; 43: 1144-51.
7. Montag S, Palmer LS. Abnormalities of penile curvature: chordee and penile torsion. *Sci World J* 2011; 11: 1470-78.
8. Mane S, Arlikar J, Reddy S, Dhende N. Hypospadias with dorsal chordee: Case report of a novel approach for correction. *J Indian Assoc Pediatr Surg* 2011; 16: 158-59.
9. Suoub M, Saleem MM, Sawaqed F. Complete urethral duplication: case report and literature review 2020; 12: 15-20.
10. Baid M, Dutta A. Urethral duplication in a 15-year-old: case report with review of the literature. *Rev Urol* 2014; 16: 149-51.