

GENDER ASSIGNMENT IN COMPLETE ANDROGEN INSENSITIVITY SYNDROME. WHO SHOULD BE THE DECISION MAKER

Naveed Ahmed, Iftikhar Ahmed, Safdar Awan, Omair Arshad Dar, Shehla Kanwal, C. Aqeel Safdar, Mudasir Saleem

Pak Emirates Military Hospital/National University of Medical Sciences (NUMS) Rawalpindi Pakistan

ABSTRACT

Androgen insensitivity syndrome (AIS) is a condition in which the target cells are unable to respond to androgenic hormones. This inability can be complete or partial. Although the individual is a genetic male due to the presence of Y chromosome but clinical presentation can vary ranging from a complete male to full female habitus. There are also individuals that lie in between these two extremes depending upon the severity of the condition. Gender assignment in such patients poses a great challenge for the care givers, parents and the patients. We report a very rare case of 10-year old phenotypic female who presented in outpatient department with bilateral inguinal hernia and during management she turned out to be a patient of complete androgen insensitivity syndrome (CAIS).

Keywords: Androgen insensitivity syndrome, Decision maker, Y chromosome.

This is an Open Access article distributed under the terms of the Creative Commons Attribution License (<http://creativecommons.org/licenses/by/4.0>), which permits unrestricted use, distribution, and reproduction in any medium, provided the original work is properly cited.

INTRODUCTION

AIS is a condition in which the target cells are unable to respond to androgenic hormones due to mutation of the gene encoding the androgen receptor¹. The etiology of AIS can be either due to deficiency of testosterone hormone, deficiency of androgen receptors or deficiency of enzyme 5 α -reductase. Although the individual is a genetic male due to the presence of Y chromosome but clinical presentation can vary ranging from a complete male to full female habitus². There are also individuals that lie in between these two extremes depending upon the severity of the condition. In complete AIS, phenotype is completely female despite having 46, XY karyotype and they are generally raised in concordance with their phenotype. In partial AIS, although the individual is a genetic male with 46, XY karyotype but he is partially masculinised. Gender assignment in AIS depends on the size of the phallus. If the phallus size is small, it may be appropriate to raise the patient as female. Those who have reasonably sized phallus can be raised as males because the response to the exogenous testosterone is better but decision regarding

gender assignment in such patients remains an open debate.

CASE REPORT

A 10 years old phenotypic female presented in out door clinic with history of bilateral inguinal swelling for the last 3 months. On examination she was found to have swelling in both inguinal regions with visible and expansile cough impulse. No contents were palpable. She had female external genitalia (fig-1). Abdominal examination was unremarkable. Clinical diagnosis of bilateral inguinal hernia was made. Her bilateral laparoscopic herniotomy was planned. Parents were explained in detail accordingly. During surgery, when telescope was put in, surprisingly no female internal organs were seen. Two gonads with vas and vessels were seen in the pelvis bilaterally (fig-2). Both deep rings were open. Biopsy of both the gonads was taken which later turned out to be testicular tissue. Herniotomy was postponed with a view point that operative findings will be discussed with parents and further management to be deferred till complete workup of the patient. At the same time her external genitalia was examined which revealed a blind ending lower one third of the vagina (fig-3). Her karyotyping turned out to be XY that denotes CAIS. Issue was discussed in detail with parents

Correspondence: Dr Naveed Ahmed, Department of Pediatric Surgery, Combined Military Hospital, Quetta Pakistan

Received: 03 Jan 2019; revised received: 10 Jun 2019; accepted: 21 Jun 2019

but there was a difference of opinion between both parents regarding gender assignment. Mother wanted to convert the child to male keeping in view that by doing so, he will be able to earn his living but contrary to this, father was

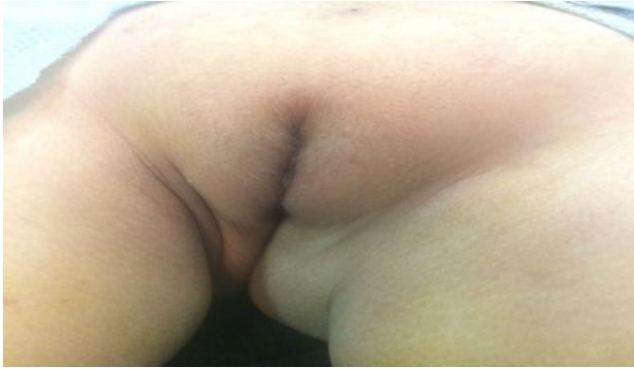

Figure-1: Female external genitalia.

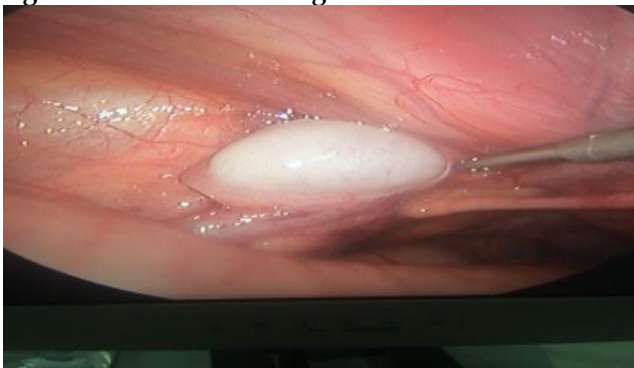


Figure-2: Intra abdominal testis. No female internal organs.

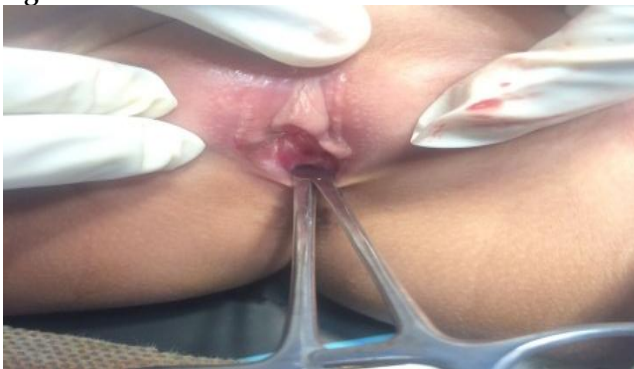

Figure-3: Blind ending lower one third of vagina.

Note: All the pictures are posted with consent of the parents of the patient.

of the opinion that the child should be reared as female because otherwise it will be a big psychological trauma for the child once the diagnosis

is disclosed. Moreover, they were not willing to involve the child in decision making process.

DISCUSSION

AIS especially CAIS is a rare and complex disorder. It is not only difficult to treat but it also has social and psychological implications especially when gender assignment is considered. When the target cells become unresponsive to the androgenic hormones, the developing fetus fails to develop masculinized genitalia. At puberty, it also results in failure of development of male secondary sexual characteristics. But this unresponsiveness of the target cells in genetic males does allow the development of female external genitalia and secondary sexual characteristics. This condition can also be associated with other morbidities like decreased bone mineral density, gonadal tumors, vaginal hypoplasia and dyspareunia³. Management of such patients has a very wide spectrum that includes gender assignment, genital reconstructive surgery, gonadectomy due to increased risk of tumor, hormone replacement therapy, genetic counselling and more importantly psychological support. A case was reported in 2013 when a 30 years old phenotypic female married for 8 years without a child presented with bilateral inguinal hernia and on investigations she was found to have no female internal organs with XY karyotyping and intra-abdominal testes in which case gonadectomy was performed and news was not disclosed to the family keeping in mind the psychological sequelae. Post-operatively patient was given estrogen replacement therapy⁴. In another case reported by Filippa *et al* in 2017 when 11 years old phenotypically female patient presented with urinary retention and during investigations found to be genotypic male and when the news was disclosed to the parents, they left the decision of gender assignment to the patient⁵. Generally in our society this is not the practice because parents are the ones who are mainly involved in decision making. If we have a look on the main stake holders involved in the management of such patients, they are clinicians, parents, patient and the last but not the least, the society. Out of all the

areas of management, the main concern is gender assignment and in this regard based on the cause and extent of the defect in 46 XY disorder, there is a lack of uniform guidelines⁶. It is very difficult to construct a phallus in a phenotypic female and so far only one case is reported in which male gender was assigned⁷. It is easy to rear a genetic male as a phenotypic female but in our society which is considered to be a male dominant one, when parents come to know about the diagnosis of their child, they become more inclined to convert her in to a male and also they do not want to involve the child in the decision making process. Resultantly patients with CAIS tend to experience anxiety and stress due to their physical characteristics and also with a sense of stigma arising from secrecy to hide their condition imposed by families and society⁸. However, in present age of medical advancements, the affected individual should not be kept ignorant from the diagnosis of CAIS. Clinician should have a considerate approach towards parents and the patient with CAIS for disclosure of the diagnosis once it is made and also for planning and implementing the possible future plans. For patients who are young children, the disclosure of the diagnosis is an ongoing process with involvement of the parents till the time they are in a position to understand and make a decision depending upon the patient's mental development. In the management of such patients, the assistance from a child psychologist who is expert in the subject cannot be ruled out⁹.

CONCLUSION

CAIS is a challenging disorder both for the clinician and for the parents but effected individual is the one who actually faces the challenges

like psychologically accepting the diagnosis, body habitus, social interactions, sexual relations and infertility. Undoubtedly, with appropriate medical treatment, parent's education, social support and psychological uplifting, individuals with CAIS can be satisfied with their sexual function and psychosexual development. CAIS individuals can lead active lives and expect a normal lifespan¹⁰.

CONFLICT OF INTEREST

This study has no conflict of interest to be declared by any author.

REFERENCES

1. Mendoza N, Motos MA. Androgen insensitivity syndrome. *Gynecol Endocrinol* 2013; 29: 1-5.
2. Stouffs K, Tournaye H, Liebaers I, Lissens W. Male infertility and the involvement of the X chromosome. *Hum Reprod* 2009; 15(6): 623-37.
3. Quint EH, McCarthy JD, Smith YR. Vaginal surgery for congenital anomalies. *Clin Obstet Gynecol* 2010; 53(1): 115-24.
4. Nair R, Bhavana S. XY Female with Complete Androgen Insensitivity Syndrome with Bilateral Inguinal Hernia. *J Obstet Gynaecol India* 2012; 62(Suppl-1): 65-67.
5. Pritsini F, Kanakis G, Kyrgios I, Kotanidou E, Litou E, Mouzaki K, et al. Psychological aspects of androgen insensitivity syndrome: two cases illustrating therapeutical challenges. *Case Rep Endocrinol* 2017; 2017(2): 1-5.
6. D'Alberton F, Assante MT, Foresti M, Balsamo A, Bertelloni S, Dati E, et al. Quality of life and psychological adjustment of women living with 46, XY differences of sex development. *J Sex Med* 2015; 12(1): 1440-49.
7. T'Sjoen G, De Cuypere G, Monstrey S, Hoebeke P, Freedman FK, Appari M, et al. Male gender identity in complete androgen insensitivity syndrome. *Arch Sex Behav* 2011; 40(1): 635-38.
8. Gangaher A, Chauhan V, Jyotsna V, Mehta M. Gender identity and gender of rearing in 46 XY disorders of sexual development. *Indian J Endocrinol Metab* 2016; 20(1): 536-41.
9. Oakes MB, Eyvazzadeh AD, Quint E, Smith YR. Complete androgen insensitivity syndrome - a review. *J Pediatr Adolesc Gynecol* 2008; 21(6): 305-10.
10. Wisniewski AB, Migeon CJ, Meyer-Bahlburg HFL, Gearhart JP, Berkovitz GD, Brown TR, et al. Complete androgen insensitivity syndrome: long-term medical, surgical, and psychosexual outcome. *J Clin Endocrinol Metab* 2000; 85(8): 2664-69.