

## EFFECTIVENESS OF STEROIDS VERSUS IMMUNOMODULATORS INTREATMENT OF VERNAL KERATO-CONJUNCTIVITIS. A STUDY AT ARMED FORCES INSTITUTE OF OPHTHALMOLOGY

Zahra Arsalan, Omer Zafar, Syed Abid Hassan Naqvi, Quratulain Zamir

Armed Forces Institute of Ophthalmology/National University of Medical Sciences (NUMS) Rawalpindi Pakistan

### ABSTRACT

**Objective:** To evaluate whether steroids or immunomodulator is a better mode of treatment in long term management of vernal keratoconjunctivitis.

**Study Design:** A quasi experimental study.

**Place and Duration of Study:** Armed Forces institute of Ophthalmology, Rawalpindi, from Feb 2019 to Oct 2019.

**Methodology:** Ninety-two patients in between ages of 5-20 years were divided into two equal groups of 46 patients each. After instillation of 0.1% Fluoromethalone (steroid) into both eyes of patients of vernal keratoconjunctivitis, in group A and outcomes were compared with those of 0.05% Cyclosporine (immunomodulator) administered in the same manner in group B. All the patients were followed up regularly after 1, 3, and 6 weeks, 3 months, and 6 months and data recorded for inference.

**Results:** Both the drugs were found to effectively reduce the foreign body sensation but had no or minimal effect on visual acuity and intraocular pressure ( $p$ -value $<0.001$ ). Few patients in steroid group showed noticeable rise of intraocular pressure ( $p=0.02$ ). Cyclosporine was found to markedly reduce the mucoid discharge and photophobia without any adverse side effects ( $p$ -value $=0.02$ ).

**Conclusion:** Cyclosporine appears to be more effective in control of mucous discharge and inflammation than steroids in vernal keratoconjunctivitis with minimal or no side effects and hence was found to be a safe alternative to steroid usage in long-term treatment groups.

**Keywords:** Allergy, Conjunctiva, Cornea, Immunomodulators, Steroids, Vernal.

**How to Cite This Article:** Arsalan Z, Zafar O, Naqvi SAH, Zamir Q. Effectiveness of Steroids Versus Immunomodulators Intreatment of Vernal Kerato-Conjunctivitis. A Study at Armed Forces Institute of Ophthalmology. Pak Armed Forces Med J 2021; 71(6): 2045-2048.

DOI: <https://doi.org/10.51253/pafmj.v6i6.5144>

This is an Open Access article distributed under the terms of the Creative Commons Attribution License (<https://creativecommons.org/licenses/by-nc/4.0/>), which permits unrestricted use, distribution, and reproduction in any medium, provided the original work is properly cited.

### INTRODUCTION

Vernal keratoconjunctivitis is an itchy condition of the eyes that develops typically in childhood and adolescence. It is generally bilateral and arises due to seasonal changes triggering a chronic inflammatory state of the eye (Figure).

Vernal keratoconjunctivitis is a potentially debilitating condition where the person suffering must confront repeated ocular itching, tearing, burning sensation, photophobia, foreign body sensation, and mucoid discharge.<sup>1</sup> Vernal keratoconjunctivitis is an important cause of hospital referral among children in many parts of Africa, Asia, and the Middle East.<sup>2</sup> The pathophysiology includes, IgE and T-cell mediated allergic response to various factors including environmental allergens and weather conditions. Genetic predisposition is still debatable. Mast cells, eosinophils, and other inflammatory mediators play a critical role in producing congestion, conjunctival hyperemia, and tarsal and

limbal papillae. Repeated blinking with the papillae leads to punctate epithelial keratitis and micro erosions, which in turn lead to shield ulcers and fibrosis and neovascularization and adversely affect the visual acuity in some cases.<sup>3</sup> Immunomodulators are anti-IgE

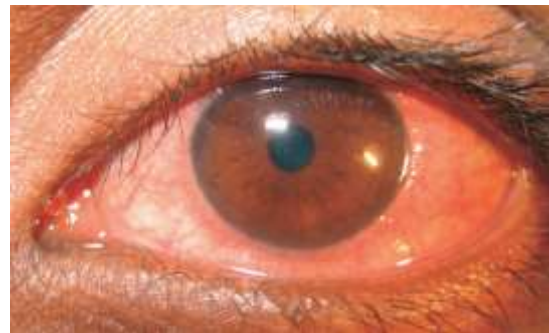


Figure: Vernal keratoconjunctivitis.

antibodies, that bind to circulating IgE, resulting in inactivation of the immune complexes, which are then cleared from the plasma. This in turn suppresses the activation of the mast and hence suppression of the inflammatory pathway. The male population is mostly effected.<sup>4</sup> Vernal keratoconjunctivitis will go away over

**Correspondence:** Dr Zahra Arsalan, Resident Ophthalmology, Armed Forces Institute of Ophthalmology, Rawalpindi Pakistan

Received: 21 Aug 2020; revision received: 17 Sep 2020; accepted: 23 Sep 2020

the years on its own, but the several years of discomfort and inflammation leave one with debilitating sequelae like ulcers and fibrosis. If it is detected and treated early, it has a good prognosis. Frequently topical mast cell stabilizers and antihistamines are first-line drugs that are prescribed. However, in severe cases with impending complications, topical steroids and immune modulators, which target the halting the lymphocyte proliferation and hence interleukin production are used. Steroids which are commonly prescribed for these cases also can lead to complications such as corneal scarring and advanced steroid-induced glaucoma.

In our study, we aimed to find whether Cyclosporin was a safer steroid alternative with minimum side effects.

## METHODOLOGY

The quasi-experimental study was conducted from February 2019 to October 2019 at the Armed Forces Institute of Ophthalmology, Rawalpindi. It was approved by the Ethics Committee of the institute vide certificate number 188/ERC/AFIO dated 6th Dec 2017 and informed written consent was taken from all patients.

**Inclusion Criteria:** Patients between the ages of 5-20 years were included in the study without any gender discrimination.

**Exclusion Criteria:** All the patients who had undergone any refractive procedures, infected eyes, and corneal complications were excluded from the study. Patients having associated corneal diseases, uveitis, glaucoma, and optic atrophy were also points of exclusion.

A total of 92 patients were divided into two groups (A and B) of 46 patients each. Consecutive sampling was done. One drop of topical 0.1% Fluoromethalone (steroid) was instilled into both eyes four times a day in group A and compared with the results of the installation of 0.05% Cyclosporine (immunomodulator) in the same manner in group B. One week of washout period was given to those patients who were previously taking treatment of vernal keratoconjunctivitis and were included in the study. All patients were followed up after 1, 3, and 6 weeks, 3 months, and 6 months. The study's effect size was 0.89 estimated from a reference study.<sup>5</sup> Using an online World Health Organization WHO sample size calculator, the sample size was calculated to be 46 patients in each group which equals a total of 92. The level of significance was taken as 95%, power of the study was 0.85, the effect

size of 0.89, standard deviation of 1.5, and a two-tailed hypothesis was considered for sample size calculation. Variables such as inflammation were assessed by Ozlem Scoring system,<sup>6</sup> (Table-I).

**Table-I: The scoring method of inflammation in vernal keratoconjunctivitis.**

Signs	SCORE			
	0	1	2	3
Conjunctival Hyperemia	None	Mild	Moderate-signs	Severe
Tarsal Papillae	None	<1 mm	1-3 mm	>3 mm
Limbal Papillae	None	<2mm or <90	2-4 mm or 90-180	>4 mm or >180
Corneal Involvement	Normal Cornea	Fine SPEK*	Coarse SPEK/ macro erosion	Shield ulcer/ pannus

\*SPEK: Superficial Punctate Epithelial Keratitis Ozlem et al<sup>6</sup>

Visual acuity was measured using Snellen's chart, intraocular pressure was measured using applanation tonometry and air puff and Corneal thickness (535-555  $\mu$ m) was measured with VKG. Inflammation control, Photophobia, Mucus discharge, and foreign body sensation were documented at each visit. Data were analyzed using Statistical Package for Social Sciences (SPSS) version 23. Descriptive analysis was done for simple frequencies and Fisher's test was applied for comparison of Dichotomous categorical variables while Pearson- chi-square test was used for comparison of categorical variables. The *p*-value of  $\leq 0.05$  was of statistical significance.

## RESULTS

A total of 92 patients were distributed into two groups of 46 in each group. The mean age of group A (steroid group) was  $10.7 \pm 2.8$  years while in group B, the mean age of the patients was  $9.9 \pm 3.2$  year.

At the end of the study, it was seen that the visual acuity in both groups remained unaffected on a comparative level. Only 3 (6.5%) patients out of 46 in each group showed betterment of vision, which reflects that both treatments are likely to help in the same quantity with respect to clarity of vision (*p*-value  $< 0.001$ ). The intraocular pressure remained unaffected in the cyclosporine group while 6 patients in the steroid group had notable intraocular pressure rise from the base reading measured at the first visit (*p*=0.02).

The severity of inflammation was found to reduce significantly earlier in the trial with topical Cyclosporine eye drops installation than the topical steroid eye drops instillation. Though long-term results were alike for both groups (Table-II). Both the drugs at the end of the study appeared to equally help in controlling

the foreign body sensation in eyes, though the foreign body sensation at week 1 appeared to be better in group A with steroid eye drops instillation (Table-III). The effects of Cyclosporine on mucus production appeared more effective than steroids in long follow up (Table-IV). Photophobia was also less for the Cyclosporine group in week.<sup>1</sup> While later both proved to be of same benefit (Table-V).

**Table-II: Severity of Inflammation in both groups.**

Duration	Severity of Inflammation	0.1% Fluoromethalone, n (%)	0.05% Cyclosporine n (%)	p-value
Week 1	Mild	-	4 (8.7)	<0.001
	Moderate	23 (50)	35 (76)	
	Severe	23 (50)	7 (15.2)	
Week 3	Mild	4 (8.7)	21 (45.7)	<0.001
	Moderate	33 (71.7)	25 (54)	
	Severe	9 (19.6)	-	
Week 6	Mild	22 (48)	40 (87)	0.001
	Moderate	24 (52)	6 (13%)	
	Severe	-	-	
3 months	Mild	46 (100)	46 (100)	-
	Moderate	-	-	
	Severe	-	-	
6 months	Mild	46 (100)	46 (100)	-
	Moderate	-	-	
	Severe	-	-	

**Table-III: Effects on foreign body sensation in both groups.**

Duration	Foreign Body Sensation	0.1% Fluoromethalone, n (%)	0.05% Cyclosporine n (%)	p-value
Week 1	No	3 (6.5)	-	0.024
	Yes	43 (93.5)	46 (100)	
Week 3	No	15 (32.6)	13 (28.3)	0.821
	Yes	31 (67.4)	33 (71.1)	
Week 6	No	41 (89.1)	41 (89.1)	1.00
	Yes	5 (10.9)	5 (10.9)	
3 Months	No	42 (91)	46 (100)	0.117
	Yes	4 (9)	-	
6 Months	No	45 (98)	45 (98)	1.00
	Yes	1 (2)	1 (2)	

**Table-IV: Effects on mucus production in both groups (Separate the table).**

Duration	Mucus Production	0.1% Fluoromethalone	0.05% Cyclosporine	p-value
Week 1	No	5 (11%)	-	0.056
	Yes	41 (89%)	46 (100%)	
Week 3	No	17 (37%)	34 (55%)	0.001
	Yes	29 (63%)	12 (45%)	
Week 6	No	40 (87%)	44 (96%)	0.267
	Yes	6 (13%)	2 (9%)	
3 Months	No	46 (100%)	46 (100%)	-
	Yes	-	-	
6 Months	No	46 (100%)	46 (100%)	-
	Yes	-	-	

**Table-V: Effects on Photophobia in both groups (separate the table).**

Duration	Photophobia	0.1% Fluoromethalone n (%)	0.05% Cyclosporine n (%)	p-value
Week 1	No	-	6 (13%)	0.026
	Yes	46 (100%)	40 (87%)	
Week 3	No	19 (41%)	27 (59%)	0.144
	Yes	27 (59%)	19 (41%)	
Week 6	No	43 (94%)	43 (94%)	1.000
	Yes	3 (7%)	3 (7%)	
3 Months	No	45 (98%)	46 (100%)	1.000
	Yes	1 (2%)	-	
6 Months	No	46 (100%)	46 (100%)	-
	Yes	-	-	

## DISCUSSION

Vernal keratoconjunctivitis is an allergic disease, which is documented to lead to complications such as shield ulcers and can cause permanently reduced vision.<sup>7</sup> The commonly used drugs for the treatment of vernal keratoconjunctivitis include antihistamines, steroids, and immunomodulators. The main aim is to provide relief from uncomfortable symptoms such as itching, foreign body sensation, watering, and ophthalmic discharge.<sup>8</sup> For the management of vernal keratoconjunctivitis induced symptoms, the mainstay has always been through steroid usage, which is known to be effective but also cause side effects in long term usage such as raised intraocular pressure, cataract etc.<sup>9,10</sup> Even with mild steroid formulations it is known to have complications.<sup>11-12</sup> Hence an attempt to compare the effects of immunomodulators like Cyclosporine over steroids, in controlling symptoms was monitored in our study.

Our study showed that in the first 6 weeks Cyclosporine group (group B) showed better control of moderate inflammatory symptoms, while the steroid group (group) had more effect on moderate to severe inflammation. However later in the treatment, there was no significant difference in control of all grades of inflammation between both the groups. As supported by the results of Ozlem *et al*<sup>6</sup>, who found that lower concentrations (0.1% and 0.05%) of Cyclosporine are good steroid-sparing agents in steroid-responsive patients. In contrast to their study, we were able to have significant results proving early betterment of symptoms such as mucoid discharge, inflammatory conditions, and photophobia in the Cyclosporine group, while Ozlem observed that the effect started after 2 weeks of administration of the drug. Their study also highlighted that adjuvant Cyclosporine with steroids help in reducing the need for steroids hence providing a safe and effective alternative in vernal keratoconjunc-

tivitis. This was also supported by our study results where there was no visual or intraocular pressure deterioration seen after Cyclosporine use.<sup>13,14</sup>

Phogat *et al.*<sup>13</sup> studied around 100 patients who were treated with topical Cyclosporine eye drops and found an appreciable reduction in signs and symptoms. Compared to our study, not only the inflammatory condition got better with the treatment but also other complaints like discharge, photophobia was also noticed to be less. Supporting our results, another study by Hayatullah and Edward,<sup>14</sup> highlighted many other studies,<sup>15</sup> where the roles of topical Cyclosporine, antihistamine, and tacrolimus were studied. They found that Cyclosporine and tacrolimus proved to have better effects in controlling the inflammation and complaints of discharge than steroids. The possible reason for Cyclosporine to have affected better in controlling the disease was explained by Utine *et al.*,<sup>16</sup> when they studied that the number of clusters of differentiation 4 (CD4) and interleukin (IL-17) were reported to decrease after the treatment with Cyclosporine ( $p=0.08$ ) hence reducing the inflammatory pathway and inflammation. Cyclosporine was considered to have augmentative effects in other studies also.<sup>16-18</sup> Our study revealed that the foreign body sensation and discomfort due to photophobia showed an almost equal response to the use of the 2 drugs after 1 week.

## CONCLUSION

Control of inflammation and mucoid discharge was better with Cyclosporine than steroids with no significant side effects like rise in intraocular pressure. We conclude that Cyclosporine is a safe and effective alternative to steroid usage, in patients who require long term treatment for vernal keratoconjunctivitis.

**Conflict of Interest:** None.

## Authors' Contribution

ZA: Conception of the main topic, design of study, reasearch and data compilation and statistics, OZ: Overall supervision and final approval, SAHN: Text evaluation and grammatical correctins, QZ: Full assistance in data and research compilation and proof reading.

## REFERENCES

- Chatterjee A, Bandyopadhyay S, Bandyopadhyay SK. Efficacy, safety and steroid-sparing effect of topical cyclosporine A 0.05% for vernal keratoconjunctivitis in Indian children. *J Ophth Vis Res* 2019; 14(4): 412-415.
- Abiy M, Betelhem T, Sofonias A. Prevalence of vernal keratoconjunctivitis and its associated factors among children in Gambella town, southwest Ethiopia. *PLoS One* 2019; 14(4): e0215528.
- Doan S, Amat F, Gabison E, Saf S, Cochereau I, Just J. Omalizumab in severe refractory vernal keratoconjunctivitis in children: case series and review of the literature. *Ophthalmol Ther* 2017; 6(1): 195-206.
- Arif AS, Aqil B, Siddiqui A, Nazneen Z, Farooq U. Corneal complications and visual impairment in vernal keratoconjunctivitis patients. *J Ayub Med Coll Abbott* 2017; 29(1): 58-60.
- Clarissa F, Carneiro D, Thiago C, Malcolm R, Olavo B. Effect size and statistical power in the rodent fear conditioning literature-A systematic review. *PLoS One* 2018; 13(4): e0196258.
- Ozlem E, Nihal D. Efficacy and safety of topical Cyclosporine A 0.05% in vernal keratoconjunctivitis. *Singapore Med J* 2016; 57(9): 507-510.
- Al-Amri AM, Mirza AG, Al-Hakami AM. Tacrolimus ointment for treatment of vernal keratoconjunctivitis. *Middle East Middle East Afr J Ophthalmol* 2016; 23(1): 135-138.
- Shoughy SS, Jaroudi MO, Tabbara KF. Efficacy and safety of low-dose topical tacrolimus in vernal keratoconjunctivitis. *Clin Ophthalmol (Auckland, NZ)* 2016; 10(2): 643-645.
- Gokhale NS. Systematic approach to managing vernal keratoconjunctivitis in clinical practice: Severity grading system and a treatment algorithm. *Ind J Ophthalmol* 2016; 64(2): 145-148.
- Ahmed SM, Ahmed KE, El Morsy OA, Soliman SS. Epidemiology of Vernal keratoconjunctivitis among children aged (12-15) years. Menofia Governorate, Egypt. *Delta J Ophthalmol* 2019; 20(1): 1-5.
- Gokhale NS. Systematic approach to managing vernal keratoconjunctivitis in clinical practice: Severity grading system and a treatment algorithm. *Ind J Ophthalmol* 2016; 64(2): 145.
- Lian QW, Xu C, Heng L, Jin WC, Rui LW. Loteprednol etabonate in the treatment of allergic conjunctivitis: a meta-analysis. *Curr Med Res Opin* 2015; 31(8): 1509-1518.
- Phogat J.. Study of efficacy and safety of topical Cyclosporine in vernal keratoconjunctivitis. *Ind J Sci Res* 2017; 7(2): 109-112.
- Hayatullah B, Edwar L. Comparison of efficacy and safety outcome among tacrolimus ointment, cyclosporine, and anti histamine in managing patient with allergic conjunctivitis. *Ophthalmol Indon* 2020; 46(1): 68-72.
- Pradhnya S, Swapnil J, Amit M, Chintan S, Alok S, Elesh J. Pattern of steroid misuse in vernal keratoconjunctivitis resulting in steroid induced glaucoma and visual disability in Indian rural population: An important public health problem in pediatric age group. *Ind J Ophthalmol* 2019; 67(10): 1650.
- Utine CA, Stern M, Akpek EK. Immunopathological features of severe chronic atopic keratoconjunctivitis and effects of topical Cyclosporine treatment. *Ocul Immunol Inflamm* 2019; 27(7): 1184-1193.
- Roberto C, Francesco V, Neri P, Cinzia L, Gioia D. Very low prevalence of keratoconus in a large series of vernal keratoconjunctivitis patients. *Am J Ophthalmol* 2016; 172(2): 64-71.
- Sacchetti M, Abicca I, Bruscolini A, Cavaliere C, Nebbioso M, Lambiase A. Allergic conjunctivitis: current concepts on pathogenesis and management. *J Biol Regul Homeost Agents* 2018; 32(Suppl-1): 49-60.