

LAPAROSCOPIC CHOLECYSTECTOMY: A STUDY OF DEMOGRAPHIC, MORPHOLOGICAL FACTORS AND IATROGENIC OCCURRENCES

Muhammad Muttahhar Asim Niaz, Fahd Mudassar Hameed, Mudassira Zahid*

PAF Hospital, Islamabad Pakistan, *Al-Nafees Medical College & Hospital, Islamabad Pakistan

ABSTRACT

Objective: To compare the morbid anatomy and iatrogenic problems and complications encountered during laparoscopic cholecystectomy (LC) in both genders.

Study Design: A cross sectional analytical study.

Place and Duration of Study: The study was conducted at Pakistan Air Force Hospital, Islamabad, from May 2017 to Jan 2019.

Methodology: All patients who underwent LC during our study period were included in the study. A pre-designed proforma was used to record data. The cases were divided into two groups based on gender. The parameters studied for each group included appearance of gallbladder, intra operative bile leakage, requirement of hemostatic procedure, spillage of stones, multiplicity of stones i.e. single vs. multiple, operative time and need of drain placement.

Results: A total of 120 patients were included in the study. There were 21 (17.5%) male and 99 (82.5%) female subjects. The mean age was 43.66 ± 13.8 years with range of 11-74 years. Normal looking gallbladder was more common in females. Thick walled gallbladder was less frequent in females (males 66.7% vs. females 39.4% $p=0.043$) Intraoperative complications were more in males. There was no statistically significance gender difference in number of stones, spillage of stones and need for hemostasis.

Conclusion: Symptomatic gallstones were mostly found in females. Gender differences exist as regards the apparent morphology & difficult operative factors. Performance of LC in our setup is of a standard comparable to those of other centers. Since morbid anatomy of females is more favorable, so surgeons new to LC should be encouraged to perform surgery on female patients.

Keywords: Gallbladder, Laparoscopic cholecystectomy, Morphology, Operative complications.

This is an Open Access article distributed under the terms of the Creative Commons Attribution License (<http://creativecommons.org/licenses/by/4.0>), which permits unrestricted use, distribution, and reproduction in any medium, provided the original work is properly cited.

INTRODUCTION

Cholecystectomy is the treatment of choice for symptomatic gallstone disease. Ever since, the first Cholecystectomy was performed by Dr Carl Johann August Langenbuch in 18821, mankind had to wait for more than a hundred years when the Gallbladder could be removed through smaller incisions. The first well acknowledged Laparoscopic cholecystectomy (LC) was performed by Phillips Mouret in Lyon in 19871.

LC is now considered a safe and effective technique for the management of symptomatic gallstone disease. Variations in the anatomy of gallbladder and biliary ducts and their blood

supply have long been recognized. The typical text book anatomy is found in only 20-40% of cases¹. In chronic cholecystitis there may be apparent changes in the anatomy of gallbladder which can create difficulty for the operating surgeon¹. Apart from congenital variations, the misinterpretation of normal anatomy can lead to serious complications during LC¹.

LC is being routinely performed in our hospital. Our technique involves a standard 4 port access, with the 2 right ports of 5mm and an epigastric 12mm port. Umbilical port is a 5mm or 12mm as per operating surgeon's choice. Gallbladder is removed from the epigastric port. This study was conducted to find out differences over some of the points of morbid anatomy encountered by surgeons during LC in male and female patient groups. A record of operative

Correspondence: Dr Muhammad Muttahhar Asim Niaz, Dept of Surgery, PAF Hospital Islamabad Pakistan

Received: 22 Mar 2019; revised received: 22 Jul 2020; accepted: 10 Aug 2020

steps was also made e.g., how hemostasis was ensured in different cases. With these in mind the operating surgeons will be more cautious or confident when performing LC on different sets of patients. It will also help training supervisors on which patient to give to their trainees or junior colleagues as an 'under direct supervision' or 'indirect supervision', case.

METHODOLOGY

This was a cross sectional analytical study carried out at Pakistan Air Force Hospital, Islamabad. The study duration was one year from May 2017 to January 2019. The cases were selected by non-probability convenient sampling technique. An informed consent was taken prior collection of the data from the patients. We aimed to compare the morbid anatomy and iatrogenic problems and complications encountered during LC in both genders.

All patients from both genders in whom LC was done for gallstones were included in the study irrespective of age. Patients who underwent a conversion from Laparoscopic to open cholecystectomy due to anesthesia related issues or surgical difficulties including dense adhesions and profound hemorrhage were excluded from the study.

The observations were recorded on a pre-designed proforma which included the following parameters:

The age and gender of patients.

The apparent condition (morphology) of gallbladder at the start of the procedure i.e., whether it was normal looking, thick walled, distended and tense or contracted. Presence/absence of any iatrogenic biliary leak. If yes, whether it was due to the gallbladder being punctured or perforated, slippage of cystic duct clip on gall bladder side, from injury to extra hepatic biliary tree, leakage from accessory cystic duct, or leakage from accessory channels between the liver and gallbladder the "ducts of Luschka".

Presence/absence of significant bleeding requiring a need to control hemostasis. If yes, the

mode of hemostasis control whether by sustained pressure, electrocautery or use of Harmonic or Ligasure. Whether the gallbladder had multiple calculi or a solitary calculus. Presence/absence of any spillage of calculi within the peritoneal cavity.

Operative time in minutes, from start of incision to closure of incision at port sites. Need for placement of a sub hepatic drain. The guidelines used for indications to place a drain in sub-hepatic space, after LC, included:

- a. Difficult dissection
- b. Extensive bile leak
- c. More than normal hemorrhage requiring cautery and other energy source
- d. Spillage of stones
- e. Use of saline for washing off bile leakage or hemorrhage

The data was analyzed using SPSS version 20. The mean and standard deviation were used for the quantitative variables. For the evaluation of qualitative variables frequencies were calculated in terms of percentages. The comparison of qualitative variables between the two groups was done by chi square test. The *p*-value of ≤ 0.05 was taken as significant.

RESULTS

A total of 123 patients underwent LC during the study period. There were three conversions to open cholecystectomy which were excluded from study. Cause of conversion was difficult dissection due to dense adhesions and hemorrhage.

Out of 120 patients 21 (17.5%) were male, and 99 (82.5%) were female, with a male to female ratio of 1:5. The age range was 11-74 years with a mean age of 43.66 ± 13 years. Mean age of male patients and female patients was 47.77 years (SD ± 15.57 years) and 42.35 years (SD ± 15.01 years) respectively.

Regarding the apparent morphology of GB a significant difference existed between the genders with a *p*-value of 0.043. Females most frequently had a normal looking GB, 54 (54.6%)

and males had a thick walled GB 14 (66.7%). Normal looking GB was less common in males. Contracted, distended and tense appearance was less common in both the genders table-I.

In majority of the females 82 (82.8%) bile leak was not observed. The intraoperative bile

leak when present was more common in males (p -value=0.42). There was no statistical significant difference between both genders for the need for haemostasis (p -value=0.42). Coagulation by cautery to control bleeding and achieve hemostasis was the most common method 68 (68.6%) of females and 13 (61.9%) of males respectively. Of these

Table-I: Comparison of morphological appearance of GB and multiplicity of gallstones between genders.

Observations	Female Patients	Male Patients	p -value
Morphological Characteristics			
Normal looking GB	54 (54.6%)	6 (28.6%)	0.05
Thick-walled Gallbladder	39 (39.4%)	14 (66.7%)	
Contracted Gallbladder	1 (1.0%)	1 (4.8%)	
Tense Gallbladder	5 (5.1%)	-	
Number of Gallstones			
Multiple stones	83 (83.8%)	16 (16.2%)	0.40
Solitary stone	16 (76.2%)	5 (23.8%)	

leak when present was more common in males (p -value 0.035). It was present in 17 (17%) females and 8 (38%) males. Leak in most of the cases was through puncture of gallbladder, none of the bile leak was through rest of the extra-hepatic biliary tree i.e., common bile duct or right or left hepatic duct or from accessory cystic duct or accessory channels between the liver and gallbladder the

electrocoagulation using spatula was required in 2 (2%) of females and 1 (4.6%) of males. Ligasure was used in 3 patients. It is noteworthy that, because of negligible blood loss, around 25-30% of cases in both groups did not require any tool to acquire hemostasis.

Majority of patients had multiple calculi in their GB. There was no significant gender difference,

Table-II: Comparison of Intraoperative complications .

Observations	Female patients	Male patients	p -value
Intraoperative Bile Leakage			
No leakage	82 (82.8%)	13 (61.9%)	0.030
Cystic duct leakage	1 (1.0%)	1 (4.8%)	
GB puncture	16 (16.2%)	6 (28.6%)	
GB perforation	-	1 (4.8%)	
Intraoperative Haemostasis			
Hemostasis not required	27 (27.2%)	6 (28.5%)	0.72
Ligasure Scalpel	2 (2%)	1 (4.7%)	
Cautery	68 (68.6%)	3 (13%)	
Pressure Application	2 (2%)	1(4.7%)	
Intraoperative Stone Spillage			
Spillage present	9 (9.1%)	1 (4.8%)	0.51
Spillage not present	90 (90.9%)	20 (95.2%)	
Requirement For Drain Placement			
Drain placed	47 (47.5%)	15 (71.4%)	0.046
Drain not placed	52 (52.5%)	6 (28.6%)	

"ducts of Luschka" Leakage from slippage of clip applied on gallbladder side of the cystic duct occurred in 1 case each in females and males, table-II.

ence, (figure). Stone spillage within the abdominal cavity while performing LC or removing the GB from the peritoneal cavity was seen in 10

patients. These were 9 (9.1%) and 1 (4.7%) cases among females and male subgroups respectively.

In the current study, the need to place a drain was more frequent in males with a significant *p*-value=0.046 table-II. The operating time starting from first port incision to final wound closure was measured. Though we could not

In study thick walled GB were 53 (44.16%). Of these 66.6% were male and 39.3% females. In a study conducted by Sharma *et al*, 80.77% patients had normal looking GB² while 19.23% had thick walled gallbladder. In another study Masud *et al*⁸, reported 80.77% having normal GB wall thickness and 19.23% having thick wall GB. They

Table-III: Operative times in different morphology of gallbladder.

	Normal Looking Gallbladder	Thick Walled Gallbladder	Contracted Gallbladder	Tense Gallbladder	Overall Mean Time
Male	42 min	56min	63 min	-	52 min
Female	39 min	52 min	108	64 min	46 min

Table-IV: Demographic comparison of studies.

Study Name	Age Range	Mean Age SD ± 3.81
Dawani S <i>et al</i>	21 - 71 years	40.9 years
Al-Sayigh HA ¹¹	20 - 80 years	46 years
Masud M ⁸	20 - 70 years	50 years
Seeramulu PN	16 - 75 years	41 years
The Current Study	11 - 74 years	43.66

record operating time of all the cases still, the minimum operating time was 22 min and longest 108 min. The mean operating time, of cases whose operating times was recorded, was 46 min for females and 52 min for males, table-III.

DISCUSSION

Gallstone disease is more prevalent in females. In the literature frequency of female patients in LC for gallstones is reported as 1 (91.75%), 1 (82.4%) and 1 (88.9%). In the current study, 82.5% of patients belonged to female gender. In other studies it was 3 (88.2%) (Dawani *et al*)³, 1 (84%) (Hashimoto *et al*)⁹, 91% (Ahmad *et al*)⁴ 1 and 91.75% (Oonwala *et al*)⁶. The demographic comparison of the current study with other studies is depicted in table-IV.

In the current study there was a significant difference between genders in the morphology of the gallbladder. The females had more frequent normal looking gallbladder morphology 54.5% as compared to males. Whereas a thick walled gallbladder was more frequent in males 28%. The change from normal appearance to thick walled gallbladder indicates the complexity of disease and reflects upon the difficulty of the operative procedure.

reported shrunken GB in 11.2% of patients. In the current study shrunken/ ontracted GB were in 1.66% of patients. Thick walled GB is suggestive of chroniccholecystitis, though not pathognomic.

A normal looking gallbladder indicates that patient had not had any attack of acute cholecys-

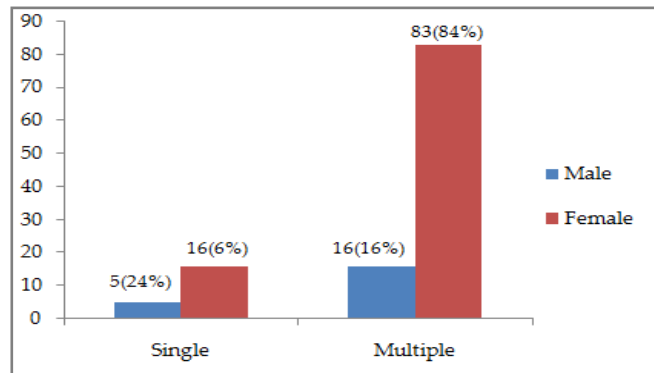


Figure: Solitary vs multiple stones.

titis and was either operated for symptomatic gallstone disease or as a pre-emptive to drastic complications of gallstones. Asymptomatic gallstones are those that have not caused biliary symptoms.

Lap cholecystectomy is a very safe treatment² but does have complications of which some carry a high morbidity and mortality. In our settings as the treatment is free of cost for the

patients. Therefore, every effort is made to ensure that patients are truly symptomatic or there is a definite indication for surgery. Moreover, LC is freely offered for patients with acute cholecystitis reporting early due to the expertise of our surgeons, therefore, the number of normal looking gallbladders are less as compared to other studies. In men more patients are observed to have thick walled gallbladders. One explanation is that male patients tend to ignore milder forms of symptoms, and opt for surgery only later in advanced disease.

Intraoperative bile leak in the current study was in 24 (20%) of cases and spillage of gallstones was in 10 (8%) of cases. Seeramulu *et al*¹⁴, reported gallbladder perforation in 38 (7.5%) and gallstone spillage in 30 (6%) cases³. A possible explanation for this could be the operating surgeons being less careful in preventing leakage of bile as no post-operative sequel of bile leakage has been observed over the years. The same observations were made by Thomas *et al*¹⁵, and Camilo *et al*¹⁶.

There may be various methods to achieve hemostasis. We usually use diathermy to achieve hemostasis. Harmonic Scalpel or Ligasure though superior was used only in those cases where bleeding was difficult to control by diathermy. It was noteworthy that in 27 (27.2%) of cases among females and 6 (28.5%) of cases among males, in this study, didn't require any means for hemostasis. Use of energy source in laparoscopic surgery is not without complications and can lead to significant morbidity especially when used near CBD¹⁷. It is our routine to keep the use of energy source to minimum. Our technique involves the dissection of cystic duct and artery in the Callot's triangle by blunt teasing of tissues and only to start using cautery after cystic duct and artery has been clipped and divided. By this technique minor bleeding occurs but risk of injury to extra-hepatic biliary tree is avoided or minimized.

Majority of our patients had multiple stones in the gallbladder. This was comparable to other studies. Multiple calculi in 87.5%, 87% and in 70.8% of patients reported by Ahmad *et al*¹⁰, by

Talpur *et al*¹⁸, and by Jan *et al*⁷, respectively. Gallstone spillage in our study was in 10 (8.3%) cases. This was in comparison with Seeramulu *et al* study which was 30 (6%)¹³. The spillage of bile and gallstones occurred because of gallbladder perforation (42%-75%), traction (15%-51%), or during extraction of the gallbladder through a narrow trocar opening (5%-10%) or due to slippage of the cystic duct clip during handling of the gallbladder (14%-21%)¹⁵. An appropriate surgical technique is fundamental in reducing the risk of perforations and gallstone spillage.

Spilled stones which are not retrieved can cause complications^{14,15}, including post-operative abscess and adhesions. However, Welch *et al*¹⁹, and Cline *et al*²⁰, noted that leaving sterile gallstones in the peritoneum does not increase the formation of adhesions or abscesses. Zisman *et al*²¹, also did not report systemic complications due to spilled gallstones and surgical clips during LC although they did cause a moderate local inflammatory reaction. It is recommended to wash the peritoneal cavity thoroughly with Normal saline in all such cases¹⁶, followed by drain placement.

In this study, drain was placed in 15 (71.4%) of males and 47 (47%) of females. However in selected patients with potential bile leak e.g., imperfect closure of cystic duct, bile staining of liver bed suggesting the possibility of missed accessory duct, difficult cholecystectomy due to inflamed gallbladder and/or adhesions, drainage may be justified¹². Routine placement of sub hepatic drain is a routine by some surgeons⁷.

The operating time varied between surgeons and the condition of the gallbladder. Time increased from normal looking gallbladder to thick walled to tense and to contracted with multiple adhesions. Moreover bile or stone spillage also increased the operating time. The minimum operating time was 22 min and longest 108 min. The average time was 46 min for females and 52 min for males. An average operating time of 58 min and 45 min for LC in acute vs. Chronic cholecystitis was reported by Shireen *et al*²², and an aver-

age time of 103.9 min by Karim *et al*²³. Khan *et al*²⁴, reported a mean operative time of 40 min²³. Our operating time matched other studies. The mean duration of surgery was also greater in males in another study by Kumar *et al*²⁵. Moreover, male patients operated mostly had chronic cholecystitis (thick walled gallbladder) as compared to females where normal looking gallbladder was more prevalent.

CONCLUSION

Performance of LC in our setup is of a standard comparable to those of other centers in Pakistan and worldwide. Symptomatic gallstone requiring LC are mostly found in females. Gender differences exist as regards the apparent morphology of the gallbladder and intraoperative complications but not as regards the multiplicity of stones and stone spillage. The morbid anatomy of females is more favorable for the surgeons new to laparoscopic surgery and so the new surgeons should be encouraged to perform surgery on female patients early in their learning curve.

CONFLICT OF INTEREST

This study has no conflict of interest to be declared by any author.

REFERENCES

1. Sparkman RS, 100th Anniversary of the First Cholecystectomy: A Reprinting of the 50th Anniversary. *Arch Surg* 1982; 117(12): 1525-31.
2. Testas P, Dewatteville JC. Laparoscopic cholecystectomy. *Ann Gastroenterol Hepatol (Paris)* 1993; 29(6): 300-06.
3. Dawani S, Sandhya A, Rasul S, Ali M. Frequency of common anatomical variations in the extrahepatic biliary tract in patients undergoing elective cholecystectomy. *Pak J Surg* 2013; 29(1): 61-65.
4. Ahmad MA, Khan NM, Ullah A. Anatomical variations of hepatobiliary triangle in patients operated laparoscopically for gallbladder diseases from Lahore and Sahiwal Punjab Univ. *J Zool* 2016; 31 (1): 47-52.
5. Nagral S. Anatomy relevant to cholecystectomy. *J Minim Access Surg* 2005; 1(2): 53-58.
6. Khan S, Oonwala ZG. An Audit of Laparoscopic Cholecystectomy. *Pak J Surg* 2007; 23(2): 100-03.
7. Jan H, Rafiq MS, Khan A, Wazir HK, Saeed T. An Audit of Laparoscopic cholecystectomy. *J Med Sci* 2015; 23(1): 46-49.
8. Masud M, Ahmed M, Gondal ZI, Adil M, Aqil A, Ashraf F. Laparoscopic cholecystectomy: a clinical practice audit. *Pak Armed Forces Med J* 2015; 65(2): 252-56.
9. Hashimoto M, Hashimoto M, Ishikawa T, Iizuka T, Matsuda M. Right hepatic duct entering into the cystic duct. *Surg Endosc* 2020; 16 (359): 1029.
10. Ahmad MA, Khan NM, Ullah A. Anatomical variations of hepatobiliary triangle in patients operated laparoscopically for gallbladder diseases from Lahore and Sahiwal. *Punjab Univ J Zool* 2016; 31(1): 47-52.
11. Al-Sayigh HA, The Incidence of Cystic Artery Variation during Laparoscopic Surgery. *Med J Bab* 2010; 7(3-4): 389-03.
12. Sharma N, Sharma DK, Sukhadia M, Barolia DK. The impact of the gall bladder wall thickness on surgical management in patients undergoing cholecystectomy-A prospective study. *Int J Curr Microbiol Appl Sci* 2015; 4(6): 514-21.
13. Steiner CA, Bass EB, Talamini MA, Pitt HA, Steinberg EP. Surgical rates and operative mortality for open and laparoscopic cholecystectomy in Maryland. *N Engl J Med* 1994; 330(6): 403-08.
14. Sreeramulu PN, Agrawal VP. Laparoscopic cholecystectomy: Our experience in a rural setup. *Med J DY Patil Univ* 2014; 7(1): 33-35.
15. Hui TT, Giurgiu DI, Margulies DR. Iatrogenic gallbladder perforation during laparoscopic cholecystectomy: etiology and sequelae. *Am Surg* 1999; 65(10): 944-48.
16. Castellón-Pavon CJ, Morales-Artero S, Martínez-Pozuelo A. Complications Due to Spilled Gallstones and Surgical Clips During Laparoscopic Cholecystectomy. *Cir Esp* 2008; 84(1): 3-9.
17. Agarwal BB, Gupta M, Agarwal S, Mahajan KC. Laparoscopic cholecystectomy without using any energy source. *J Laparosc Adv Surg Tech A* 2007; 17(3): 296-01.
18. Talpur KA, Laghari AA, Yousfani SA, Malik AM, Memon AI, Khan SA. Anatomical variations and congenital anomalies of extra hepatic biliary system encountered during laparoscopic cholecystectomy. *J Pak Med Assoc* 2010; 60(2): 89-93.
19. Welch N, Hinder RA, Fitzgibbons RJ, Rouse JW. Gallstones in the peritoneal cavity. A clinical and experimental study. *Surg Laparosc Endosc* 1991; 1(4): 246-47.
20. Cline RW, Poulos E, Clifford EJ. An assessment of potential complications caused by intraperitoneal gallstones. *Am Surg* 1994; 60(5): 303-05.
21. Zisman A, Loshkov G, Negri M, Herbert M, Halpern Z, Lin G. The fate of long-standing intraperitoneal gallstone in the rat. *Surg Endosc* 1995; 9(1): 509-11.
22. Damani AA, Haider S, Bilal H, Perveen S. Comparison of operative time and length of hospital stay in laparoscopic cholecystectomy in acute versus chronic cholecystitis. *J Ayub Med Coll Abbot* 2015; 27(1): 102-04.
23. Karim T, Kadyal A. A comparative study of laparoscopic vs. open cholecystectomy in a suburban teaching hospital. *J Gastrointest Dig Sys* 2015; 5(6): 371-77.
24. Khan DJ, Hassan H, Iqbal M. Laparoscopic cholecystectomy at rawalpindi general hospital - A clinical practice audit. *Pak Armed Forces Med J* 2010; 60(4): 1-5.
25. Kumar S, Kumar P, Verma RK, Agarwal A. A study of impact of gender on operative findings and outcome in patients undergoing laparoscopic cholecystectomy. *Int Surg J* 2017; 4(1): 390-94.