

## Accuracy of Rapid Diagnostic Test for Malaria Compared to Microscopy

Sanober Shah, Jamal Waris\*, Hina Mushtaq\*\*, Imran Khan\*\*\*, Mashoq Ali\*\*\*\*, Nighat Afridi\*\*\*

Pakistan Naval Ship Rahat Hospital, Karachi Pakistan, \*Combined Military Hospital Jhelum/National University of Medical Sciences (NUMS) Pakistan, \*\*Rehman Medical Institute, Peshawar Pakistan, \*\*\*Combined Military Hospital Peshawar/National University of Medical Sciences (NUMS) Pakistan, \*\*\*\*Army Medical College/National University of Medical Sciences (NUMS) Rawalpindi Pakistan

### ABSTRACT

**Objective:** To determine the diagnostic accuracy of the Rapid Diagnostic Test in the detection of malaria by taking routine microscopy as a gold standard.

**Study design:** Cross-sectional study.

**Place and Duration of Study:** Department of Haematology, Pakistan Naval Ship Rahat Hospital, Karachi Pakistan, from Aug 2018 to Jan 2019.

**Methodology:** Patients diagnosed as a case with malaria were included. Malaria was confirmed by using a Rapid detection test and microscopy. Mean and standard deviations were calculated for the quantitative variables like age. Frequencies and percentages were calculated for the qualitative variables like gender. Sensitivity, specificity, positive predictive value, negative predictive value and diagnostic accuracy were calculated.

**Results:** Out of 175 patients in the study, the mean age was  $39.30 \pm 11.29$  years. 85 (48.6%) were male, and 90 (51.4%) were female. Out of 175 patients, sensitivity, specificity, positive predictive value, negative predictive value and diagnostic accuracy of the rapid diagnostic test for malaria, keeping microscopy as the gold standard was found to be 87.2%, 74.15%, 67.34%, 85.71% and 80.57% respectively.

**Conclusion:** Rapid immune-capture tests can have excellent applicability in malaria diagnosis. Field workers can reliably read such tests without any supervision. It appears to satisfy the desired criteria of being rapid, easy to perform, interpret and reasonably accurate.

**Keywords:** Malaria, Microscopy, Rapid diagnostic test.

**How to Cite This Article:** Shah S, Waris J, Mushtaq H, Khan I, Ali M, Afridi N. Accuracy of Rapid Diagnostic Test for Malaria compared to Microscopy. *Pak Armed Forces Med J* 2022; 72(3): 1099-1102. DOI: <https://doi.org/10.51253/pafmj.v72i3.4804>

This is an Open Access article distributed under the terms of the Creative Commons Attribution License (<https://creativecommons.org/licenses/by-nc/4.0/>), which permits unrestricted use, distribution, and reproduction in any medium, provided the original work is properly cited.

### INTRODUCTION

Malaria is a common parasitic infection and a devastating global health problem. According to the World Health Organization, 228 million malaria cases were diagnosed globally, claiming 405 000 lives in the year 2018.<sup>1</sup> Among them, the highest rates of cases and deaths were reported in Sub-Saharan Africa.<sup>2</sup> In Pakistan, 374,513 (*P. Vivax*: 84.0%, *P. Falciparum*: 14.9%) confirmed malaria cases had been reported.<sup>3</sup>

Malaria provides a diagnostic challenge to the laboratories of mostly resource-poor malaria-endemic areas. According to WHO, the diagnosis of malaria should be established at the earliest before the commencement of treatment.<sup>4</sup>

To avoid complications which may have fatal consequences, timely diagnosis and commencement of treatment are the keys to successful management of malaria.<sup>5</sup> But, to diagnose acute malaria, demonstrating malarial parasites in blood is prudent as no aspect

of the clinical picture is diagnostic of malaria.<sup>6</sup> However, in many poor-resourced endemic countries, clinicians often rely on clinical signs and symptoms for malaria diagnosis, which may lead to the significant over-diagnosis and injudicious prescription of anti-malarial drugs.<sup>7</sup>

Currently, the standard gold method for malaria diagnosis is microscopy, as it remains cost-effective and useful in estimating the level of parasitaemia. But this method is time-consuming, labour-intensive and also requires a trained eye.<sup>8</sup>

Rapid Diagnostic Test (RDT) is simple to perform, has improved the ease of appropriate diagnosis, requires less expertise and has been widely adopted in recent days.<sup>9</sup>

In Pakistan, the research on diagnostic accuracy and cost-effectiveness of RDTs has not been extensively evaluated.<sup>10</sup> Moreover, despite being available for many years, it has not replaced microscopy as a gold standard for diagnosing malaria.<sup>10</sup>

This study was designed to evaluate the diagnostic efficiency of RDTs while keeping microscopy as

**Correspondence:** Dr Imran Khan, Flat No. E4/H, Artillery Road, Peshawar Cantt, Peshawar-Pakistan  
Received: 15 Jul 2020; revision received: 18 Dec 2020; accepted: 21 Dec 2020

a gold standard, to determine the recommendation of the RDTs as an alternate cost-effective screening test and to be adopted by malaria control programs for diagnostic purposes.

**METHODOLOGY**

This cross-sectional study was conducted at the Hematology Department of Pakistan Naval Ship Rahat Hospital, Karachi, from August 2018 to January 2019. Approval to conduct the study was taken from the Ethical Committee of the hospital (reference ERB/PAT/19).

**Inclusion Criteria:** Adult patients of both genders with a history of intermittent moderate to high-grade fever with rigours and having high suspicion of malaria were included in the study.

**Exclusion Criteria:** The study did not include febrile patients with productive cough, diarrhoea, odynophagia, and skin rashes.

One hundred seventy-five patients meeting the inclusion criteria were included in the study. Informed consent was taken from all the included patients. Non-probability consecutive sampling method was employed to select the patients.

WHO calculator was used to determine the sample size, taking sensitivity (74%), specificity (85.5%), prevalence (17.5%), the margin of error d=11% for sensitivity and 10% for specificity and a confidence interval of 95%.<sup>11</sup>

Samples were collected from indoor and outdoor patients with fever and/or clinical suspicion of malaria. 3 ml venous blood was collected in a Tri-potassium ethylene diamine tetra-acetic-acid (EDTA) tube for RDT & microscopy.

For microscopy, thick and thin blood smears were prepared and air-dried. Thin films were stained with Leishman’s stain [0.2 g powder stain dissolved in 100 ml methanol (acetone-free)] for 2 minutes. Diluted with Sorensen’s phosphate buffer pH 7.2

(Potassium Di-hydrogen Phosphate 9.1 g/l, Disodium Hydrogen Phosphate 9.5 g/l, distilled water upto 1 litre) for 10 min. Blood film was examined under a microscope with 40x lens power and Oil-immersion with 100x lens power for the presence or absence of malaria parasites. Thick films were stained for 12 minutes, and an equal quantity of Leishman’s stain and Sorensen’s buffer were used.

For performing the RDT, 5µL of whole blood specimen was poured into the specimen well with the help of a dropper. Then, a buffer (approximately

120uL) was added to the buffer well, and the timer was started. The result was read after 15 minutes.

Patient data and results were recorded in a predesigned proforma. The data were analyzed using Statistical Package for Social Science (SPSS) version 22.0. Mean and standard deviation was calculated for age, while frequency and percentage were calculated for gender. True positive, true negative, false positive, false negative, sensitivity, specificity and diagnostic accuracy were calculated and presented in percentages. The chi-square test was applied after stratification. The p-value ≤0.05 was considered to indicate statistically significant differences.

**RESULTS**

Out of 175 included patients, the distribution of ages varies between 24 and 57 years. The mean age was 39.30 years with a standard deviation of ± 11.29). The frequency distribution of age showed that 54 (30.9%), 36 (20.6%), 51 (29.1%) and 34 (19.4%) patients were in age groups 21-30 years, 31-40 years, 41-50 years and 51-60 years respectively (Figure). The frequency distribution of gender showed that 85 (48.6%) were male and 90 (51.4%) were female.

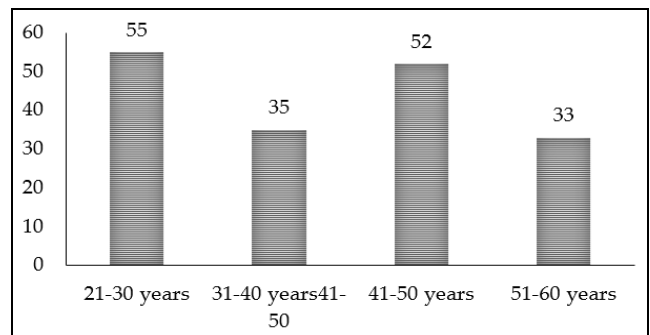


Figure: Histogram show age distribution among the studied patients.

The outcome of microscopy, True positive/negative cases and false positive/negative cases of RDT in comparison with microscopy were shown in Table-I.

**Table-I: Diagnostic accuracy of rapid diagnostic test for malaria keeping microscopy as gold standard (n=175).**

Microscopy	Rapid Diagnostic Test	
	No. of Cases	
Outcome	Positive Cases	Negative Cases
Positive	86 (49%)	75 (True positive) 11 (False negative)
Negative	89 (51%)	23 (False positive) 66 (True negative)

The sensitivity and specificity, positive predictive value; negative predictive value; and diagnostic accuracy of RDT for malaria while considering

microscopy as the gold standard was found to be 87.2%, 74.15%, 67.34%, 85.71% and 80.57%, respectively (Table-II).

**Table-II: Diagnostic accuracy of rapid diagnostic test for malaria keeping microscopy as gold standard.**

Sensitivity	(True Positive/True Positive + False Negative) x 100	87.2%
Specificity	(True negative /True negative + False positive) x 100	74.15%
Positive Predictive Value	(True negative/True positive + False positive) x 100	67.34%
Negative Predictive Value	(True negative/False negative + True negative) x 100	85.71%
Diagnostic Accuracy	(True positive + True negative/Total patients) x 100	80.57%

Stratification for age showed that out of 54 patients in the age group 21-30 years, 30 (55%) and 27 (50%) had positive RDT and microscopy results, respectively. *p*-value was 0.03. Moreover, out of 36 patients in the age group 31-40 years, 20 (55%) and 21 (58.3%) had positive RDT and microscopy results, respectively, (the *p*-value was 0.04). Furthermore, out of 51 patients in the age group 41-50 years, 28 (54.9%) and 25 (49%) had positive RDT and microscopy results, respectively (*p*-value was 0.0). Finally, out of 54 patients in the age group 51-60 years, 20 (58.8%) and 13 (38.2%) had positive RDT and microscopy results, respectively. The *p*-value was 0.01.

Association with gender showed that 45 (52.94%) and 38 (44.70%) in the male gender had positive RDT and microscopy results, respectively; the *p*-value was 0.03. While 53 (58.88%) and 48 (53.33%) in the female gender had positive RDT and microscopy results, the *p*-value was 0.04.

**DISCUSSION**

In this study, 175 patients were included. Results for the diagnostic accuracy of the rapid diagnostic test for malaria were determined while keeping microscopy as a gold standard.

The sensitivity of RDT was 87.2%, specificity was 74.15%, positive predictive value was 67.34%, negative predictive value was 85.71%, and diagnostic accuracy was found to be 80.57%. The result of this study showed that the accuracy of the RDT method is statistically significant in all adult age groups (*p*-value <0.05)

Jang *et al*, compared three commercial RDT and ELISA with PCR and microscopy positive cases. Their results showed 100% specificity of the ELISA-based method and 85.5%, 86.8%, and 86.8% sensitivity with

OPTIMAL test, SD BIOLINE Malaria Antigen (Ag) Pf/Pan test, and Humasis Malaria Pf/Pan antigen test, respectively.<sup>12</sup> The high specificity of RDTs is comparable with the findings of our study.

Mallepaddi *et al*, compared the PCR results for malarial parasites with microscopy and Malarial Ag rapid kits and malarial Antibodies (Ab) rapid kits. Overall the microscopy and malaria antigen-based lateral flow assay exhibited similar sensitivity, specificity, PPV, NPV and efficiency; their results are comparable with our study.<sup>13</sup>

A study in Kenya conducted in 2016 showed that in comparison to microscopy, the sensitivity of eight RDTs to detect malaria parasites was 90.3–94.8 %, and the specificity was 73.3–79.3 %.<sup>14</sup>

Ojurongbe *et al*, compared PCR, thick film microscopy and RDTs to detect Malarial parasites. In their study, RDT had a sensitivity of 62.3% and specificity of 87.4%, which is comparable with our study.<sup>15</sup> In a meta-analysis Zhu *et al*, also concluded that the Rapid diagnostic tests have high accuracy for diagnosing malaria in children.<sup>16</sup>

Garba *et al*, found higher positivity rates for microscopy than for RDT, with a low sensitivity of 9.09%.<sup>17</sup> Elechi *et al*, found a very low sensitivity of 8.3% of RDT compared to microscopy.<sup>18</sup> The result of these studies are not in agreement with our results. The subjects they included in their studies were under five years of age. In those studies, the author concluded that the immune response in children is yet to develop; therefore, the sensitivity to RDTs increases with age. This factor has led to the discrepancy between these studies and our one.

Ahmed *et al*, in their study, concluded that the PCR method is preferred over Microscopy and rapid methods in populations with low transmission of the malarial parasite but with moderate transmission intensities. All three methods have potential significance.<sup>19</sup>

This study has shown that the accuracy of RDT for diagnosing malaria is comparable with microscopy. It can be used as a reliable method where the disease brunt is high and positive Cases may be overlooked if relied on microscopy alone.

PCR is an alternate and highly specific method for malaria diagnosis. Nevertheless, being an expensive modality, it is impossible to carry out this test on a routine basis in a developing country with meagre health resources.

RDTs can be used as an alternative to microscopy in field areas and resource-constrained settings where expertise for microscopy is unavailable due to the dearth of skilled personnel. It is an economical and easy-to-use method without the need for specialized equipment. Moreover, it may help decrease the practices of offering presumptive malaria treatment in febrile patients without confirming the diagnosis.

### LIMITATIONS OF STUDY

The small sample size was the limitation of this study. In order to formulate a guideline for replacing Microscopy with the RDT method, larger data is needed. Nevertheless, this study will support other data with similar prospects. In order to design specific policies regarding the use of RDT, further studies with a larger sample size are recommended.

### CONCLUSION

Rapid immune-capture tests can have excellent applicability in malaria diagnosis. Field workers can reliably read such tests without any supervision. It appears to satisfy the desired criteria of being rapid, easy to perform, interpret and reasonably accurate.

**Conflict of Interest:** None.

### Author's Contribution

SS: Data collection, JW: Review of literature, HM: Manuscript writing, IK: Statistical analysis, MA: Charts and tables preparation, NA: Critically reviewed the article.

### REFERENCES

1. World malaria report 2019. World Health Organization. 2020 [Internet] available at: <http://www.who.int/malaria/publications/world-malaria-report-2019/en/> [Accessed on May 5, 2021].
2. Fact sheet about Malaria Who.int. 2020. [Internet] available at: <https://www.who.int/news-room/fact-sheets/detail/malaria> [Accessed on May 5, 2021].
3. Directorate of Malaria Control. Pakistan malaria annual report 2019. [Internet] available at: <http://dmc.gov.pk/> [Accessed on July 27, 2020].
4. World Health Organization. (2015). Guidelines for the treatment of malaria, 3rd ed. [Internet]. available at: <https://apps.who.int/iris/handle/10665/162441> [Accessed on May 5, 2021].
5. Ayogu E, Ukwe C, Nna E. Assessing the reliability of microscopy and rapid diagnostic tests in malaria diagnosis in areas with varying parasite density among older children and adult patients in Nigeria. *J Postgrad Med* 2016; 62(3): 150-156. doi: 10.4103/0022-3859.183167.
6. Sajjad M, Khan ZA, Akram M. Blood Morphology of Patients Suffering from Malaria. *J Islam Int Med Coll* 2015; 10(4): 251-255.
7. Leslie T, Mikhail A, Mayan I, Anwar M, Bakhtash S, Nader M, et al. Over diagnosis and mistreatment of malaria among febrile patients at primary healthcare level in Afghanistan: observational study. *BMJ* 2012; 345: e4389 doi: <https://doi.org/10.1136/bmj.e4389>.
8. Leski T, Taitt C, Swaray A, Bangura U, Reynolds N, Holtz A, et al. Use of real-time multiplex PCR, malaria rapid diagnostic test and microscopy to investigate the prevalence of Plasmodium species among febrile hospital patients in Sierra Leone. *Malar J* 2020; 9(1):84.
9. Singh N, Sharma R. Improving diagnosis and treatment of uncomplicated malaria. *Lancet Glob Health* 2014; 2(6): 304-305.
10. Shaikh S, Memon S, Memon H, Ahmed I. Role of rapid diagnostic tests for guiding outpatient treatment of febrile illness in Liaquat University Hospital. *Pak J Med Sci* 2013; 29(5): 1167-1172. doi: 10.12669/pjms.295.3937.
11. Singh N, Shukla MM, Mehra RK, Sharma S, Bharti PK, Singh MP, et al. Field and Laboratory comparative evaluation of rapid malaria diagnostic tests versus traditional and molecular techniques in India. *Malar J* 2010; 9(1): 191.
12. Jang JW, Cho CH, Han ET. pLDH level of clinically isolated Plasmodium vivax and detection limit of Pldh based malaria rapid diagnostic test. *Malar J* 2013; 12: 181.
13. Mallepaddi P, Maity S, Poonati R, Pyadala N, Polavarapu R, Mangamuri U, et al. Selecting better diagnostic kits for diagnosis of malarial parasites at point of care. *3 Biotech* 2019; 9(1): 36. doi: 10.1007/s13205-018-1566-7.
14. Wanja EW, Kuya N, Moranga C, Hickman M, Johnson JD, Moseti C, et al. Field evaluation of diagnostic performance of malaria rapid diagnostic tests in western Kenya. *Malar J* 2016; 15(1): 456.
15. Ojuronbe O, Adegbosin OO, Taiwo SS, Alli OA, Olowe OA, Ojuronbe TA,, et al. Assessment of clinical diagnosis, microscopy, rapid diagnostic tests, and polymerase chain reaction in the diagnosis of plasmodium falciparum in Nigeria. *Malar Res Treat* 2013; 2013: 308069. doi: 10.1155/2013/308069.
16. Zhu W, Ling X, Shang W, du Y, Liu J, Cao Y, et al. High value of rapid diagnostic tests to diagnose malaria within children: A systematic review and meta-analysis. *J Glob Health* 2020; 10: 010411. doi: 10.7189/jogh.10.010411
17. Garba B, Muhammad A, Musa A, Edem B, Yusuf I, Bello N, et al. Diagnosis of malaria: A comparison between microscopy and rapid diagnostic test among under-five children at Gusau, Nigeria. *Sub-Saharan Afr J Med* 2016; 3(2): 96-101. doi: 10.4103/2384-5147.184371
18. Elechi H, Rabasa A, Bashir M, Gofama M, Ibrahim H, Askira U. Uncomplicated malaria in children: The place of rapid diagnostic test. *Niger J Med* 2015; 56(2): 85-90. doi: 10.4103/0300-1652.150686.
19. Ahmed R, Devnath K, Bhowmik D, Sharma I. High-sensitivity detection of human malaria parasites by the use of rapid diagnostic tests and nested polymerase chain reaction in burdened communities of North East India. *Indian J Med Microbiol* 2018; 36(4): 541-546.