

## Role of Percutaneous Bone Marrow Aspirate in the Management of Femoral Delayed Union and Non Union Fractures

Muhammad Rehan Saleem, Rana Shahbaz Ahmad, Shahzad Inam, Adnan Anwer, Osma Jafar, Hassan ud Din Hassan

Department of Orthopedics, Combined Military Hospital/National University of Medical Sciences (NUMS) Rawalpindi Pakistan

### ABSTRACT

**Objective:** The objective of the study is to radiologically ascertain bone union following percutaneous autologous bone marrow aspirate injection in the management of delayed union and non-union fractures of femur.

**Study design:** Case series.

**Duration and place of Study:** Department of Orthopedics, Combined Military Hospital, Rawalpindi Pakistan, from Jan to Jun 2019.

**Methodology:** Forty-two (42) patients of fracture femur who fulfilled the inclusion criteria were enrolled in the study. Fresh radiographs of affected side were performed to document cases of delayed union and nonunion. 50ml of bone marrow aspirate from iliac crest was injected at fracture site. Results were evaluated after 12 weeks with the help of radiographs to see radiological union of bone.

**Results:** A total of 42 patients were included in the study. 37(88.09%) were males and 5(11.9%) were females between the ages of 18 and 60 years. The mean age of patients was calculated to be 34.80±11.17 years. Radiological union was achieved in 32(76.19%) patients.

**Conclusion:** Radiological assessment shows percutaneous injection of bone marrow as a safe procedure with bone healing in 12 weeks in patients with non-union or delayed union.

**Keywords:** Delayed union, Non-union.

**How to Cite This Article:** Saleem MR, Ahmad RS, Inam S, Anwer A, Jafar O, Hassan HUD. Role of Percutaneous Bone Marrow Aspirate in the Management of Femoral Delayed Union and Non Union Fractures. Pak Armed Forces Med J 2023; 73(Suppl-1): S274-276. <https://doi.org/10.51253/pafmj.v73iSUPPL-1.4749>.

This is an Open Access article distributed under the terms of the Creative Commons Attribution License (<https://creativecommons.org/licenses/by-nc/4.0/>), which permits unrestricted use, distribution, and reproduction in any medium, provided the original work is properly cited.

### INTRODUCTION

Issues of delayed and non-union of fractures of long bones are a nightmare for the orthopedic surgeons despite revolutionary advancements which have taken this field by storm. Bhargava *et al.* mentions the use of autologous bone grafting from cancellous bone for the stimulation of skeletal repair dating fifty years back.<sup>1</sup> The benefits stand recognized for more than a century now. Albeit, this surgical bone harvesting with fracture site implantation is not without complications. According to Boyd, "bone marrow is primarily a second wounding procedure in which surgeon hopes that the response of the body will be more favorable than the response following the original injury".

Use of bone marrow as an osteogenic source without surgical intervention is a novel technique. It has shown promising results of 90 % radiological union in 12 weeks in femoral delayed as well as nonunion.

Use of percutaneous bone marrow injection in the

outdoor setting can have multifaceted advantages viz a viz reduced inpatient waiting times for surgery, reduced stress and a significant drop in off work period leading to early return to activities of daily living.

### METHODOLOGY

The study was carried out at Department of Orthopedics Combined Military Hospital, Rawalpindi Pakistan from January to June 2019. Permission was taken from the Ethical committee of the hospital (Ltr no. 17/11/19).

**Inclusion Criteria:** Patients of either gender between the ages of eighteen (18) and sixty (60) years who had closed femoral diaphysial fractures with delayed or non-union, were included.

**Exclusion Criteria:** Patients with vascular or nerve injury, skin and soft tissue infections, infective non-union, pregnancy or previous history of bone grafting were not included in the study.

Written consent was obtained from the enrolled patients after explaining the procedure, risks and benefits in the language they understood. Demographic data including hospital number, name, gender, address and phone number were noted. Radiographs

**Correspondence:** Dr Muhammad Rehan Saleem, Classified Surgeon, Combined Military Hospital, Rawalpindi Pakistan

Received: 08 Jul 2020; revision received: 20 Dec 2020; accepted: 10 Jan 2023

of affected side were performed in anteroposterior and lateral projections including hip and knee joints. These were blindly reported by the Department of Radiology. All patients were kept nil per oral 6 hours before the injection/procedure. They were given a single dose of preoperative 2nd generation cephalosporin. After all necessary aseptic measures, site of delayed or non-union were localized under image intensifier. Bone marrow aspiration was done from the iliac crest. 50ml then injected at recipient fracture area using technique described by Hernigou. All procedures were performed by the same team. Post operatively compression bandage was applied for two days. Patients were encouraged to bear full weight after the procedure.

Patients were followed up in outpatient department. Fresh radiographs were taken. Results of procedure were evaluated at the end of 12 weeks after procedure. The patients were considered to have radiological union of the fracture when there was a radiographic evidence of cortical bone or bone trabeculae crossing the site of the fractured bone. Age, delayed and non-union were addressed using stratification. All this information was collected through specially designed proforma.

The data was analyzed using SPSS 20. Mean and standard deviation was calculated for quantitative variables like age. For all qualitative data, frequency and percentages were calculated (including gender and bone union). *p*-value <0.5 was taken as significant.

**RESULTS**

42 patients [37 males, 5 females] with ages ranging from 18-60 years were included in this study. Mean age of the study population was 34.80±11.17 years. Table-I shows the age group wise distribution of patients with reference to non-union and delayed union of fractures. Frequency of results obtained in non-union versus delayed union of fractures is represented by a bar diagram in Figure. Out of 42 patients, 29(69.04%) were of femoral non-union and 13(30.95%) patients were of femoral delayed union. Radiological evidence of union was seen in 32(76.19%) patients and radiological union was not achieved in 10(23.8%). Out of 13 patients of delayed union, radiological union was achieved in 11(84.61%) patients and was not achieved in 2(15.38%) patients. Out of 29 patients of non-union, radiological union was achieved in 21(72.41%) with non-union was achieved in 8 (27.59%) patients. No single patient developed subcutaneous or deep hematoma, nerve injury,

infection or fat embolism after the procedure in early or late period (Table).

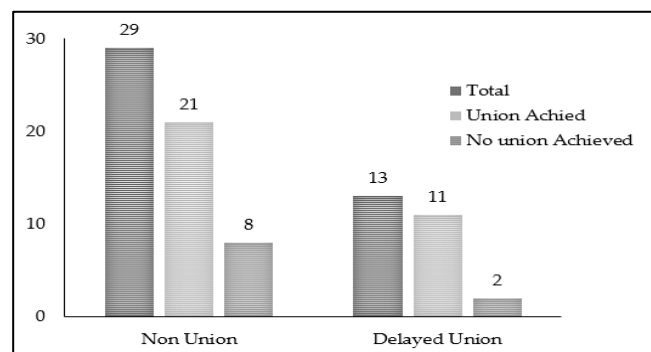


Figure: Results achieved in Non Union versus Delayed Union Patients (n=42)

Table: Age Wise Distribution and Union (n=42)

Age groups (in years)	Number of Patients	Union Achieved	Union Not Achieved	<i>p</i> -value
18-20	5	4(80%)	1(20%)	<0.5
21-30	12	10(83.3%)	2(16.66%)	<0.5
31-40	14	12(85.71%)	2(14.28%)	<0.5
41-50	9	4(44.44%)	5(55.55%)	<0.5
51-60	2	2(100%)	0	<0.5
18-60	42	32(76.19%)	10(23.8%)	<0.5

**DISCUSSION**

A number of interventions ranging from invasive e.g. cortico-cancellous bone grafting to non-invasive modalities e.g., bone marrow injection, stimulation by direct current through implanted electrodes, ultrasound therapy and pulsed electromagnetic field around the site of fracture have been documented over time for the management of delayed and nonunion of long bones.

Although all of these techniques showed different degrees of results (from good to excellent) but come at the extended arms of expertise, use of expensive equipment and exposure to anesthesia. The only therapeutic intervention performed in present study was percutaneous autologous bone marrow injection. The same I/M I/L nail or fracture brace was continued as it was before procedure. There were 42 closed fracture femurs which were studied; all closed fractures had undergone definitive fracture fixation at our institute or other centers before they underwent bone marrow injection.

Most of the patients (32 out of 42) in present study presented after 11 months of injury. This was comparable to studies by Siwach *et al.* Hernigou *et al.* and Powel *et al.* where mean delays of 11.6 months, 12

months and 05 months between injury and bone marrow injection have been documented.

We used 50ml of percutaneous bone marrow without concentration at delayed union or nonunion site only once as done by Connolly *et al.* Healy *et al.* injected 50ml of marrow without concentration. 4 out of them were injected only once and other 4 were injected twice. Garg *et al.* injected 15-20 ml of bone marrow at fracture site twice at three weekly intervals without concentration. Siwach *et al.* used 30ml of autologous bone marrow without concentration in 72 patients. They repeated injection twice with interval of 4 weeks. Bone marrow injection was not repeated in comparison to other studies owing to the short study period.

In our present study, bone marrow injection was injected without concentration due to limitation of resources. However, it has been postulated that increasing concentration of marrow increases its osteogenic activity. Hernigou *et al.* used 20 ml concentrated bone marrow at fracture site in 60 patients with significant influence. And subsequently suggested that graft needs to contain > 1000 progenitors per cm<sup>3</sup> to affect result significantly.

Healing time at 12 weeks (9-12 weeks) after intraosseous injection of autologous bone marrow in the present study was comparable to other studies conducted both locally and internationally. This was 12 weeks and 14 weeks respectively in studies by Hernigou *et al.* and Siwach *et al.*

In present study radiological union was achieved in 32(76.19%) out of 42 patients after bone marrow injection in study duration of 6 months. In study by Siwach *et al.* radiological union was achieved in 68 out of 72 patients (94.44%) in study duration of 7 years. In study by Hernigou *et al.* radiological union was achieved in 53 out of 60 patients (88.30%) in study duration of 10 years. In study by Bhargava *et al.* radiological union after bone marrow injection was achieved in 23 out of 28 patients (82.14%) in study duration of 2 years. In study by Powel *et al.* radiological union was achieved in 28 out of 37 patients (75.67%) in study duration of 5 years. In study by Healy *et al.* radiological union was achieved in 5 out of 8 patients (62.5%). Percentage of radiological union achieved in present study is inferior to other studies carried out locally and abroad. Out of these nine patients comprising failure of union at the end of study, six patients had their fracture distracted with I/M I/L nail in place and ultimately they had to

undergo bone grafting for their fractures. Two patients underwent open redo fixation with I/M I/L nail as the initial implant was B-DCP with resultant loss of fracture fragments and one patient had comminuted fracture with displaced fracture fragments with I/M I/L nail in place and he also had to undergo bone grafting to achieve union. Five patients were tobacco users and three had diabetes mellitus.

Present study showed that percutaneous autologous bone marrow injection is a treatment for non-infected delayed and nonunion of long bones as no patient reported back with chronic pain at recipient or donor site, nerve injury, infection or hematoma formation as local complications. There was also no case with fat embolism as systemic complication in present study. In studies by Siwach *et al.* Hernigou *et al.* and Powel *et al.* no local or systemic complication was identified. Only in study by Bhargava *et al.* 6 out of 28 patients reported chronic pain at the recipient site which settled in 2-3 weeks with reassurance and mild analgesia. All studies including the present study proved the safety of the autologous bone injection.

### CONCLUSION

Percutaneous bone marrow autologous grafting is an effective outpatient technique for the management of non-infected delayed and non-union of long bones. It provides cellular reactivation of bone formation with minimal complications.

**Conflict of Interest:** None.

### Author's Contribution

Following authors have made substantial contributions to the manuscript as under:

MRS: & RSA: Study design, drafting the manuscript, data interpretation, critical review, approval of the final version to be published.

SI: & AA: Data acquisition, data analysis, approval of the final version to be published.

OJ: & HUDH: Critical review, concept, drafting the manuscript, approval of the final version to be published.

Authors agree to be accountable for all aspects of the work in ensuring that questions related to the accuracy or integrity of any part of the work are appropriately investigated and resolved.

### REFERENCES

1. Bhargava R, Sankhla SS, Gupta A, Changani RL, Galgal KC. Percutaneous autologous bone marrow injection in the treatment of delayed or nonunion. *Indian J Orthop* 2007; 41: 67-71.
2. Tseng SS, Lee MA, Reddi AH. Nonunions and the potential of stem cells in fracture-healing. *J Bone Joint Surg Am* 2008; 90(1): 92-98.
3. Patterson TE, Kumagai K, Griffith L, Muschler GF. Cellular strategies for enhancement of fracture repair. *J Bone Joint Surg Am* 2008; 90(1): 111-119.

## Role of Percutaneous Bone Marrow Aspirate

4. Jones E, McGonagle D. Human bone marrow mesenchymal stem cells in vivo. *Rheumatol* 2008; 47(1): 126-131.
5. Suzanne A, Maher, Chisa H, Matthew E, Cunningham, Scott AR, et al. What's new in orthopaedic research. *J Bone Joint Surg Am* 2006; 88(1): 2314-2321.
6. Long WGD, Einhorn TA, Koval K, McKee M, Smith W. Bone grafts and bone graft substitutes in orthopaedic trauma surgery. *J Bone Joint Surg Am* 2007; 89(1): 649-658.
7. LaVelle DG. Delayed union and nonunion of fractures. In: Canale ST, Daugherty K and Jones L, editors. *Campbell's operative orthopaedics*. 10th ed. Philadelphia, Pennsylvania 19106: Mosby Elsevier;2003; (1): 3125-3157.
8. Malik HR, Aslam E, Zeeshan M, Shami A. Role of percutaneous bone marrow aspirate injection in delayed union of femur and tibia diaphyseal fractures. *J Rawal Med Uni* 2018; 22(1): 210-214.
9. Gates CB, Karthikeyan T, Fu F, Huard J. Regenerative medicine for the musculoskeletal system based on muscle derived stem cells. *J Am Acad Orthop Surg* 2008; 16(1): 68-76.
10. Soucacos PN, Dailiana Z, Beris AE. Vascularised bone grafts for the management of non-union. *Injury* 2006; 37(1): 41.
11. Hernigou PH, Poignard A, Manicom O. Use of percutaneous autologous bone marrow transplantation in non union and avascular necrosis of bone. *J Bone Joint Surg Br* 2005; 87(1): 896-902.
12. Siwach RC, Sangwan SS, Singh R, Goel A. Role of percutaneous bone marrow grafting in delayed unions, non-unions and poor regenerates. *Indian J Med Sci* 2001; 55(1): 326-336
13. Hernigou PH, Poignard A. Percutaneous bone marrow grafting for non unions. Influence of concentration and number of progenitor cells. *J Bone Joint Surg Am* 2005; 87(1): 1430-1437.
14. Reichert P, Rutowski R, Gosk J, Zimmer K, Skiba K. Treatment of delayed union of long bones by percutaneous injection of autologous stem cells. *Adv Clin Exp Med*. 2007; 16(1): 43-48.
15. Healy JH, Zimmerman PA, McDonnel JM. Percutaneous bone marrow grafting of delayed union and non-union in cancer patients. *Clin Orthop* 1990; 256(1): 281-285.
16. Verma N, Singh MP, Haq RU, Rajesh K, Rajnish R. Outcome of bone marrow instillation at fracture site in intracapsular fracture of femoral neck treated by head preserving surgery. *Chinese J Traumatol* 2017; 20(4): 222-225. [https://doi: 10.1016/j.cjtee.2017.02.003](https://doi.org/10.1016/j.cjtee.2017.02.003).
17. Garnavos C. Treatment of aseptic non-union after intramedullary nailing without removal of the nail. *Injury* 2017; 48(S1): S76-S81. [https://doi: 10.1016/j.injury.2017.04.022](https://doi.org/10.1016/j.injury.2017.04.022).
18. Markel MD, Seeherman H. Biologic Agents to Enhance Fracture Healing. *Equine Fracture Repair* 2019; 12(2). <https://doi.org/10.1002/9781119108757.ch12>
19. Kostenuik P, Mirza FM. Fracture healing physiology and the quest for therapies for delayed healing and nonunion. *J orthop Res* 2017; 35(2); 213-223. [https://doi: 10.1002/jor.23460](https://doi.org/10.1002/jor.23460).
20. Mannelli G, Arcuri F, Conti M, Agostini T, Raffaini M, Spinelli G, et al. The role of bone marrow aspirate cells in the management of atrophic mandibular fractures by mini-invasive surgical approach. *Journal of Cranio-Maxillofacial Surg* 2017; 45(5); 694-703. [https://doi: 10.1016/j.jcms.2017.01.007](https://doi.org/10.1016/j.jcms.2017.01.007).
21. Ducharme NG, Nixon AJ. Delayed union, nonunion, and malunion. biologic agents to enhance fracture healing. *Equine Fracture Repair* 2019; 12(2). 623-628. [https://doi:10.15514425312/wjo.v6.i8.623](https://doi.org/10.15514425312/wjo.v6.i8.623)