

OUTCOME OF RETROGRADE FLEXIBLE INTRAMEDULLARY NAILING IN FEMORAL DIAPHYSEAL FRACTURES OF CHILDREN

Aamir Shabab, Mumtaz Hussain*, Muhammad Imran**, Sana Ali Shah**

Services Institute of Medical Sciences, Lahore Pakistan, *Children Hospital, Lahore Pakistan, **Jinnah Hospital, Lahore Pakistan

ABSTRACT

Objective: To evaluate the results of flexible intramedullary nailing in terms of postoperative leg length discrepancy and post operative pain during fracture resolution.

Study Design: Case series.

Place and Duration of Study: Department of Orthopedic Surgery, Jinnah Hospital Lahore, from Jan 2014 to Dec 2014.

Methodology: One hundred and twenty patients (95 boys, 25 girls) having close fractures of femur diaphysis, between age of 5 to 9 years old were stabilized with titanium elastic nails system. Flynn *et al* scoring criteria was used to evaluate the outcome in terms of leg length discrepancy and visual analogue score for postoperative pain.

Results: All patients were evaluated at 8 weeks for postoperative leg pain and leg length discrepancy (LLD). Excellent results (LLD <1cm) were found in eighty nine (89) patients (74.2%) and successful results (LLD <2cm) were found in thirty one (31) patients (25.8%). No patient was found to have a leg length discrepancy >2cm. Fifty four (54) patients (45.00%) had no pain using visual analogue scale (VAS score 0), forty three (43) patients (35.83%) had mild pain (VAS score 1-3), sixteen (16) patients (13.33%) had moderate pain (VAS score 4-6) and seven (7) patients (5.83%) had severe pain (VAS score 7-10) as shown in figure.

Conclusion: Titanium elastic nailing system is a simple, internally placed splint that acts as load sharing device, respects physis, restores alignment and allows early mobilization. It is preferred treatment in age group (5-9 years) and seems advantageous over other surgical methods.

Keywords: Femoral diaphyseal fractures, Leg length discrepancy, Postoperative leg pain, Titanium elastic nailing system, Visual analogue score.

This is an Open Access article distributed under the terms of the Creative Commons Attribution License (<http://creativecommons.org/licenses/by/4.0>), which permits unrestricted use, distribution, and reproduction in any medium, provided the original work is properly cited.

INTRODUCTION

Pediatric femur fractures are uncommon but involve high energy trauma that mandates emergency department admissions and long period of rehabilitation. These fractures represent only 2% of all other pediatric fractures with an annual incidence of around 19 per 100,000^{1,2}. Boys in their early years of life frequently sustain these kinds of injuries³. Simple falls and road traffic accidents are commonly documented mechanisms of injury.

There are various modes of management of these fractures ranging from Thomas spint, immediate spica cast, delayed spica cast, plate osteosynthesis, external fixation to close intra-

medullary fixation⁴. The best treatment option for a particular patient depends on age, fracture configuration, level but the importance of regional, institutional or surgeons' preferences cannot be underestimated⁵.

The surgeons from Nancy, France were first to describe the technique of Titanium Elastic Nails (TENS). Now it is commonly recommended treatment for pediatric femur fractures. The reported outcome of this technique is exceptional, which is also called "elastic stable intramedullary nailing", "flexible intramedullary nailing" or "Nancy nailing".

The technique of TENS entails retrograde insertion of one or more nails through the distal metaphysis into the medullary canal. Biomechanically, it is not rigid fixation but permits micromotions at fracture site to encourage secondary healing. The growth arrest is not a

Correspondence: Dr Aamir Shabab, House No. 31, Block-A Iqbal Avenue, Phase-3, Lahore Pakistan

Email: drorthopedics2016@gmail.com

Received: 01 Jan 2019; revised received: 28 Nov 2019; accepted: 30 Dec 2019

concern in this technique because entry point avoids physis.

TENS has become the ideal choice of treatment in pediatric long bone fractures. Early ambulation and swift return to daily life activities decrease morbidity and hasten recovery as compared to non-operative techniques. Percutaneous placement with small scars at entry points contributes to cosmesis and less soft tissue disruption.

We report a research article with an objective of evaluation of flexible intramedullary nailing in terms of postoperative pain and leg length discrepancy (LLD).

METHODOLOGY

In this case series, 120 patients with close femoral diaphyseal fractures were selected by non probability consecutive sampling technique. The sample size was calculated using 95% confidence interval, 8% margin of error with an expected percentage of pain 27% post-operatively. After informed consent, these patients were treated with TENS, between Dec 2013 and Dec 2014 in Jinnah Hospital Lahore. All these fractures were in middle one third of femur. Patients with open fracture, bilateral femur fractures, associated injuries and inability to comply with 1 year follow up were excluded from study.

The surgery was performed under general anesthesia in supine position. After close reduction of fracture under fluoroscopic guidance, two retrograde nails of identical diameter were passed through 1-2cm incisions made above distal femur physis. The diameter of individual nail was determined by formula (internal diameter of medullary canal/2)-0.5cm. The tip of individual nail to fracture site distance was measured and nails were pre-bent up-to 30° degree in order to get the fracture reduction through elastic recoil of nails. The rods generally used were 2.5-4mm in diameter. After rods were passed and fracture was reduced, rods were withdrawn about 2cm and cut in such a way that only 1cm stays outside the distal femoral metaphysis in order to prevent

bursa formation and soft tissue impingement at nails ends.

Postoperatively knee immobilizer was used in most patients. Some patients with long oblique and spiral unstable fractures were stabilized with cylinder cast. As soon as patient was comfortable, toe-touch weight bearing was started. Full weight bearing was started at 6 weeks.

All patients were evaluated for postoperative pain and LLD at 8 weeks. Statistical analysis was done using SPSS version 17.0 to evaluate postoperative leg pain using visual analogue scale (VAS) score and LLD using Flynn *et al* scoring criteria. LLD was measured in cm and VAS score was measured in percentages.

Nails were removed 6-12 months after surgery when fracture line was not visible radiologically. LLD <1cm was seen in 89 patients, while LLD <2cm was seen in 29 patients. LLD >2cm was not seen in any patient. Postoperative pain was seen in 66 patients, whereas 54 patients had no postoperative pain.

RESULTS

Our study included 120 cases of pediatric femur diaphysis fracture between the age of 5 to 9 years. Mean age of patients was 7.4 ± 1.4 years. There were 95 males (79.17%) and 25 females (20.83%) with male to female ratio (M:F) of 3.80:1. Regarding the side of femur fracture, right sided femur diaphysis fracture was present in sixty one patients (50.83%) and left side femur diaphysis fracture was present in fifty nine patients (49.17%). LLD had a mean \pm SD of (0.75 ± 0.27 cm) as shown in table-I. The minimum value of LLD was (0.40cm) with maximum value up to (1.6cm). Flynn *et al* scoring criteria was used to assess the LLD as shown in table-II. Excellent results (LLD <1cm) were found in eighty nine patients (74.2%) and successful results (LLD < 2cm) were found in thirty one patients (25.8%). No patient was found to have a LLD > 2cm.

Postoperative pain was assessed using VAS score. Fifty four (54) patients (45%) have no pain (VAS score 0), forty three (43) patients (35.83%)

have mild pain (VAS score 1-3), sixteen (16) patients (13.33%) have moderate pain (VAS score 4-6) and seven (7) patients (5.83%) have severe pain (VAS score 7-10) as shown in figure. VAS

Another treatment option in children is plate osteosynthesis which involves extensive soft tissue dissection, prolonged period of splintage, delayed weight bearing and revision surgery for

Table-I: Statistical values of leg length discrepancy and visual analogue score score.

Statistical Values	Leg Length Discrepancy (LLD)	Postoperative Pain (VAS Score)
n	120	120
Mean ± SD	0.75 ± 0.27	1.72 ± 2.30

Table-II: Flynn *et al* criteria¹.

Leg length discrepancy	Excellent <1cm	Successful <2cm	Poor >2cm
Sequence disorder	50	100	150
Pain	Absent	Absent	Present
Complication	Absent	Mild	Major complication and/or extended period for resolvable morbidity

score had a mean of (1.72 ± 2.30) with minimum and maximum values of 0.00 and 10.00 respectively as shown in table-I.

Out of 120 patients, 54 patients had no postoperative pain. Among these patients, 37 patients (68.5%) had LLD <1cm and 17 patients (31.5%) had LLD <2cm. It means that only 37 patients had excellent results and 17 patients had successful results. Regarding the sixty six (66) patients who had postoperative pain, 52 patients (78.8%) had LLD<1cm and 14 patients (21.2%) had LLD <2cm.

Out of 89 patients who had LLD <1cm, 37 patients (41.6%) had no pain and 52 patients (58.4%) had pain. LLD <2cm was found in 31 patients, out of which 17 patients (54.8%) had no pain and 14 patients (45.2%) had postoperative pain.

DISCUSSION

The treatment of pediatric femur fractures had always been a challenge to the orthopedics fraternity. In children and adolescents, conservative treatment had been the treatment of choice for femoral diaphysis fractures. In a comparative study by Reeves *et al*⁶ and Kirby *et al*⁷ demonstrated that intramedullary fixation is a better technique for femur fractures than traction and casting. In the last two decades, operative treatment has gained popularity due to early mobilization, early return to recreational activities and better nursing care.

plate removal^{6,8}. Open femoral diaphysis fractures are treated with external fixator for initial stability and soft tissue management, but pin track infection and delayed weight bearing are potential risks with external fixation^{9,10}. For pediatric femoral fractures, intramedullary K-wire fixation has also been used. But disadvantages associated with this are lack of stability and fracture angulation.

In skeletally mature patients, Interlocking

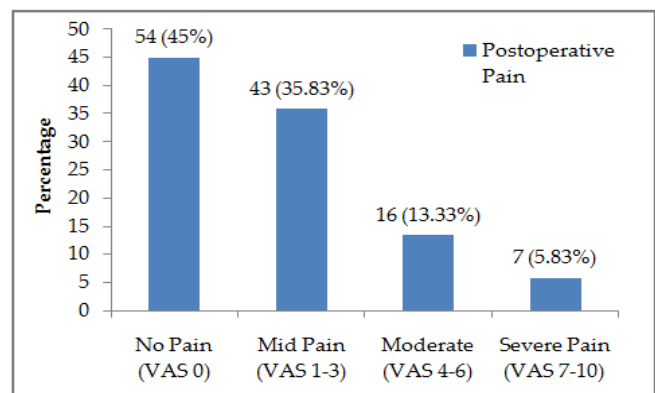


Figure: Postoperative pain assessment using visual analogue score score.

nail is ideal treatment as it controls angulation and rotational instability along with translation. Coxa valga and avascular necrosis of femoral head have been reported in skeletally immature patients^{11,12}. However, in patients from 11-16 years age, good results have been reported with interlocking nail with precaution of avoiding the piriformis fossa as entry site.

To our surprise, only 37 patients (30.8%) had excellent results and 17 patients (14.1%) had successful results. All these 54 patients had no postoperative pain and LLD was less than 2cm. Poor results in this study was not allocated to any patient because no patient was found to have LLD more than 2cm. Although postoperative pain was a problem in 66 patients (66%), which is in accordance with Narayanan *et al*¹³ study results, in which 41 out of 71 patients had pain at entry site due to irritation by nail ends. This can be avoided by leaving nail end 1cm outside cortex and in contact with metaphysis.

In a comparison study, 73 patients were operated with TENS either through antegrade or retrograde route by Bourdel *et al*¹⁴, it was found that antegrade approach is associated with less knee problems and early weight bearing. In another study of 25 patients by Carey and Galpin¹⁵, there was not a single case of osteonecrosis and disturbance with growth of proximal femur. In this study, all patients were operated through retrograde approach, but no knee problem was reported in this study patients. Although patients had delayed weight bearing due to postoperative pain at nail entry site or fracture site.

Intramedullary nailing can be done with both stainless steel rods and titanium flexible rods. Steel rods have intrinsic rigidity and these need not to be configured in either C or S pattern. Irrespective of fracture pattern, touchdown weight bearing can be started as demonstrated by Gyaneshwar *et al*¹⁶ in their randomized comparative trial. In this study, all patients were operated through retrograde approach with Nancy nails in C configuration pattern with apex of bend at fracture site and stainless steel rods. One study in literature illustrates that 4mm titanium nails imparts significant torsional stability, irrespective of fracture pattern. Another study depicted that retrograde rods insertion provides more stiffness and resistance to torsional forces as compared to antegrade rods insertion.

Flynn *et al* recommend TENS over hip spica cast for pediatric femur fractures treatment¹⁷. Buechsenschuetz *et al* documented that TENS is superior to traction and casting in terms of scar acceptance, union and overall patient satisfaction¹⁸.

Regarding the efficacy of Ender Nail, Rush Nail or TENS, no comparative study is available. All nails give comparable results. In pediatric femoral diaphysis fractures, poor rotational stability is provided by Ender nail and Rush nail and may require insertion of multiple nails to achieve good stabilisation. Ligier noted that the elasticity and flexibility of Ender nail is not compatible with pediatric fractures¹⁹. Kumar *et al* observed good results in 20 femoral fractures treated with Ender Nail²⁰.

Surgical technique is determined by fracture geometry and the location. Flynn *et al* stated that TENS is viable option for transverse, short oblique and minimally comminuted fractures²¹. In 5-12 years age group, transverse, short oblique, short spiral fractures with minimum comminution were the best indications for TENS according to Narayanan *et al*¹³. Lascombes *et al*²² stated that in all femoral diaphysis fractures of children above six years of age, TENS could be indicated till epiphysis closed except severe type-III open fractures. In comminuted long oblique or spiral fractures, TENS does not provide adequate stability. In such circumstances, alternative mode of treatment should be considered but if it is even contemplated, postoperative immobilization becomes essential. The limitation of study is that it does not take into account configuration of fracture during treatment decision making because it may affect postoperative LLD and VAS score.

CONCLUSION

Titanium elastic nail is a simple, intramedullary splint that acts as load sharing device, respects physis, restores alignment and permits early ambulation. TENS is an excellent treatment modality in femur diaphysis fracture between 5-9 years of age.

CONFLICT OF INTEREST

This study has no conflict of interest to declare by any author.

REFERENCES

1. Flynn JM, Skaggs DL. Femoral shaft fractures. Kasser J, Beaty J. Rockwood and Wilkins' Fractures in Children. Philadelphia: Lippincott Williams & Wilkins; 2010. p. 809-815.
2. Akilapa O. Elastic stable intramedullary nail for paediatric femoral fractures. *Web Med Central Trauma* 2012; 3(5): 1-20.
3. Kocher MS, Sink EL, Blasler RD. Treatment of pediatric diaphyseal femur fracture. *J Am Acad Orthop Surg* 2009; 17(11): 718-25.
4. John A, Dimitios P, Charalampos K, Kristos P, George M. Flexible intramedullary nailing in paediatric femoral shaft fractures. *Clin Trial* 2009; 41(6): 578-82.
5. Wishwanath C, Satheth GS. Surgical outcome of fracture shaft femur in children using flexible intramedullary nailing. *Int J Orthopedic Sci* 2017; 3(3): 1137-51.
6. Reeves RB, Ballard RI, Hughes JL. Internal fixation versus traction and casting of adolescent femoral shaft fractures. *J Pediatr Orthop* 1990; 10(5): 592-5.
7. Kirby RM, Winquist RA, Hansen ST. Femoral shaft fractures in adolescents: a comparison between traction plus cast treatment and closed intramedullary nailing. *J Pediatr Orthop* 1981; 1(1): 193-97.
8. Ward WT, Levy J, Kaye A. Compression plating for child and adolescent femur fractures. *J Paediatr Orthop* 1992; 12(5): 626-32.
9. Aronson J, Torsky EA. External fixation of femur fractures in children. *J Pediatr Orthop* 1992; 12(1): 157-63.
10. Krettek C, Haas N, Walker J, Tschern H. Treatment of femoral shaft fractures in children by external fixation. *Injury* 1991; 22(1): 263-6.
11. Mani KC, Dhirga RC, Parimal A. Paediatric femoral shaft fractures treated by flexible intramedullary nailing. *Chinese J Traumatol* 2015; 18(1): 284-87.
12. Letts M, Jarvis J, Lawton L, Davidson D. Complications of rigid intramedullary rodding of femoral shaft fractures in children. *J Trauma* 2002; 52(3): 504-16.
13. Narayanan UG, Hyman JE, Wainwright AM, Rang M, Alman BA. Complications of elastic stable intramedullary nail fixation of pediatric femoral fractures, and how to avoid them. *J Pediatr Orthop* 2004; 24(4): 363-69.
14. Bourdelat D. Fracture of the femoral shaft in children: advantages of the descending medullary nailing. *J Pediatr Orthop Br* 1996; 5(2): 110-14.
15. Carey TP, Galpin RD. Flexible intramedullary nail fixation of pediatric femoral fractures. *Clin Orthop Relat Res* 1996; 332(1): 110-18.
16. Gyaneshwar T, Nitesh R, Sagar T, Pranav K, Rustagi N. Treatment of pediatric femoral shaft fractures by stainless steel and titanium elastic nail system: A randomized clinical trial. *Chinese J Traumatol* 2016; 19(4): 213-16.
17. Flynn JM, Hresko T, Reynolds RA, Blasler RD, Davidson R, Kasser J. Titanium elastic nails for Pediatric femur fractures: A multicenter study of early results with analysis of complications. *J Pediatr Orthop* 2001; 21(1): 4-8.
18. Buechsenschuetz KE, Mehlman CT, Shaw KJ, Crawford AH, Immerman EB. Femoral shaft fractures in children: traction and casting versus elastic stable intramedullary nailing. *J Trauma* 2002; 53(5): 914-21.
19. Ligier JN, Metaizeau JP, Prévot J, Lascombes P. Elastic stable intramedullary nailing of femoral shaft fractures in children. *J Bone Joint Surg Br* 1988; 70(1): 74-7.
20. Raghu Kumar J, Gutta SH. A clinical study on the surgical management of fracture shaft femur in children and adolescents by using Ender's nail. *Int J Res Orthop* 2016; 2(3): 170-73.
21. Flynn JM, Skaggs DL, Sponseller PD, Ganley TJ, Kay RM, Kellie Leitch KK. The operative management of pediatric fractures of the lower extremity. *J Bone Joint Surg Am* 2002; 84(1): 288-300.
22. Lascombes P, Haumont T, Journeau P. Use and abuse of flexible intramedullary nailing in children and adolescents. *J Pediatr Orthop* 2006; 26(6): 827-34.