

Role of L5 Nerve Root Morphology in Identification of Lumbosacral Transitional Vertebra. Is it a Reliable Indicator?

Sara Khan, Adil Qayyum, Nazia Dildar*, Asma Jabeen**, Salahuddin Baloch*, Ruquiyya Adil

Department of Radiology, Combined Military Hospital Multan/National University of Medical Sciences (NUMS) Pakistan, *Department of Radiology, Combined Military Hospital Kharian/National University of Medical Sciences (NUMS) Pakistan, **Department of Radiology, Combined Military Hospital Abbottabad/National University of Medical Sciences (NUMS) Pakistan

ABSTRACT

Objective: To determine whether L5 nerve root morphology can assist in identification Lumbosacral Transitional vertebra.

Study Design: Cross sectional study.

Place and Duration of Study: Radiology Department, Combined Military Hospital, Multan Pakistan, Apr 2019 to Apr 2020.

Methodology: Patients of both genders, 15 to 50 years age who underwent whole spine MRI were included in the study. Patients were referred from Combined Military Hospital Multan, from neighboring Combined Military Hospitals and Civil. Sagittal and axial T1WS and T2WS were performed along with coronal T2WS/FS sequences. Axial images were assessed for identification of L5 nerve root arising from LV5-SV1 level and hence vertebra was identified as LV5. Correlation was done with sagittal images for presence of Transitional vertebra, further confirmed by counting vertebral bodies from C2 vertebra upto sacrum using cross referencing tool.

Results: A total of 135 patients were included in the study. Out of these, transitional vertebra was confidently labeled in 23 patients by nerve identification method which was confirmed on vertebral counting method. However, in four patients, L5 nerve root morphology was not clear and we had to rely on vertebral counting method for identification of transitional vertebra.

Conclusion: Neuroanatomy and morphology of exiting L5 nerve roots can act as a reliable method for numbering of lumbosacral vertebra and identification of transitional vertebra.

Keywords: L5 nerve root morphology, lumbosacral Transitional vertebra(LSTV), Magnetic resonance imaging.

How to Cite This Article: Khan S, Qayyum A, Dildar N, Jabeen A, Baloch S, Adil R. Role of L5 Nerve Root Morphology in Identification of Lumbosacral Transitional Vertebra. Is it a Reliable Indicator?. Pak Armed Forces Med J 2024; 74(5): 1445-1450. DOI: <https://doi.org/10.51253/pafmj.v74i5.4340>

This is an Open Access article distributed under the terms of the Creative Commons Attribution License (<https://creativecommons.org/licenses/by-nc/4.0/>), which permits unrestricted use, distribution, and reproduction in any medium, provided the original work is properly cited.

INTRODUCTION

Lumbosacral transitional vertebrae (LSTV) are common finding in general population, with a reported incidence of 1-30%, having a wide range of morphological variation.¹ Importance of correct labeling of Lumbosacral Transitional vertebra in pre surgical planning in symptomatic patients cannot be undermined as it is source of morphological variation in neuroanatomy resulting in inaccurate attribution of clinical symptoms to a different spinal level thus leading to intervention at an unintended level.² Accurate identification of Lumbosacral transitional vertebra (referred as LSTV onwards) is important while reporting MRI spine because there are associated clinical implications and manifestations. Transitional vertebrae are controversially associated with Bertolotti's syndrome (source of backpain).^{2,3} Few symptoms include low backache due to the anomalous articulation as a result of abnormal segmentation, spinal instability and neuralgia caused by hypertrophy

of the transverse process causing nerve root compression.⁴

Various anatomical markers like costal facets, aortic bifurcation, Inferior vena cava confluence and psoas major origin etc have been proposed to identify LSTV, however, these are subjected to a higher degree of anatomical variation and none of these has a 100% accuracy.^{4,5} Likewise, some techniques also include the assessment of origin of right renal artery and iliolumbar ligament but none has proved to be reliable indicator. In patients undergoing isolated lumbar spine or low field MRI, task of identifying transitional vertebra becomes more cumbersome in absence of cervicothoracic localizer scans. At present, there is no standardized method to identify LSTV unequivocally.⁶ This problem is of utmost importance in surgical preplanning, as up to 32% of neurosurgeons have reported an event of surgical intervention at unintended level, occurring at least once in their careers.^{7,8}

At present, there is no consensus regarding method for correctly identifying LSTV on MRI. Literature review showed that there is no standardized method to identify LSTV with significant

Correspondence: Dr Sara Khan, Department of Radiology, Combined Military Hospital, Multan Pakistan

Received: 14 May 2020; revision received: 03 Apr 2024; accepted: 28 Jun 2024

precision.⁹ Only limited studies are available previously on role of L5 nerve roots morphology in lumbosacral vertebral numbering. Aim of our study is to establish L5 nerve root morphology can act as a reliable tool in numbering lumbosacral vertebra and identifying LSTV. This will help eliminate the ambiguity and misattribution of symptoms to incorrect spinal level thus improving confident identification of LSTV, especially in patients requiring surgical intervention.

METHODOLOGY

We reviewed cases of whole spine MRI performed at Radiology Department, Combined Military Hospital, Multan Pakistan, from April 2019 to April 2020, after approval of Ethical Committee of Hospital.

Inclusion Criteria: Patients aged 15 to 50 years who had spinal imaging for backache, limb weakness and neurological deficits were included.

Exclusion Criteria: Patients with infection, trauma, congenital block vertebra and previous spinal surgery were excluded.

Sagittal and coronal images including both T1-weighted images (TR/TE, 700/10s) and T2-weighted images (TR/TE,2700/100) were obtained along with Coronal STIR images using 1.5 Tesla MRI machine (Vantage Atlas, Toshiba, Japan). Slice thickness was kept at 4mm with a gap of 0.4mm between slices. This study was commenced after taking approval from Ethical Committee of our institute. No extra financial constraints were put on institution or patients. MRI were reviewed by two senior Radiologists (with experience of 15 and 8 years respectively). The Radiologists were given a small briefing on basic anatomy of lumbar plexus and L5 nerve root morphology. L5 nerve root was identified based on its special morphological and neuroanatomical features and its origin was documented. The corresponding cephalad vertebral level was identified as LV5. Correlation was done with sagittal and coronal scans to determine vertebral counting after labeling L5 vertebra (on axial scans) and presence or absence of transitional vertebra based on nerve morphology method was determined. These findings were then compared with whole spine MRI to determine total vertebral number by counting method, taken as standard and presence or absence of transitional vertebra was documented. MRI whole spine of patients included in the study were evaluated independently by the two consultant radiologists. On sagittal T2WS, vertebrae were counted as follows: CV2

was readily identified and counted upto CV7 to determine cervical vertebrae and further 12 vertebrae were counted caudally to determine thoracic vertebrae. In case of supernumerary ribs, L1 was considered to have rudimentary ribs. Further caudal counting was done to determine lumbar vertebra upto Lumbosacral junction. On sagittal T2WS and Coronal STIR images, patients were classified according to O’Driscoll staging and Castellvi method. L5 nerve root was identified based on these characteristic neuroanatomical features: (1)L5 nerve is thick in caliber, being twice in caliber as compared to size of L4 peroneal branch. (2)L5 is the only nerve which does not branch earlier in its course. (3)The peroneal branch of L4 typically joins L5 nerve root at the level of sacrum.¹⁰ These characteristic features were helpful to identify L5 nerve root, hence corresponding vertebral level was labeled as LV5-SV1 (Figure-1).

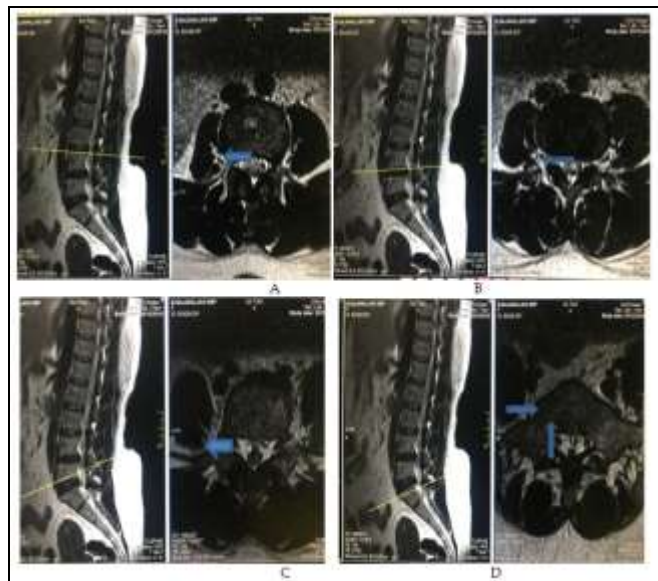


Figure-1: (A-D): Normal Lumbosacral transition. A; L3 nerve roots showing early division immediately after exit from neural foramina, B; L4 nerve root is showing early division into peroneal and tibial components, C; Thick Caliber L5 Nerve exiting at LV5-SV1 level, D; Peroneal branch of L4 Nerve joining thick caliber L5 Nerve along lateral border of Sacrum

Statistical Package for Social Sciences (SPSS) version 23.0 was used for the data analysis. Quantitative variables with normal distribution were expressed as Mean±SD and qualitative variables were expressed as frequency and percentages. Diagnostic parameters were calculated using a 2 x 2 contingency table. Sensitivity, specificity, positive predictive value, negative predictive value and diagnostic accuracy were determined by using the standard formulae.

RESULTS

A total of 135 patients were included in our study, fulfilling the inclusion criteria, who underwent whole spine MRI from April 2019 to April 2020. There were 106 males (78.5%) and 29 females (21.5%). Mean age of females was 44.21 ± 9.26 years and males are 41.27 ± 8.97 years, with minimum age 18 years and maximum age 80 years. Out of total patients, 23 patients (17.0%) were found to have LSTV (in accordance with general population incidence of 1-30%) based on nerve morphology method and counterchecked with whole spine numbering method. Gender distribution showed 5 females (21.7%) and 18 males (78.2%) having transitional vertebra. Out of 23 patients with transitional vertebrae, 8 patients (34.7%) had lumbarization and 15 patients (65.2%) had sacralization. Gender distribution showed males having more lumbarization (6:18) as compared to sacralization (3:18). While in females, 3:5 patients had sacralization and 2:5 had lumbarization. In sacralization of LV5, 3 patients had Castellvi type Ia (2.2%), 3 patients had Castellvi type IIa (2.2%), 2 patients had castellvi type IIb (1.5%) and 2 had type IIIa (1.5%) and 4 patients had castellvi type IIIb (3%) and one had type IV (0.7%). O'Driscoll staging showed 27 patients with type I morphology (20%), 53 patients with type II (39.3%), 38 patients type III (28.1%) and 17 patients with type IV morphology (12.6%) (Figure-2). Two patients had hypoplastic 12th ribs and one patient had cervical ribs. These three patients also had LSTV with lumbarization of SVI in first two cases and sacralization of LV5 in last patient. Two patients had normal LumboSacral transition but extensive spinal osseous metastatic disease with large expansile masses in sacral ala, making identification of L5 nerve root difficult so these two cases were excluded from the study.

L5 nerve root morphology was accurately identified in 131 patients and the exact vertebral count was determined confidently. However, in four patients, nerve morphology method could not determine the exact vertebral level and we had to rely on counting method. A female patient with hemivertebrae, left pelvic kidney and supernumery ribs at LVI vertebral body, had L5 nerve root arising from lumbarized SVI. Two other patients with supernumery LVI ribs had L5 nerve morphology arising from lumbarized SVI. A patient with 11 pairs of ribs and multiple congenital anomalies had equal size of L4 and L5 nerve roots alongwith sacralization of LV5. Accuracy of the test was determined by Area

Under Curve(AUC) which was found to be 0.926, representing excellent diagnostic value shown in the Table.

Table: Diagnostic parameters of LumboSacral Transitional Vertebra (LSTV) Methods (n=135)

LSTV on Counting Method	LSTV on Nerve Identification Method	
	Yes	No
Yes	23	4
No	0	108

Sensitivity= True Positive/(True Positive +False Negative)=85.19%

Specificity= True Negative / (True Negative +False Positive) =100.00%

Positive Predictive Value= True Positive/ (True Positive+ False Positive) =100.00%

Negative Predictive Value= True Negative/ (True Negative +False Negative) = 96.43%

Diagnostic Accuracy= (True Positive +True Negative)/All Patients=97.04%

AUR=0.926, 95% CI: 0.846 - 1.00

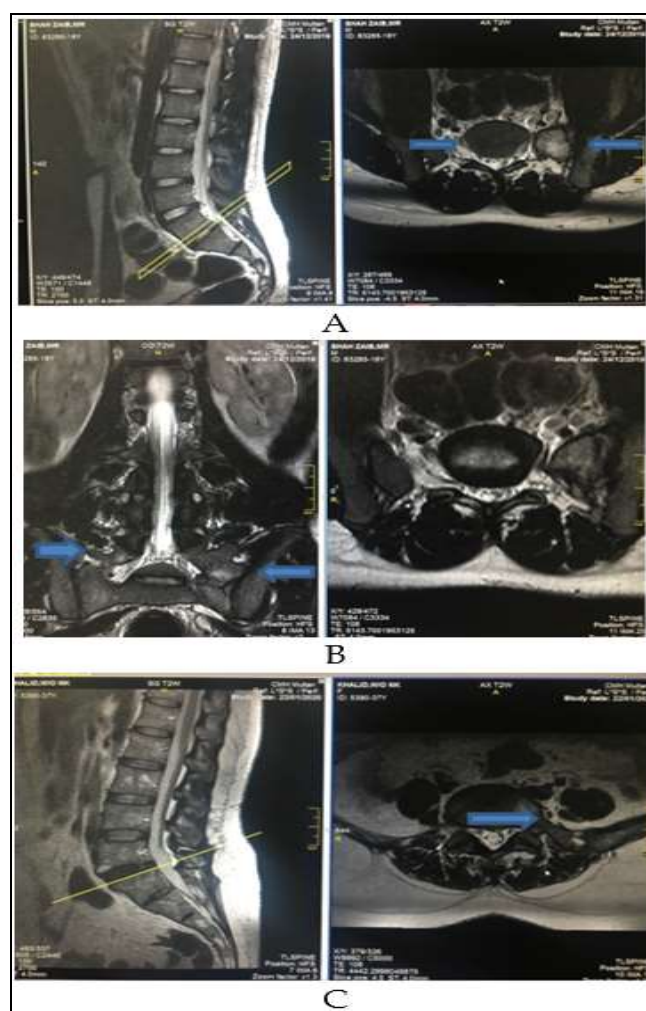


Figure-2: (A-C): LumboSacral Transitional Vertebra(LSTV). A; shows sacralized LV5 (Castellvi stage IV) and L5 nerve root was noted arising from sacralized LV5. **B;** coronal image of same patient shows Castellvi stage IV with IIa on right side and IIIa on left side. **C;** Lumbarization of SV1 with well formed intervertebral disc between first sacral segment and sacrum. On axial scan, L5 nerve was noted joining smaller L4 peroneal branch

DISCUSSION

Lumbosacral transitional vertebra are seen due to abnormal segmentation or variable degree of fusion of lowest lumbar vertebra with the sacrum.⁸ In cases of LSTV, when complete or whole spine scans are not available, numbering of lumbosacral vertebrae becomes very difficult due to lack of a reliable enumeration method. We determined that the exiting L5 nerve can be identified due to its characteristic anatomical features and can help in accurate numbering of the L5 vertebra.^{9,10} In a previous study different auxiliary parameters were evaluated to determine their role in lumbar vertebra numbering. The most common locations of the paraspinal parameters were: Right renal artery: L1 vertebrae (45%), Superior Mesenteric artery: L1 vertebrae (66%), Celiac trunk: T12 vertebrae (46%), Aortic bifurcation: L4 vertebrae (63%), and Inferior vena cava confluence: L4 vertebrae (52%).¹¹ According to this study, none of these auxiliary parameters can be used as accurate identification markers for LSTV. When vertebral morphology and lumbosacral axis angle were evaluated for numbering of lumbosacral vertebra, it was impossible to correctly identify lumbosacral transitional vertebra in 6.2% of the LSTV group. Previously in a study carried out by Tins BJ, this rate was found to be 7%.¹² On the contrary, transitional vertebra was incorrectly labeled in 4.6% of patients having normal lumbosacral morphology.

One study carried out on lumbar spine of 100 patients and proposed a classification into four types based on the disc morphology between first sacral segment and the remaining sacrum. Patients with pseudarthrosis (Castellvi type IIa or IIb) were not reliably identified with this method. However, identification of pseudoarthrosis can be accomplished by correlation with axial images through the lumbosacral junction because enlargement of the transverse processes of the LSTV can be readily determined on axial scans. Therefore, the identification of LSTV can be made using MRI. However, these techniques still do not completely help in enumeration of vertebral segments.¹³

Anatomical stability is noted in cervical spine with fixed number of vertebrae, i.e. 7. On the other hand, the thoracic and lumbar segments are subjected to variation in terms of number of vertebral bodies.¹⁴ Variation is observed in bony structures in upto 16% of population, developing embryologically from mesoderm, as compared to neural structures developing

from ectoderm showing less variation.¹⁰ One study was carried out to assess the role of vascular and osseous anatomical landmarks in vertebral segmentation enumeration. He found a great deal of variation in these landmarks with caudal and cranial shifts in lumbarization and sacralization, respectively. In his study, iliolumbar ligament was found to arise at L5 alone or its adjacent disc in 93.8% of cases in control population and in 80% of cases with last lumbar vertebra L4 or adjacent disc. Costal facet was observed at D12 in 96.9% and 91.7% in the control and lumbarization population. Similarly, psoas major origin was observed from D12 or D12-L1 in 69.3% and 95.7% of patients in the normal and sacralization groups, respectively.¹⁵ Hence, these markers can be helpful but none of them led to 100% accurate identification.^{2,16}

The characteristic neuroanatomic features of L5 nerve root help in its demarcation and thus corresponding LV5-SV1 vertebral level can be determined. First, L5 does not show proximal branching in its course. The L1-L4 nerves contribute to Lumbar plexus through anterior and posterior Divisions, immediately after exit from neural foramina. The L3 and L4 nerve roots join to form femoral nerve below the L4-5 disc space.¹⁷ The L4 nerve, after division, contributes to femoral and obturator nerves and also gives a small branch that communicates with L5 nerve. L5 nerve gives contribution to Tibial nerve and common peroneal nerve. This branch of L4, joining L5 nerve is very small in caliber¹⁸. This "nonsplitting" pattern of L5 can be used to determine the level of LV5-SV1 by tracing nerve back to level of origin. This level was correlated with sagittal and coronal images to determine lumbosacral enumeration and document any LSTV if present. The result was then matched with vertebral body counting method involving whole spine, taken as standard. Classification of LSTV was done according to Castellvi and O Driscoll method. On correlation with sagittal images, If the first nonsplitting nerve was found to arise at vertebral body 2 levels above the first sacral body, the patient was considered to have lumbarization of S1. Second point of identification is the union of small L4 contribution with L5 occurring commonly at the level of the sacrum, thus helping in its demarcation.¹⁹ Third point to aid to localization of L5 nerve is the difference in caliber of L5 nerve and small peroneal contribution of L4 with L5 width being almost twice in thickness along sacrum.²⁰ Differences in nerve caliber along the sacrum can be useful for localization in patients with a

paucity of abdominal fat where the psoas muscle obscures L4 nerve root and when there are confounding adjacent small vascular structures. In patients with normal vertebral segmentation, L5 can be traced back to LV5-SV1 level, keeping in view the above mentioned anatomical details. In patients with lumbarization of SVI, almost equal caliber of L5 and S1 nerves is noted coursing along the sacrum. In patients with sacralization of L5, i-e, L5 nerve caliber is thicker as compared to L4 peroneal branch. These images were correlated with sagittal T2WS to count the number of vertebrae from cervicothoracic region for complete authentication.

Accurate identification of L5 nerve is extremely important as in our study, we found few patients having no significant difference in caliber of L5 nerve and L4 peroneal branch. However, L5 nerve root was identified, keeping in view the other two features of non-splitting nature and peroneal branch of L4 joining L5 along lateral aspect of sacrum. Other pitfalls in identification and numbering of vertebral bodies in our study included congenital vertebral anomalies like hemivertebra seen in one patient. Three patients showed extensive degenerative facet joint arthropathy and foraminal stenosis posing difficulty in identification of nerve and characterization of LSTV.

The problem of vertebral enumeration and identification of transitional vertebra is faced off and on by Radiologists especially in cases of limited field of view MRI or in absence of cervicothoracic localizer. This method based on identification of L5 nerve root morphology is easily applicable as it requires only familiarization with basic neuroanatomy of lumbar plexus and L5 nerve root. No further extensive training or modification of procedure is required. This method will eliminate ambiguity and improve consistency in reporting by Radiologists. It will be advantageous in patients who are undergoing pre-surgical planning for diagnostic or Interventional procedures as symptoms due to specific dermatome distribution are to be treated. Accurate identification of L5 nerve root leading to corresponding vertebral enumeration and localization of transitional vertebra will help eliminate chances of intervention at unintended level.

CONCLUSION

Neuroanatomic localization of L5 nerve root can help in accurate enumeration of corresponding vertebral level, and hence, identification of transitional vertebra. This method has great application especially in patients undergoing pre-surgical planning where whole spine MRI

images are not available. This method can easily be acquired through familiarization with L5 nerve root morphology and applied for accuracy and consistency in reporting by Radiologists.

Conflict of Interest: None.

Authors' Contribution

Following authors have made substantial contributions to the manuscript as under:

SK & AQ: Data acquisition, data analysis, critical review, approval of the final version to be published.

ND & AJ: Study design, data interpretation, drafting the manuscript, critical review, approval of the final version to be published.

SB & RA: Conception, data acquisition, drafting the manuscript, approval of the final version to be published.

Authors agree to be accountable for all aspects of the work in ensuring that questions related to the accuracy or integrity of any part of the work are appropriately investigated and resolved.

REFERENCES

1. Tins BJ, Balain B. Incidence of numerical variants and transitional lumbosacral vertebrae on whole-spine MRI. *Insights Imaging* 2016; 7(2): 199-203. <https://doi.org/10.1007/s13244-016-0468-7>
2. Jagannathan D, Indiran V, Hithaya F, Alamelu M, Padmanaban S. Role of Anatomical Landmarks in Identifying Normal and Transitional Vertebra in Lumbar Spine Magnetic Resonance Imaging. *Asian Spine J* 2017; 11(3): 365-379. <https://doi.org/10.4184/asj.2017.11.3.365>
3. Konin GP, Walz DM. Lumbosacral transitional vertebrae: classification, imaging findings, and clinical relevance. *AJNR Am J Neuroradiol* 2010; 31(10): 1778-1786. <https://doi.org/10.3174/ajnr.A2036>
4. Tureli D, Ekinci G, Baltacioglu F. Is any landmark reliable in vertebral enumeration? A study of 3.0-Tesla lumbar MRI comparing skeletal, neural, and vascular markers. *Clin Imaging*. 2014; 38(6): 792-796. <https://doi.org/10.1016/j.clinimag.2014.05.00>
5. Hughes RJ, Saifuddin A. Numbering of lumbosacral transitional vertebrae on MRI: role of the iliolumbar ligaments. *AJR Am J Roentgenol* 2006; 187(1): W59-65. <https://doi.org/10.2214/AJR.05.0415>
6. Jhawar BS, Mitsis D, Duggal N. Wrong-sided and wrong-level neurosurgery: a national survey. *J Neurosurg Spine* 2007; 7(5): 467-472. <https://doi.org/10.3171/SPI-07/11/467> Erratum in: *J Neurosurg Spine* 2008 Jul; 9(1): 109.
7. Peckham ME, Hutchins TA, Stilwill SE, Mills MK, Morrissey BJ, Joiner EAR, et al. Localizing the L5 Vertebra Using Nerve Morphology on MRI: An Accurate and Reliable Technique. *AJNR Am J Neuroradiol* 2017; 38(10): 2008-2014. <https://doi.org/10.3174/ajnr.A5311>
8. Tini PG, Wieser C, Zinn WM. The transitional vertebra of the lumbosacral spine: its radiological classification, incidence, prevalence, and clinical significance. *Rheumatol Rehabil* 1977; 16(3): 180-185. <https://doi.org/10.1093/rheumatology/16.3.180>
9. Peker E, Hürsoy N, Akkaya H E, Ünal E S, Gülpinar E B, Arıkan B B, et al. Evaluation of spinal-paraspinal parameters to determine segmentation of the vertebrae. *Pol J Radiol* 2019; 84: e470-e477.

L5 Nerve Root Morphology

10. Tins BJ, Balain B. Incidence of numerical variants and transitional lumbosacral vertebrae on whole-spine MRI. *Insights Imaging* 2016; 7: 199-203. <https://doi.org/10.1007/s13244-016-0468-7>
 11. Tokgoz N, Ucar M, Erdogan AB. Are spinal or paraspinal anatomic markers helpful for vertebral numbering and diagnosing lumbosacral transitional vertebrae? *Korean J Radiol* 2014; 15: 258-266. <https://doi.org/10.3348/kjr.2014.15.2.258>
 12. Castellvi AE, Goldstein LA, Chan DP. Lumbosacral transitional vertebrae and their relationship with lumbar extradural defects. *Spine (Phila Pa 1976)* 1984; 9(5): 493-495. <https://doi.org/10.1097/00007632-198407000-00014>
 13. O'Driscoll CM, Irwin A, Saifuddin A. Variations in morphology of the lumbosacral junction on sagittal MRI: correlation with plain radiography. *Skeletal Radiol* 1996; 25: 225-30. <https://doi.org/10.1007/s002560050069>
 14. Wigh RE. Classification of the human vertebral column: phylogenetic departures and junctional anomalies. *Med Radiogr Photogr* 1980; 56: 2-11.
 15. Farshad-Amacker NA, Lurie B, Herzog RJ, Farshad M. Is the iliolumbar ligament a reliable identifier of the L5 vertebra in lumbosacral transitional anomalies? *Eur Radiol* 2014; 24(10): 2623-2630. <https://doi.org/10.1007/s00330-014-3277-8>
 16. Lee CH, Park CM, Kim KA, Hong SJ, Seol HY, Kim BH, et al. Identification and prediction of transitional vertebrae on imaging studies: anatomical significance of paraspinal structures. *Clin Anat*. 2007; 20(8): 905-914. <https://doi.org/10.1002/ca.20540>
 17. Menezes CM, de Andrade LM, Herrero CF, Defino HL, Ferreira Júnior MA, Rodgers WB, et al. Diffusion-weighted magnetic resonance (DW-MR) neurography of the lumbar plexus in the preoperative planning of lateral access lumbar surgery. *Eur Spine J* 2015; 24(4): 817-826. <https://doi.org/10.1007/s00586-014-3598-y>
 18. Benedetto PD, Pinto G, Arcioni RA, Blasi D, Sorrentino, Baciarello M, Capotondi C. Anatomy and imaging of Lumbar Plexus. *Minerva Anestesiol* 2005; 71: 549-554.
 19. Philip A, Hijbregts P. Anatomical Variations of the Lumbar Plexus: A Descriptive Anatomy Study with Proposed Clinical Implications. *J Manual Manip Ther* 2009; 17(4): 107-114.
 20. Chaves H, Bendersky M, Goñi R, Gómez C, Carnevale M, Cejas C. Lumbosacral plexus root thickening: Establishing normal root dimensions using magnetic resonance neurography. *Clin Anat* 2018; 31(6): 782-787. <https://doi.org/10.1002/ca.23073>
-