

PAINTBALL OCULAR INJURIES—A PREVENTABLE DISASTER

Qamar UI Islam, Muhammad Kashif Hanif*

Pakistan Navalship Shifa Hospital, Karachi Pakistan, *Armed Forces Institute of Ophthalmology Rawalpindi Pakistan

ABSTRACT

As the paintball sports including war games have become popular, the incidence of paintball ocular injuries has increased considerably. These injuries are usually blunt trauma resulting from paintball projectiles, which travel at a speed of 80-130 m/s. We report 3 cases of ocular paintball injuries with compromised visual outcome sustained in unprotected environment highlighting the importance of compulsory use of American society for testing and material (ASTM) compliant eye protective devices (EPD) during paintball related activities.

This is an Open Access article distributed under the terms of the Creative Commons Attribution License (<http://creativecommons.org/licenses/by/4.0>), which permits unrestricted use, distribution, and reproduction in any medium, provided the original work is properly cited.

INTRODUCTION

Sports related ocular injuries are preventable in 90% of cases with the use of proper protective eye wear^{1,2}. War games with paintball pellets have become increasingly popular, but it can result in severe ocular injuries if proper ocular protection is not used. Paintballs are small (17 mm diameter) gelatin projectiles filled with non-toxic, water soluble paint that explode on contact with an object at a velocity of 100 – 300 feet/sec^{2,3-5}. Eye is the most commonly affected organ in paintball injuries (42.7%) with poor visual outcome in 30–43% of patients⁶⁻⁸.

Because of their large size and relatively low velocity, paintballs usually cause blunt ocular injuries resulting from coup-counter coup trauma and equatorial expansion^{2,4}. The most common anterior segment injuries include hyphema, lens dislocation, cataract, angle recession and iridodialysis². Common posterior segment manifestations include commotion retinae, choroidal rupture, vitreous hemorrhage, retinal tear/dialysis and macular hole².

CASE REPORT

Case-1: A 24 years old male sustained paintball injury to his right eye while playing without protective eye wear. Presenting visual acuity

was Counting Finger (CF) at 2 meter with commotio retinae and inferior vitreous hemorrhage. He was managed conservatively with topical steroids and anti glaucoma medications. On eight month follow up visit best corrected visual acuity (BCVA) in right eye was 6/36 with epiretinal membrane and a patch

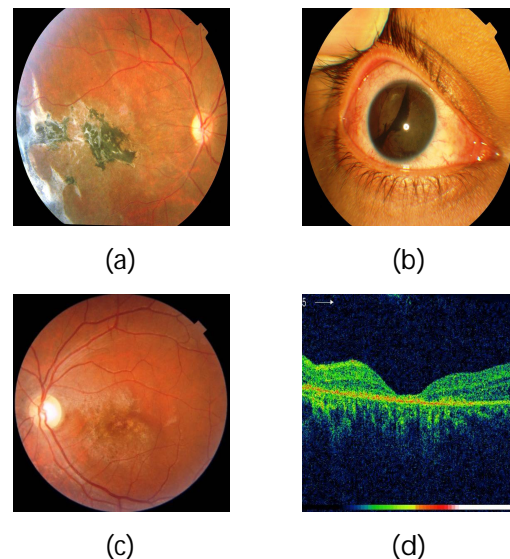


Figure-1: Ocular findings in paintball Injuries (a) Chorioretinitis Sclopetaria (b) Traumatic iridodialysis (c) & (d) Atrophic Maculopathy.

of chorioretinal scarring with fibrosis (Chorioretinitis Sclopetaria) temporal to fovea.

Case-2: A 23 years old male was hit in an unprotected left eye by a paintball pellet during training activity. Initial examination revealed visual acuity of 1/60 in left eye with relative afferent pupillary defect (RAPD), commotio

Correspondence: Dr Qamar UI Islam, Classified Eye Spec Eye Department PNS Shifa Naval Hospital, Karachi, Pakistan (Email: qamarulislam71@gmail.com)

Received: 09 Jul 2014; revised received: 08 Jul 2014; accepted: 02 Dec 2014

retinae and vitreous hemorrhage. He was managed conservatively and at 9 month follow up visit BCVA was 2/60 in affected eye with RAPD, temporal disc pallor and atrophic maculopathy.

Case-3: During a training activity a 23 year old soldier sustained paintball injury in an unprotected right eye. Visual acuity at presentation was hand movement (HM) at 1 meter in affected eye with hyphema, traumatic cataract, iridodialysis and severe commotio retinae. He underwent cataract surgery with IOL implantation after one month of injury. BCVA at 3 months after surgery improved to 6/60.

DISCUSSION

Sports-related ocular injuries are 4 times more common in young men^{2,4}. All our patients was young males (mean age: 23.3 years). Mean age ranging from 16-22.7 years were reported in various studies on ocular paintball injuries^{2,4-5, 9-10}. Presenting visual acuity was < 6/60 in all our cases with 1 out of 3 patients having final BCVA < 6/60. Presenting visual acuity of < 6/60 was reported in 70 -78% of patients of ocular paintball injuries in various studies^{2,4,9}. Final BCVA remained < 6/60 in 40-50% of eyes with ocular paintball trauma suggesting the catastrophic nature of such injuries^{2,4-5,9-10}.

Listman et al and Farr et al in their studies reported hyphema, vitreous hemorrhage, and traumatic cataract as the commonest manifestations of the ocular paintball trauma^{8,11}. Determinant of poor visual outcome in such injuries include traumatic maculopathy, epiretinal membrane formation and optic neuropathy^{5,12}.

American society for testing and material (ASTM) in 1997 issued standard specifications for eye protective devices (EPDs) used in

paintball sports¹³. The incidence of ocular injuries would be reduced by 90% or more with the proper use of ASTM-compliant EPDs during paintball sports². None of our patients was wearing ocular protection at the time of injury. Non usage of ocular protection during paintball games was reported in the range of 100% to 95% non usage, resulting in higher and severe ocular morbidity after such injuries^{1,5, 9-10}.

CONCLUSION

Increased awareness and compulsory use of ASTM-compliant EPDs during paintball games is mandatory to avert and avoid this preventable disaster.

CONFLICT OF INTEREST

The authors of this study reported no conflict of interest.

REFERENCES

1. Masha'our RS, Habib HJ, Garzozzi H. Ocular Paintball Injury with and without Eye Protection. *Asian J Ophthalmol* 2004; 6(1): 13-14.
2. Keles S, Ondas O, Ekinci M, Sener MT, Erhan E, Sirinkan A, et al. Paintball-related ocular trauma: Paintball or Painball?. *Med Sci Monit* 2014; 20:564-8.
3. Sbicca JA, Hatch RL. Target lesions and other paintball injuries. *J Am Board Fam Med* 2012; 25(1):124-7.
4. Fineman MS, Fischer DH, Jeffers JB, Buerger DG, Repke C. Changing trends in paintball sport-related ocular injuries. *Arch Ophthalmol*. 2000; 118(1):60-4.
5. Taban M, Taban M, Sears JE. Ocular findings following trauma from paintball sports. *Eye (Lond)*. 2008; 22(7):930-4.
6. Conn JM, Annest JL, Gilchrist J, Ryan GW. Injuries from paintball game related activities in the United States, 1997-2001. *Inj Prev*. 2004; 10(3):139-43.
7. Fineman MS. Ocular paintball injuries. *Curr Opin Ophthalmol*. 2001; 12(3):186-90.
8. Listman DA. Paintball injuries in children: more than meets the eye. *Pediatrics*. 2004; 113(1 Pt 1):e15-8.
9. Alliman KJ, Smiddy WE, Banta J, Qureshi Y, Miller DM, Schiffman JC. Ocular Trauma and Visual Outcome Secondary to Paintball Projectiles. *Am J Ophthalmol* 2009; 147(2): 239-42.
10. Pakh PJ, Adelman RA. Ocular trauma resulting from paintball injury. *Graefes Arch Clin Exp Ophthalmol*. 2009; 247(4):469-75.
11. Farr AK, Fekrat S. Eye injuries associated with paintball guns. *Int Ophthalmol*. 1998-1999; 22(3):169-73.
12. Mason III JO, Feist RM, White MF. Ocular Trauma from Paintball-Pellet War Games. *South Med J*. 2002; 95(2): 218-22.
13. American Society for Testing and Materials. Standard specification for eye protective devices for paintball sports. In: 1997 Annual Book of ASTM Standards. West Conshohocken, Pa: American Society for Testing and Materials 1997; 1391- 99.