

IDH-1, ATRX AND 1P19Q CO-DELETION IN DIFFUSE GLIOMAS

Rabia Javed, Noreen Akhtar, Usman Hassan, Mohammad Azam, Asif Loya, Mudassir Hussain, Maryam Hameed, Sumera Butt, Sajid Mushtaq

Shaukat Khanum Memorial Cancer Hospital and Research Centre, Lahore, Pakistan

ABSTRACT

Objective: To stratify diffuse gliomas into subtypes including diffuse astrocytomas, oligodendrogliomas and glioblastomas based on recent molecular updates and assess their frequencies in our local subpopulation.

Study Design: Cross-sectional study.

Place and Duration of Study: Department of Histopathology, Shaukat Khanum Memorial Cancer Hospital and Research Centre, Lahore, Pakistan, from Jun 2015 to Jul 2017

Methodology: Two hundred and fourteen (n=214) cases of adult diffuse gliomas were evaluated. Clinical and morphological features like age, gender and type of tumor were quantified. Molecular studies including IDH 1 by antibody and PCR, ATRX by antibody and 1p/19q co-deletion by FISH were tested. Gliomas were subcategorized based on WHO 2016 guidelines.

Results: Mean age of presentation was 39 years. Overall n=146/214 (68.2%) of the cases were completely classifiable including Diffuse Astrocytomas, Oligodendrogliomas and Glioblastomas. Out of the glioblastomas (n=81), 67/81(n=82.7%) were IDH Wild type and 14/81 (17.3%) were IDH Mutant.

Conclusion: In this study, glioblastomas are the most frequent gliomas as categorized by current WHO molecular guidelines followed by diffuse astrocytomas. Oligodendrogliomas are the least common.

Keywords: ATRX, Diffuse astrocytomas, Glioblastoma, IDH1, Oligodendrogliomas, 1p/19q co-deletion.

This is an Open Access article distributed under the terms of the Creative Commons Attribution License (<http://creativecommons.org/licenses/by/4.0>), which permits unrestricted use, distribution, and reproduction in any medium, provided the original work is properly cited.

INTRODUCTION

The adult diffuse gliomas are the most common primary central nervous system tumors^{1,2}. The diagnosis of diffuse gliomas has historically been based primarily on histopathologic features³. Their correct pathologic diagnosis required the ability to distinguish astrocytic from oligodendroglial differentiation, a challenging feat even for the most experienced neuropathologist. Interobserver variability in the diagnosis of diffuse gliomas has been high owing to subjective diagnostic criteria, overlapping morphologic features, and variations in training and practice among pathologists⁴. In addition, previously, all glial tumors were grouped under one major category including both localised gliomas such as pilocytic astrocytomas as well as diffuse gliomas including diffuse astrocytomas. Yet these tumors have a wide range of biological behaviours that are only

partially explained by morphology⁵.

Recent updating of the World Health Organization (WHO) classification of central nervous system (CNS) tumors in 2016 demonstrates the first organized effort to restructure brain tumor classification by incorporating histomorphologic features with recurrent molecular alterations⁶. Revised CNS tumor diagnostic criteria more distinctly delineates astrocytomas that are more circumscribed, that lack IDH gene alterations and may contain BRAF mutations (i.e, pilocytic astrocytomas, pleomorphic xanthoastrocytoma and sub-ependymal giant cell astrocytoma) from diffuse gliomas. Also, oligodendrogliomas are now closer to diffuse astrocytomas in terms of prognosis that localised gliomas⁶.

Diffuse gliomas category now includes the grade II and III astrocytomas and oligodendrogliomas along with grade IV glioblastomas^{7,8}. Glioblastomas are now divided into two major subtypes based on IDH mutation status⁹. IDH-wildtype glioblastoma account for about 90% of all glioblastomas² and are also known as primary

Correspondence: Dr Rabia Javed, Department of Histopathology, Shaukat Khanum Memorial Cancer Hospital and Research Centre, Lahore, Pakistan (Email: rabiajavedpiracha@gmail.com)

Received: 16 Nov 2018; revised received: 17 Feb 2019; accepted: 19 Feb 2019

glioblastomas indicating that they typically arise de novo, without a precursor lesion. IDH mutant glioblastomas (secondary glioblastomas) account for around 10% of all glioblastomas⁸. These develop through malignant progression from grade II or III astrocytomas⁸. Secondary glioblastomas usually present earlier, are preferentially located in the frontal lobe and have a better prognosis than primary glioblastomas.

Diffuse gliomas are genetically classified into distinct subtypes based primarily on Isocitrate Dehydrogenase (IDH) mutation status, ATRX and co-deletion of chromosome 1p and 19q (1p/19q) along with other molecular markers such as p53, TERT and ki67^{2,3}. These molecular sub-types help clinicians plan treatment strategies with respect to the molecular subtypes in conjunction with WHO grade of tumor. IDH (isocitrate dehydrogenase) is an extremely important molecular marker with immense prognostic value which is now used to categorise diffuse gliomas². Both IDH 1 and IDH 2 mutations occur in infiltrating gliomas. IDH 1 mutations are more common; present in approximately 70-80% of astrocytomas and secondary glioblastomas. The most frequently occurring IDH 1 mutation is R132H which occurs at codon 132 and there is exchange of amino acid arginine for histidine. IDH mutant gliomas have a slower progression over the course of time than those lacking IDH mutation and IDH mutant gliomas having a much better prognosis than IDH wild type. IDH mutations occur early in tumorigenesis of gliomas as indicated by the fact that they occur in both astrocytic and oligodendroglial gliomas.

Among IDH mutant gliomas, there are 2 major types, one category is that which will show 1p/19q co-deletion and the other larger category which demonstrates loss of ATRX. Alpha Thalassemia/ Mental Retardation Syndrome X-linked (ATRX) is a gene that codes for a chromatin remodelling regulator. ATRX mutation is associated with Alternative Lengthening of Telomeres (ALT) phenotype². Loss of ATRX immunohistochemical staining in tumor cells can be used as

a surrogate for ATRX gene inactivation and supports a diagnosis of astrocytoma.

Oligodendrogliomas are the type of diffuse gliomas that are characterized by IDH mutation and 1p19q co-deletion¹. Deletion of the 1p and 19q chromosomal arms occurs through an unbalanced translocation which leads to inactivating mutations of tumor suppressor genes FUBP 1 and CIC on chromosomes 1p and 19q respectively. These mutations are specific for oligodendrogliomas with 1p/19q co-deletion and are mutually exclusive with Tp53 and ATRX mutations. Activating mutations in TERT (telomerase reverse transcriptase promoter) are noted in almost all oligodendrogliomas.

IDH can be detected by immunohistochemistry as well as by Polymerase Chain Reaction (PCR) and both modalities have been used in our study. ATRX gene undergoes inactivating mutations in astrocytomas. Fluorescent in situ hybridization (FISH) analysis for detection of 1p/19q co-deletion is one of the ways to detect this co-deletion which is seen in cases of oligodendrogliomas.

In this study, we share our experience in terms of the frequencies of IDH mutations, 1p19q co-deletion and ATRX loss of expression in 214 cases of WHO defined adult diffuse gliomas-diagnosed at Shaukat Khanum Memorial Cancer Hospital and Research Centre, Lahore Pakistan, from June 2015 to July 2017.

METHODOLOGY

The study design was, cross-sectional study. The study was approved by the Institutional Review Board of Shaukat Khanum Memorial Cancer Hospital & Research Centre (SKMCH & RC). All cases of adult diffuse gliomas (n=214), that were received at SKMCH&RC from June 2015 to July 2017 were selected through non-probability consecutive sampling. These included all cases with a tissue diagnosis of diffuse gliomas including oligodendrogliomas, diffuse astrocytomas and glioblastomas.

Tissues with poor processing and post treatment specimen were excluded from the study. For all cases, Haematoxylin and Eosin stained slides were reviewed under light microscopic examination by a consultant histopathologist with a special interest in neuropathology. Additional studies (IHC, IDH PCR, and FISH for 1p19q co-deletion) were performed where and as needed. The relevant clinical data was extracted from electronic medical record including age, gender and location of tumor¹¹⁻¹⁵.

Grading according to WHO guidelines was performed in all cases under light microscopic examination. Tumors showing cytologic atypia along with variation in nuclear shape/size and hyperchromasia were graded as WHO Grade II. Tumors additionally showing anaplasia and unequivocal mitotic activity were labelled as Grade III and when microvascular proliferation and/or necrosis was also present, the tumor qualified as WHO Grade IV¹⁶⁻¹⁸.

Paraffin blocks were then selected for immunohistochemistry for stains such as IDH, ATRX, Olig2, p53 and Ki67 as per requirement of each case. Anti-IDH1 R132/DIA-H09 mouse monoclonal anti-brain tumor marker, clone H09, lyophilized powder (Dianova) was used for immunohistochemical evaluation of IDH1. The expression of IDH mutations was determined by assessing cytoplasmic staining in proportions of positively stained tumor cells. Cases in which >10% cells were stained were defined as positive. Cases which were negative by IHC were tested by IDH-PCR^{19,20}.

All sections were immunostained with mouse monoclonal anti-ATRX antibody, clone CL0537, purified immunoglobulin, and buffered aqueous glycerol solution (Sigma-Aldrich). ATRX gene mutation leads to loss of nuclear protein expression in tumor cells. Endothelial cells and normal glial cells serve as positive internal control. Cases with >50% stained tumor cells in the presence of positive internal control were considered ATRX retained and cases with <50%

stained cells were considered negative (ATRX Loss).

Routine IHC cannot assess 1p19q co-deletion. Chromosomal loss of 1p and 19q was detected by Fluorescent In-situ Hybridization using VYSIS Abbott 1p/19q probe. After interpretation of IDH1, ATRX, Olig-2 and other ancillary stains, gliomas were categorized into molecular subtypes based predominantly on the guidelines²⁵. Cases in which IDH mutation was present, ATRX was retained and 1p19q co-deletion by FISH was identified were classified as Oligodendrogliomas. Cases which showed loss of ATRX expression were classified as Astrocytomas, IDH mutant and IDH wildtype depending on the status of IDH immunohistochemistry. Cases which were negative for IDH by immunohistochemistry, IDH by PCR (polymerase chain reaction) was recommended on them. FISH for 1p19q co-deletion was performed on those cases in which morphology and immunohistochemistry favoured the diagnosis of oligodendroglioma.

Statistical analysis was carried out using the SPSS statistical software package (version 20.0; SPSS, Chicago, IL, USA).

RESULTS

The current WHO 2016 classification of diffuse gliomas relies on histopathological and molecular parameters. This is in sharp contrast to the previous categorization that relied heavily on light microscopic appearance of the tumour and its line of differentiation. We studied 214 cases of adult diffuse gliomas between June 2015 and July 2017. The aim of this study was to evaluate how many cases could be properly classified after incorporation of the recent molecular parameters with special emphasis on IDH, ATRX and 1p/19q co-deletion.

Mean age of patients was 39 years with patient's ranging in age from 18 years to 80 years. There were n=81/214 (37.9%) females and n=133/214 (62.1%) males.

Exact location of 135/214 (63.1%) cases was known of which 42/135 (31.1%) were frontal,

14/135 (10.4%) frontoparietal, 7/135 (5.2%) occipital, 34/135 (25.2%) parietal, 21/135 (15.5%) temporal and 17/135 (12.6%) were located in the temporoparietal region. There were 79/214 (36.9%) cases in which exact location was not

The first algorithm (fig-1) was for grade II and III adult diffuse gliomas that were tested for IDH-PCR. There were a total of 28/133 (21.1%) cases on which IDH was tested by PCR. Of these, 26/28 (93%) cases were positive (IDH-mutant)

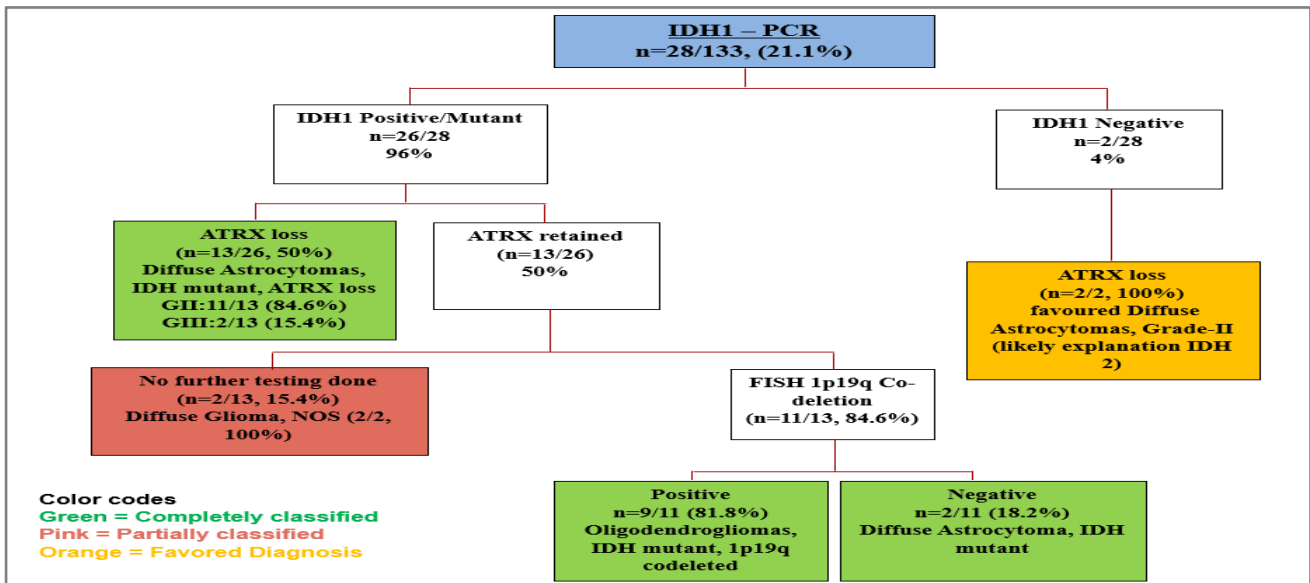


Figure-1: Distribution of IDH1-PCR Tested Cases.

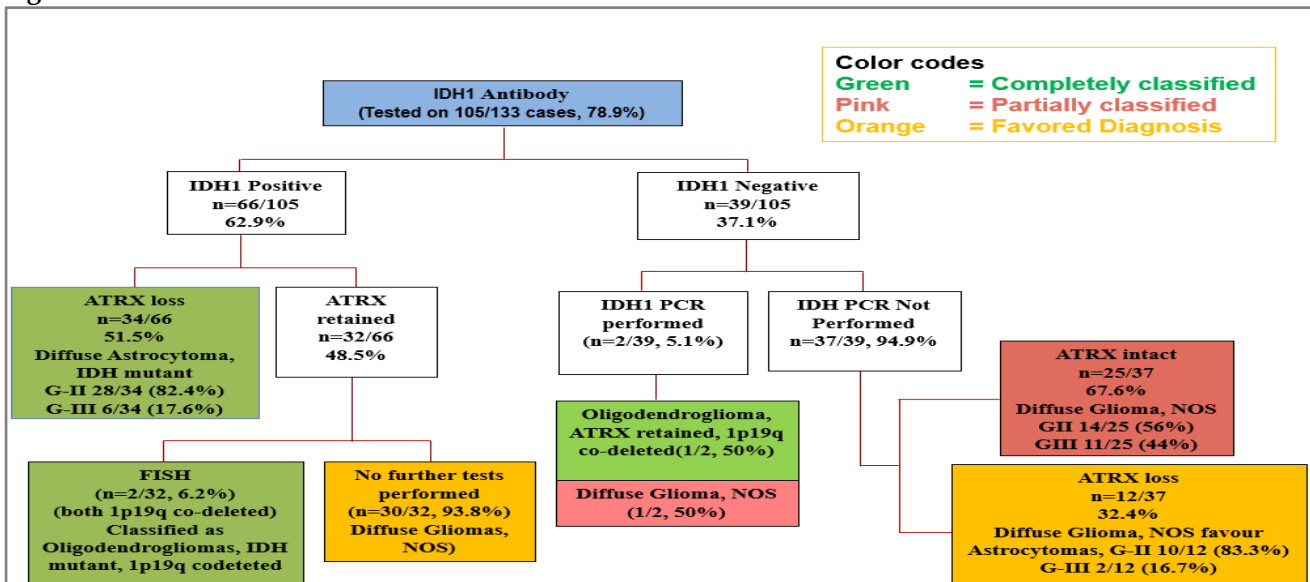


Figure-2: Distribution of IDH1 antibody tested cases.

mentioned.

In this study, IDH1 has been evaluated by immunohistochemistry and PCR and two separate work flow charts depicting their results have been incorporated.

and ATRX loss was found in n=13/26 (50%) of these cases and these were classified as Diffuse Astrocytomas, IDH mutant, ATRX loss. However, n=13/26 (50%) of these IDH mutant cases by PCR retained ATRX and FISH testing for 1p19q co-deletion was tested on n=11/13 (85%) of

these cases. It was seen that 1p19q co-deletion was present in 9/11 (81.8%) of these cases and they were labelled as Oligodendrogliomas, IDH mutant, 1p/19q co-deleted. The other two cases 2/11 (18.2%) did not show 1p/19q co-deletion and were classified as Diffuse Gliomas, NOS. On the other hand, there were n=2/28 (7.14%) cases that were IDH negative by PCR. ATRX was performed on both these IDH-PCR negative cases. Both cases showed ATRX loss (2/2, 100%) and a diagnosis of Diffuse Astrocytoma, grade II was favoured.

The second algorithm (fig-2) that was assessed in this study was of those 105/133 (78.9%) cases of grade II and III adult diffuse

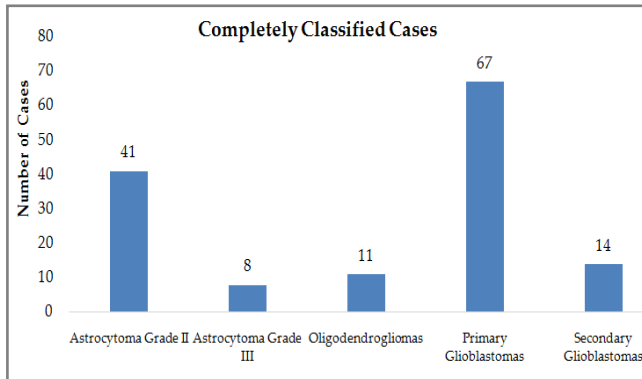


Figure-3: Classification of cases according to WHO guidelines.

gliomas which were tested by IDH1 antibody using immunohistochemistry. Of the 66/105 (62.9%) IDH mutant cases, those that showed ATRX loss (n=34/66, 51.5%) were classified into final subcategories and included 28/34 (82.4%) Diffuse Astrocytomas, IDH Mutant, ATRX loss, WHO Grade II and 6/34 (17.6%) cases of Anaplastic Astrocytomas, IDH Mutant, ATRX loss, WHO Grade III. 32/66 cases (48.5%) retained ATRX. FISH studies for 1p/19q co-deletion was only performed on 2/32 (6.3%) of these cases, both of which showed 1p/19q co-deletion and were thus classified as Oligodendrogliomas, IDH Mutant, 1p/19q co-deleted. However, on 30/32 (93.8%) cases, no further testing was done and these remained partially classified as Diffuse Gliomas, NOS, IDH Mutant. Out of the IDH1 negative cases (n= 39/105, 37.1%), IDH1 PCR was

only performed on 2/39 (5.13%) of these cases. One of them showed IDH1 positivity by PCR, with ATRX retained and 1p19q co-deletion and was diagnosed as Oligodendroglioma, IDH mutant, ATRX retained, 1p19q co-deleted. The other case was also IDH mutant by PCR with weak nuclear expression of ATRX. 1p19q co-deletion was not tested on this and was therefore partially classified as diffuse gliomas, NOS.

There were 39/135 (37.1%) cases which were IDH antibody negative. IDH by PCR was performed on 2/39 (5.1%) of them while on the rest (37/39, 94.9%), IDH PCR was not performed. These cases which were negative by IDH Antibody and on which IDH1 PCR was not performed (37/39, 94.9%), were further tested for ATRX and were categorised into 2 main groups based on ATRX results. Group A showed ATRX loss (n=12/37, 32.4%). These included n=10/12 (83.3%), grade II and n=2/12 (16.6%) grade-III tumours and although they were called Diffuse Glioma (NOS), Astrocytoma was morphologically favoured with complete workup for IDH advised to oncologists. Group B showed intact ATRX (n=25/37, 67.6%) and included n=14/25 (56%) grade II diffuse gliomas, NOS and n=11/25 (44%) grade III diffuse gliomas NOS.

Of the n=81/214 (37.9%) glioblastomas (fig-3), n=67/81 (82.7%) showed negative IDH1 (either by antibody or PCR) whereas n=14/81 (17.3%) were IDH mutant.

Overall, n=146/214 (68.2%) of the cases were completely classifiable including diffuse Astrocytomas, Oligodendrogliomas and Glioblastomas, as clearly illustrated in fig-3.

DISCUSSION

WHO 2016 CNS classification has incorporated molecular studies as an integral part of the classification of diffuse gliomas. In Pakistan, Shaukat Khanum Memorial Cancer Hospital and Research Centre is one of the rare institutes that have access to IDH antibody, ATRX antibody, PCR testing for IDH and 1p/19q co-deletion FISH studies. No local data is available on these molecular tests and the frequencies of various

subtypes of adult diffuse gliomas. This study aimed to assess, in our local setup, the categorization of adult diffuse gliomas after incorporating these molecular tests in the diagnostic process and assess the frequency of cases that were completely classifiable.

This study included 214 adult diffuse glioma cases from July 2015 to July 2017. Our study revealed temporal and parietal lobes as being the most common locations for occurrence of diffuse gliomas. Previous investigations included a large study of 987 gliomas from University Hospital Zurich which showed parietal lobe to be the most common site (34%) followed closely by temporal (31%), frontal lobe (23%) and least frequently the occipital lobe(16%)²¹. In our study, a subset of cases were only labelled for site as brain and exact location in the brain had not been specified.

IDH1/2 mutations are present in the majority of astrocytomas and oligodendrogliomas as well as secondary glioblastomas²¹. They are not seen in conditions such as vasculitis, encephalitis, demyelinating diseases or reactive gliosis, which can also at times mimic gliomas²². Also, as discussed earlier, their main importance lies in the fact that circumscribed gliomas such as pilocytic astrocytomas and angliogliomas are always IDH negative²³. IDH has been evaluated by two techniques: immunohistochemistry and PCR and two separate work flow charts depicting their results have been incorporated. This is because our institute acquired the IDH-PCR test before the IDH antibody.

When considering all IDH1/2 mutant diffuse gliomas, more than 90% show the R132 IDH1 type of mutation^{24,25}. Therefore, IDH1 specific antibody is an effective and rapid test for quick detection of the majority of IDH mutations. Of the IDH1 mutant cases, those that show ATRX loss were classified into final subcategories. Of the IDH1-mutant cases by immunohistochemistry (not all cases could be confirmed by IDH-PCR), 32 cases (44%) retained ATRX. FISH studies for 1p/19q co-deletion was only performed on 2 of these cases both of which showed

1p/19q co-deletion and were thus classified as Oligodendrogliomas, IDH Mutant, 1p19q co-deleted. However, in the other 30 cases, we faced difficulty in sub classifying them, as neither was IDH PCR nor FISH for 1p/19q co-deletion was performed on any of them. These partially worked up cases were classified as Diffuse Gliomas, NOS. Although not fully subcategorized, IDH mutant status along with the morphologic WHO grade of these tumors did give some prognostic information to the clinician to help plan management strategies

Another major group was of those cases on which IDH PCR was performed directly without the IDH antibody. This was because our institute acquired the IDH-PCR test before the IDH antibody. The majority of these cases were IDH mutant 26/28 (96%) and most of these were classifiable into subcategories. The majority was of Diffuse Astrocytomas followed by oligodendrogliomas. Those 2 cases which were IDH1 negative by PCR but showed ATRX loss, based on morphology and ATRX loss, astrocytoma was favoured morphologically. However, we recommend performing the complete IDH panel including sequence testing for IDH2. The reason for these cases being IDH negative by PCR might be due to the fact that the PCR being used by our institute only evaluates IDH1. IDH2 was not tested and it is possible that these two cases harboured IDH2 mutations.

LIMITATION OF STUDY

In our setup, due to hesitancy on the part of the patient/clinician for molecular testing most likely due to financial reasons and lack of familiarity with the current prognostic implications of these tests, it was not always possible to do the complete molecular workup in each case. Therefore, in a certain percentage of cases (31.8%), there was difficulty in classification and in such cases the WHO-recommended term of Diffuse Glioma, NOS was used.

ACKNOWLEDGEMENT

The authors will like to thank Mr. Usman Ayyub for technical assistance.

CONCLUSION

In this study, glioblastomas are the most frequent gliomas as categorized by current WHO molecular guidelines followed by diffuse astrocytomas. Oligodendrogliomas are the least common.

CONFLICT OF INTEREST

This study has no conflict of interest to be declared by any author.

REFERENCES

1. Senhaji N, Louati S, Chbani L, El Bardai S, Mikou K, Maaroufi M, et al. Prevalence of IDH1/2 Mutations in Different Subtypes of Glioma in the North-East Population of Morocco. *Asi Pacif J Cancer Preve ion* 2016; 17(5): 2649-53.
2. Mur P, Mollejo M, Hernández-Iglesias T, de Lope ÁR, Castresana JS, García JF, et al. Molecular classification defines 4 prognostically distinct glioma groups irrespective of diagnosis and grade. *J Neuropath Experi Neuro* 2015; 74(3): 241-09.
3. Perry A, Brat DJ. *Practical surgical neuropathology: a diagnostic approach*. Elsevier Health Sciences; 2010. <https://www.elsevier.com/books/practical-surgical-neuropathology-a-diagnostic-approach/9780323449410>.
4. Leeper HE, Caron AA, Decker PA, Jenkins RB, Lachance DH, Giannini C. IDH mutation, 1p19q codeletion and ATRX loss in WHO grade II gliomas. *Oncotarget* 2015; 6(30): 30295-05.
5. Coons SW, Johnson PC, Scheithauer BW, Yates AJ, Pearl DK. Improving diagnostic accuracy and interobserver concordance in the classification and grading of primary gliomas. *Cancer* 1997; 79(7): 1381-93.
6. Louis DN, Perry A, Reifenberger G, Von Deimling A, Figarella-Branger D, Cavenee WK, et al. The 2016 World Health Organization classification of tumors of the central nervous system: a summary. *Actaneuropathol* 2016; 131(6): 803-20.
7. Lai A, Kharbanda S, Pope WB, Tran A, Solis OE, Peale F, et al. Evidence for sequenced molecular evolution of IDH1 mutant glioblastoma from a distinct cell of origin. *J clini onco* 2011; 29(34): 4482-90.
8. Liu N, Wang P, Song H, Kong L, Yao K, Qi X. Immuno-staining of IDH-1 R132H and ATRX proteins in the classification of adult glioblastomas. *Int J Clin Exp Pathol* 2016; 9(12): 12849-54.
9. Cimino PJ, Zager M, mc Ferrin L, Wirsching HG, Bolouri H, Hentschel B, et al. Multidimensional scaling of diffuse gliomas: application to the 2016 World Health Organization classification system with prognostically relevant molecular subtype discovery. *Actaneuropathol Commun* 2017; 5(1): 39-42.
10. Nobusawa S, Watanabe T, Kleihues P, Ohgaki H. IDH1 mutations as molecular signature and predictive factor of secondary glioblastomas. *Clini Cancer Rese* 2009; 15(19): 6002-7.
11. Takano S, Ishikawa E, Sakamoto N, Matsuda M, Akutsu H, Noguchi M, et al. Immunohistochemistry on IDH 1/2, ATRX, p53 and Ki-67 substitute molecular genetic testing and predict patient prognosis in grade III adult diffuse gliomas. *Brain Tumor Path* 2016; 33(2): 107-16.
12. Chen JR, Yao Y, Xu HZ, Qin ZY. Isocitrate dehydrogenase (IDH) 1/2 mutations as prognostic markers in patients with glioblastomas. *Medici* 2016; 95(9).
13. Turkalp Z, Karamchandani J, Das S. IDH mutation in glioma: new insights and promises for the future. *J Am Med Assoc Neurol* 2014; 71(10): 1319-25.
14. Chesnelong C. Isocitrate Dehydrogenase (IDH) Mutation in Gliomas. In *Next Generation Sequencing in Cancer Research*. Springer 2015; 2(1): 441-58.
15. Liu XY, Gerges N, Korshunov A, Sabha N, Khuong-Quang DA, Fontebasso AM, et al. Frequent ATRX mutations and loss of expression in adult diffuse astrocytic tumors carrying IDH1/ IDH2 and TP53 mutations. *Actaneuropathol* 2012; 124(5): 615-25.
16. Kannan K, Inagaki A, Silber J, Gorovets D, Zhang J, Kastenhuber ER, et al. Whole exome sequencing identifies ATRX mutation as a key molecular determinant in lower-grade glioma. *Oncotarget* 2012; 3(10): 1194-03.
17. Ebrahimi A, Skardelly M, Bonzheim I, Ott I, Mühleisen H, Eckert F, et al. ATRX immunostaining predicts IDH and H3F3A status in gliomas. *Acta Neuropathol Commun* 2016; 4(1): 60-69.
18. Jenkins RB, Blair H, Ballman KV, Giannini C, Arusell RM, Law M, et al. A t (1; 19)(q10; p10) mediates the combined deletions of 1p and 19q and predicts a better prognosis of patients with oligodendroglioma. *Cancer Res* 2006; 66(20): 9852-61.
19. Cancer Genome Atlas Research Network. Comprehensive, integrative genomic analysis of diffuse lower-grade gliomas. *New Engl J Med* 2015; 372(26): 2481-98.
20. Killela PJ, Reitman ZJ, Jiao Y, Bettegowda C, Agrawal N, Diaz LA, et al. TERT promoter mutations occur frequently in gliomas and a subset of tumors derived from cells with low rates of self-renewal. *Proc Natl Acad Sci USA* 2013; 110(15): 6021-26.
21. Ostrom QT, Gittleman H, Farah P, Ondracek A, Chen Y, Wolinsky Y, et al. CBTRUS statistical report: Primary brain and central nervous system tumors diagnosed in the United States in 2006-2010. *Neuro-Oncol* 2013; 15(suppl_2): 111-56.
22. Camelo-Piragua S, Jansen M, Ganguly A, Kim JC, Louis DN, Nutt CL. Mutant IDH1-specific immunohistochemistry distinguishes diffuse astrocytoma from astrocytosis. *Acta Neuropathol* 2010; 119(4): 509-11.
23. Capper D, Weibert S, Balss J, Habel A, Meyer J, Jäger D, et al. Characterization of R132H Mutation specific IDH1 Antibody Binding in Brain Tumors. *Brain Pathol* 2010; 20(1): 245-54.
24. Dimitrov L, Hong CS, Yang C, Zhuang Z, Heiss JD. New developments in the pathogenesis and therapeutic targeting of the IDH1 mutation in glioma. *Int J Med Sci* 2015; 12(3): 201-13.
25. Reifenberger G, Wirsching HG, Christiane B. Thomsen K, Weller M. Advances in the molecular genetics of gliomas-implications for classification and therapy. *Nature Reviews Clin Oncol* 2016; 14(7): 434-52.