

INCIDENCE OF MICRO DETACHMENTS AFTER SUCCESSFUL SCLERAL BUCKLING SURGERY FOR MACULA-OFF RETINAL DETACHMENTS

Abdullah Naeem Syed, Isra Batool, Haleema Masud, Nadeem Qureshi

Al-Shifa Trust Eye Hospital, Rawalpindi Pakistan

ABSTRACT

Objective: To determine the incidence of micro detachments and change in mean height of persistent sub-retinal fluid (SRF) in eyes that underwent successful scleral buckling surgery for macula-off rhegmatogenous retinal detachment (RRD).

Study Design: Prospective cohort study.

Place and Duration of Study: Retina Department, Al Shifa Trust Eye Hospital Rawalpindi, from Jan 2016 to Dec 2016.

Methodology: Thirty two patients that underwent successful scleral buckling surgery for macula-off RD were included in the study. Pre-operative assessment including retinal examination by slit-lamp bio microscopy was carried out before surgery. Post-operative assessment included best corrected visual acuity (BCVA) with a Snellen chart and optical coherence tomography (OCT) by OCT Spectralis, Heidelberg Engineering. The post-operative assessment was performed at 1 week, 1 month, 3 months and 6 months after surgery.

Results: The incidence of micro detachments was 31.25% (10 patients) as detected by presence of sub-retinal fluid on optical coherence tomography at one week postoperative and 9.38% (3 patients) at six months after surgery while the base population was considered to be 32. The mean height of persistent sub-retinal fluid decreased significantly at all 4 time-points after the surgery. Mean height of SRF at 1 week, 1 month, 3 months and 6 months after surgery was $357.42 \pm 114.25\mu\text{m}$, $303.67 \pm 107.57\mu\text{m}$, $267.36 \pm 106.79\mu\text{m}$ and $240.45 \pm 19.77\mu\text{m}$ respectively.

Conclusion: Incidence of micro detachments decreased significantly after scleral buckling surgery up to a period of 6 months with only a small fraction of patients having persistent sub-retinal fluid after 6 months of surgery.

Keywords: Macula-off retinal detachment, Micro detachments, Scleral buckling surgery.

This is an Open Access article distributed under the terms of the Creative Commons Attribution License (<http://creativecommons.org/licenses/by/4.0>), which permits unrestricted use, distribution, and reproduction in any medium, provided the original work is properly cited.

INTRODUCTION

The purpose of retinal detachment (RD) surgery is to re-attach the retina and to reverse or prevent vision loss. Different kinds of surgeries including scleral buckling surgery, vitrectomy and pneumatic retinopexy can be used to re-attach the retina if the detachment is too large to be repaired by laser treatment or cryotherapy alone¹.

Despite successful surgery for macula-off RD and total retinal re-attachment on fundus examination, visual recovery may remain incomplete. Age of the patient², pre-operative visual acuity, the duration of the detachment, post-operative cystoid macular edema and epiretinal

membrane development may result in incomplete visual recovery after retinal detachment surgery³. Studies have shown that apart from these factors, long term persistence of sub-retinal fluid after buckle surgery maybe associated with limited post-operative visual acuity recovery. Minute levels of persistent sub-retinal fluid are documented by optical coherence tomography (OCT) after rhegmatogenous retinal detachment surgery to allow for a detailed retinal evaluation⁴.

In cases of persistent SRF after surgery, additional surgical treatment maybe required including diathermy or cryotherapy and the buckle maybe broadened or converted from a segmental to an encircling element with the hope of adequately treating a suspected but unrecognized break⁵. Whether or not scleral buckling is performed with drainage techniques, post-operative absorption of SRF should be assessed

Correspondence: Dr Abdullah Naeem Syed, Associate Professor, Al-Shifa Trust Eye Hospital, Rawalpindi Pakistan
Email: dransyed@hotmail.com

Received: 04 Jul 2017; revised received: 31 Oct 2019; accepted: 08 Nov 2019

properly. This will provide opportunities to the physician to deal with any complications that usually result after RD surgery including massive peri-retinal proliferation. So when the physician is familiar with conditions associated with prolonged SRF resorption even after adequate treatment, he can avoid unnecessary surgical treatment. Recognizing such cases in advance of the primary surgical approach may influence the physician's choice of treatment, as well as preoperative and postoperative discussions with the patients, and may allow a conservative approach after operation in the face of persistent sub-retinal fluid⁶.

In order to investigate a specific group of patients with successfully re-attached retinas, an OCT-based study was performed after buckle surgery for macula-off RD to determine the incidence and duration of persistent SRF.

METHODOLOGY

Ethical approval to conduct this study was taken from the Ethical Committee of Al Shifa Trust Eye Hospital, Rawalpindi, Pakistan. A cohort study was conducted at the Retina Clinic, Al Shifa Trust Eye Hospital, Rawalpindi from January 2016 to December 2016. A consecutive non-probability sampling technique was used to recruit the patients for this study. Sample size was not pre-determined, rather all patients who had undergone scleral buckling surgery by one surgeon during the mentioned time period were included in the study. A total of 32 patients (32 eyes) were evaluated at 1 week, 1 month, 3 months and 6 months after scleral buckling surgery. Informed consent was obtained from all the patients who participated in the study. The inclusion criteria of the study was patients of all ages and both genders who had macula-off RD with PVR A and B. Both fresh and old RD cases were included in the study. Exclusion criteria of the study was factors that could render the patients ineligible for the study such as eyes with closed funnel RD, PVR C or intra-operative gas temponade, hence such patients were excluded from the study.

All surgeries were done by one surgeon. After the positioning of an encircling silicone band, a circumferential or radial additional explant was positioned to close the break(s) if the break was not on to the buckle on retinal examination. All eyes underwent external SRF drainage followed by the application of cryotherapy around the retinal break(s).

Pre-operative assessment including retinal examination on slit lamp was performed before surgery. The patients were asked to come for a follow-up examination after 1 week of surgery, followed by 1 month, 3 months and then 6 months after surgery. The post-operative assessment was then performed which included BCVA and OCT to look for changes in VA and to con-

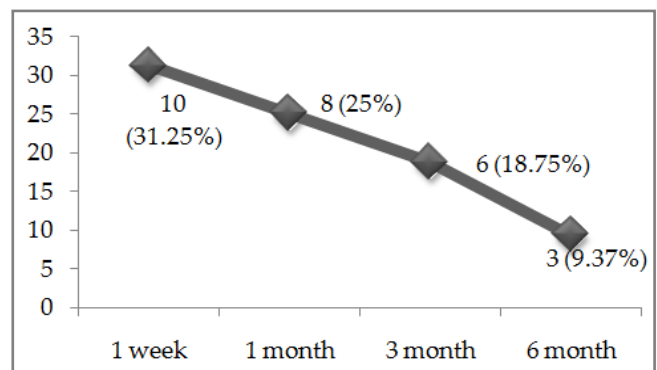


Figure: Proportion of patients with persistent SRF (micro detachments).

firm the presence of SRF. BCVA was measured with a Snellen chart at 6 meters. OCT images after surgery were obtained with Spectralis OCT (Heidelberg Engineering, Heidelberg, Germany), following a standardized protocol. Data at different time points was recorded on a proforma for each patient.

Statistical analysis was carried out using IBM SPSS statistics software version 17.0 to evaluate if there was persistent SRF in eyes after surgery. Statistical analysis was performed to compare the pre and post-op data for the incidence and levels of SRF. A p -value <0.05 was considered to be significant. Cochran's Q test was carried out to assess if there was significant change in the proportion of patients with persistent SRF across

four time points. ANOVA was used to analyze changes in the height of SRF after 1 week, 1 month, 3 months and 6 months of scleral buckling surgery. Before carrying out the test, assumptions of this test checked i.e. normality of the data were checked. Data was considered normally distributed as the absolute value of skewness

patients with age less than 15 years, 17 (53.12%) patients in age group 16-45 years and 11 (34.4%) patients were more than 45 years old.

The duration of retinal detachment ranged from 4 days to 5 years in the study participants. Fourteen patients (43%) had a detachment that

Table-I: Mean height of srf on oct after scleral buckling surgery.

Follow up time	n	Height of sub-retinal fluid		
		Mean ± SD	Minimum	Maximum
1 week	12	357.42 ± 114.25	202	617
1 month	12	303.67 ± 107.57	160	580
3 months	11	267.36 ± 106.79	127	550
6 months	11	240.45 ± 119.77	103	560

Table-II: Change in mean height of persistent srf after scleral buckling surgery.

Time Points	Mean Difference	p-value	95% Confidence Interval for Difference	
			Lower Bound	Upper Bound
1 week - 1 month	57.909	0.004	18.504	97.314
1 week - 3 months	102.727	0.001	61.602	143.853
1 week - 6 months	129.636	0.001	72.313	186.960
1 month - 3 months	44.818	0.003	15.506	74.130
1 month - 6 months	71.727	0.013	14.112	129.343
3 months - 6 months	26.909	0.129	-5.504	59.322

Table-III: Risk of not having a micro-detachment at 6 months after surgery.

History of retinal detachment	Micro-detachment		Cumulative Incidence	Risk Ratios	95% CI for Relative Ratios	
	Yes	No			Lower Bound	Upper Bound
Fresh retinal detachment	-	22 (100%)	22/22=1	1.43	0.95	2.14
Old retinal detachment	3 (30%)	7 (70%)	7/10=0.7			

Table-IV: History of retinal detachment and sub-retinal fluid levels at 6 months after surgery.

History of retinal detachment	n	Sub-retinal fluid Level (Mean ± SD)	p-value
Fresh retinal detachment	22	199 ± 40.1	0.226
Old retinal detachment	10	290 ± 167.9	

was <2 and histogram showed normal distribution. Data was also checked for the assumptions of sphericity by using Mauchly’s test of Sphericity. Greenhouse - Geisser correction was applied as assumption of sphericity was not met. Post-hoc test using Bonferroni correction was applied to assess the difference between the groups.

RESULTS

A total of 32 patients were recruited in the study, their mean age was 36.84 ± 20.06 years ranging from 4-75 years. There were 4 (12.5%)

was less than 15 days old. In another 14 patients, the duration of RD ranged from 1-8 months and in 4 patients the duration of RD ranged from 1-5 years. The duration of RD surgery ranged from 1-12 months in all the patients.

Majority of patients, 29 (90.6%) had symptomatic visual improvement after surgery. The mean Snellen BCVA was 0.33 ± 0.2 after 6 months of surgery.

The incidence of micro detachments was 31.25% (10 patients) as detected by presence of SRF in OCT at one week postoperative. The

proportion of patients having micro detachments was reduced at subsequent follow-ups (figure). Considering the base population of 32, the incidence at six months after the surgery was 9.34% (3 patients).

Cochran's Q test showed that the decrease in proportions was statistically significant, Cochran's Q (df=3) = 13.96, p -value <0.005.

The mean height of SRF was also measured across four time points. These time points were: after 1 week, 1 month, 3 months and 6 months of scleral buckling surgery (table-I).

Scleral buckling surgery was found to elicit a change in the mean height of persistent SRF across the 4 time-points (table-II), p <0.001. Post-hoc tests revealed that mean height of SRF significantly decreased across all time points after surgery however the difference in mean SRF from 3 to 6 months after surgery was not significant.

There was no significant effect of different age groups on persistent SRF after 6 months of surgery, p >0.1. The incidence of not having a micro-detachment 6 months after surgery was not significantly affected by duration of detachment history; risk ratios reported in table-III.

The SRF level was slightly lower among patients with fresh RD when compared with those who had old RD, however it was not statistically significant p >0.05 (table-IV).

DISCUSSION

It is known that persistent SRF occurs after successful SB surgery for macula-off RD. Two patterns of residual SRF have been identified, confluent and bleb-like pockets of fluid and it has been reported that fluid can take more than 12 months to resolve⁷. Both Wolfensberger and Benson *et al* reported that PSF occurred more frequently after buckling than after vitrectomy⁸⁻¹⁰. Fluid absorption proceeds very rapidly when the retinal breaks are closed, even without drainage of fluid, in many cases of rhegmatogenous retinal detachment. However it is still poorly understood why sub-retinal fluid takes months to resorb in certain cases⁵. Persistent SRF after SB

surgery may indicate the presence of small undetected and untreated holes in the retina which may call for additional surgery. It was suggested that scleral buckling might disturb the choroidal circulation and, consequently, impair SRF absorption¹¹. It has been demonstrated both by research and clinical practice that absorption of fluid is favored by forces like oncotic pressure gradient, an active retinal pigment epithelial pump and hydrostatic pressure^{1,12}.

A number of studies show the incidence of persistent SRF after SB surgery ranging widely from 9-94%¹³⁻¹⁵. In our study, OCT done post-operatively demonstrated that 3 out of 32 eyes (9.38%) with macula-off RD had persistent SRF up to 6 months after surgery. These results were in line with other studies with similar settings. Wang *et al*¹⁶ found persistent SRF on OCT in 100% of his patients with macula-off RRD at 2 weeks follow-up while the duration for the SRF to become undetectable ranged from 2-11 months (average 6.3 ± 2.3 months). In another study, Gharbiya *et al*⁷ evaluated that persistent SRF was found on OCT in 62.5% of eyes with macula-off RRD at 1 month follow-up.

It has been reported in studies that recovery of visual acuity may be slowed by persistent fluid, with improvement of visual acuity occurring as the fluid resolves^{5,12}. Studies have suggested that young age, phakia and long-standing inferior detachment can be risk factors for persistent SRF after SB surgery. However, there is no conclusive evidence about this¹². However, patients with persistent foveal detachment may have poor central vision. Even after successful scleral buckling surgery, metamorphopsia, poor visual acuity and loss of depth perception may persist for over a year¹⁷. Further damage to the retinal pigment epithelium is possible in cases of persistent fluid under the macula⁵. On the contrary, Ritesh Shah *et al* reported poor anatomical outcome in pseudophakic patients with RD which was due to capsular opacities leading to localization of retinal breaks or poor view of the retina¹⁸.

In this study, the average time for SRF to get absorbed completely was 3 months postoperatively. Results on OCT showed that the bleb height decreased significantly up to 3 months after surgery. SRF further decreased up to 6 months after surgery, however the results were not significant.

ACKNOWLEDGEMENT

The role of the staff of Retina Department and all the patients who participated in the study is acknowledged with much appreciation.

CONCLUSION

Successful scleral buckling surgery for retinal detachment was found to decrease the level of persisting SRF. This change occurs with time taking a period of about 6 months for the SRF to get absorbed completely in majority of patients. However, the relation of persisting SRF and its outcome on visual acuity is still a matter to be studied further.

CONFLICT OF INTEREST

This study has no conflict of interest to be declared by any author.

REFERENCES

1. Boyd K, Maturi RK. Retinal detachment: torn or detached retina treatment [Internet]. Retinal Detachment: Torn or Detached Retina Treatment ... American Academy of Ophthalmology; 2016. Available from: <https://www.aao.org/eye-health/diseases/detached-torn-retina-treatment>
2. Hirata N, Iwase T, Kobayashi M, Yamamoto K, Ra E, Terasaki H. Correlation between preoperative factors and final visual acuity after successful rhegmatogenous retinal reattachment. *Sci Rep* 2019; 9(1): 3217.
3. Abouzeid H, Becker K, Holz FG, Wolfensberger TJ. Submacular fluid after encircling buckle surgery for inferior macula-off retinal detachment in young patients. *Acta Ophthalmologica* 2009; 87(1): 96-99.
4. Leshno A, Barak A, Loewenstein A, Weinberg A, Neudorfer M. Optical density of subretinal fluid in retinal detachment. *Invest Ophthalmol Vis Sci* 2015; 56(9): 5432-38.

5. Al Rashaed S. Unusual presentation of residual subretinal fluid composition after surgery for acute rhegmatogenous retinal detachment. *Clin Ophthalmol* 2013; 7(1): 1069-72.
6. Robertson DM. Delayed absorption of subretinal fluid after scleral buckling procedures: the significance of subretinal precipitates. *Trans Am Ophthalmol Soc* 1978; 76(1): 557-83.
7. Gharbiya M, Malagola R, Mariotti C, Parisi F, De Vico U, Ganino C, et al. Spectral-domain optical coherence tomography analysis of persistent subretinal fluid after scleral buckling surgery for macula-off retinal detachment. *Eye* 2015; 29(9): 1186-88.
8. Wolfensberger TJ. Foveal reattachment after macula-off retinal detachment occurs faster after vitrectomy than after buckle surgery. *Ophthalmol* 2004; 111(7): 1340-43.
9. Benson SE, Schlottmann PG, Bunce C, Xing W, Charteris DG. Optical coherence tomography analysis of the macula after vitrectomy surgery for retinal detachment. *Ophthalmol* 2006; 113(7): 1179-83.
10. Benson SE, Schlottmann PG, Bunce C, Xing W, Charteris DG. Optical coherence tomography analysis of the macula after scleral buckle surgery for retinal detachment. *Ophthalmol* 2007; 114(1): 108-12.
11. Schwartz SG, Kuhl DP, McPherson AR, Holz ER, Mieler WF. Twenty-year follow-up for scleral buckling. *Arch Ophthalmol* 2002; 120(3): 325-29.
12. Veckeneer M, Derycke L, Lindstedt EW, Van Meurs J, Cornelissen M. Persistent subretinal fluid after surgery for rhegmatogenous retinal detachment: hypothesis and review. *Graefes Arch Clin Exper Ophthalmol* 2012; 250(6): 795-802.
13. Kaga T, Fonseca RA, Dantas MA, Yannuzzi LA, Spaide RF. Optical coherence tomography of bleb-like subretinal lesions after retinal reattachment surgery. *Am J Ophthalmol* 2001; 132(1): 120-21.
14. Hagimura N, Iida T, Suto K, Kishi S. Persistent foveal retinal detachment after successful rhegmatogenous retinal detachment surgery. *Am J Ophthalmol* 2002; 133(4): 516-20.
15. Wolfensberger TJ, Gonvers M. Optical coherence tomography in the evaluation of incomplete visual acuity recovery after macula-off retinal detachments. *Graefes Arch Clin Exp Ophthalmol* 2002; 240(2): 85-91.
16. Wang XY, Shen LP, Hu RR, Wei XU. Persistent subretinal fluid after successful scleral buckle surgery for macula-off retinal detachment. *Chinese Medical J* 2011; 124(23): 4007-11.
17. Huang C, Fu T, Zhang T, Wu X, Ji Q, Tan R. Scleral buckling versus vitrectomy for macula-off rhegmatogenous retinal detachment as assessed with spectral-domain optical coherence tomography: a retrospective observational case series. *Bio Med Central Ophthalmol* 2013; 13(1): 12-18.
18. Shah R, Byanju R, Pradhan S, Ranabhat S. Factors affecting the outcome of scleral buckling surgery for primary rhegmatogenous retinal detachment. *J Ophthalmol* 2018; 2018: 9016302.