

The Diagnostic Performance of the Circumpubertal Dental Maturation Phases for the Identification of Individual Specific Skeletal Maturation Phase using Mandibular Canine

Sumbal Hayat, Nasrullah Mengal, Fakhira Nizam, Munaza Saeed*

Department of Dentistry, Sandeman Provincial Hospital, Quetta Pakistan, *Department of Dentistry, Armed Forces Institute of Dentistry/ National University of Medical Sciences (NUMS) Rawalpindi Pakistan

ABSTRACT

Objective: To determine the correlation between circumpubertal dental maturation phase using mandibular canine and skeletal maturation phase for correct prediction of specific maturation phase in adults.

Study Design: Cross sectional study.

Place and Duration of Study: Department of Dentistry, Sandeman Provincial Hospital, Quetta Pakistan, from Jun to Dec 2019.

Methodology: Fifty individuals with permanent mandibular canine, either gender were included. Dental maturity was measured by applying the estimation of calcification phases of the mandibular canines by using Demirjian *et al.*, criteria. The skeletal maturity was determined by using method of maturation phase of cervical vertebra on lateral cephalograms.

Results: The mean age of individuals was 12.34 ± 6.55 years. There were 11 males and 39 females. There was significantly strong correlation observed between skeletal maturity and dental maturation of mandibular third molar i.e., $r=0.633$ ($p<0.001$).

Conclusion: Circumpubertal dental maturation phase is appropriate way for identification of individual specific maturation phase using mandibular canine.

Keywords: Cervical vertebral maturation, circum-pubertal dental maturation phase, mandibular canine, maturation phase.

How to Cite This Article: Hayat S, Mengal N, Nizam F, Saeed M. The Diagnostic Performance of the Circumpubertal Dental Maturation Phases for the Identification of Individual Specific Skeletal Maturation Phase using Mandibular Canine. *Pak Armed Forces Med J* 2023; 73(Suppl-1) S225-228. <https://doi.org/10.51253/pafmj.v73iSUPPL-1.4039>.

This is an Open Access article distributed under the terms of the Creative Commons Attribution License (<https://creativecommons.org/licenses/by-nc/4.0/>), which permits unrestricted use, distribution, and reproduction in any medium, provided the original work is properly cited.

INTRODUCTION

Skeletal maturity has the utmost significance to diagnose and better prognosis the appropriate orthodontic treatment option accepted in adolescent age.¹ It is well known that among growing individuals the facial skeletal dissonances or malocclusion, can be corrected by applying appropriate orthopedic method. Such skeletal malocclusion can be for example are transverse maxillary contractions, mandibular absence or prognathism. These features are comparatively common among different ethnicities or races.²

The recent indication of the consistency of growth signs for the correct estimation of the pubertal development emission while better effectivity of the functional therapy for skeletal malocclusion Class II, the scheduling of which depend on such indicators, is extremely contentious.³ Concerning growth indicators, the methods for hand and wrist maturation phase and recording of the standup height of individual seem to be most consistent. While other procedures are exposed to some controversies or had showed unreliable findings.⁴

Estimation of actual chronological age as well as

stage of maturation in children is mainly imperative in fields for example pediatrics, orthopedics & orthodontics, in addition to in forensic & anthropological studies.⁵ Effectiveness of a functional therapy and modification in growth, particularly to correct the Class II skeletal malocclusion, depends on the skeletal maturity assessment. Skeletal effects can be make best use of orthodontic treatment if it is done during pubertal growth emission, regardless whether temporary or permanent appliances are applied.^{6,7}

Consequently, struggles have been done to determine the reliable signs to predict the skeletal maturity in an individual subjects. Such indicators have comprised of cervical vertebral maturational method, radiographic hand-wrist maturational methods, 3rd finger middle phalanx method, dental maturation & dental emergence.^{8,9}

So we conducted this study to get the reliability evidence of circumpubertal dental maturation phase to measure the mandibular maturation before undergoing any procedure to determine the pubertal age and treatment can be planned accordingly. So this study would provide us the evidence which can help us to determine the maturation phase of an individual by using circumpubertal dental maturation phase instead of going for other maturation procedures.

Correspondence: Dr Sumbal Hayat, Department of Dentistry, Raisani Street No. 2, Saleh Mohammad Manzir Double Road, Quetta Pakistan
Received: 27 Mar 2020; revision received: 3 Jul 2020; accepted: 13 Jul 2020

METHODOLOGY

It was a cross sectional study conducted at the OPD of Department of Dentistry, SPH, Quetta Pakistan for 6 months i.e. June-Dec 2019. Sample size of 100 cases is estimated by using type I error 5%, type II error 10% and taking previously reported value of correlation coefficient i.e. 0.798 between skeletal growth and circumpubertal dental maturation phase of mandibular third molar. All the cases were included through Non-probability, consecutive sampling. Individuals of age range 8–16 years of both genders having permanent exposed mandibular teeth were included in the sample while individuals having hormonal, developmental, nutritional or dental growth problems were excluded from the study.

All the individuals were selected from OPD. Before enrollment of candidate in the study, written informed consent was obtained. All individuals had measurement of the dental maturity, which was done by applying the calcification phases of the mandibular canines as defined by Demirjian *et al.*, from stages D-H, detected on the panoramic x-rays of the left mandibular canine teeth and findings were recorded on proforma. Concisely, the stages are defined as follows:

Stage and Description	
D:	(1) Crown formation is complete down to the cemento-enamel junction, (2) pulp horns become visible, and (3) root formation begins in the form of a spicule.
E:	(1) Walls of the pulp chamber form straight lines, the continuity of which is broken by the presence of the pulp horn, which is larger than in the previous stage, (2) root length is less than crown height, and (3) root bifurcation begins to be visible
F:	(1) Walls of the pulp chamber form a more or less isosceles triangle, with the apex ending in a funnel shape and (2) root length is equal to or greater than crown height.
G*:	Walls of the root canal are parallel and its apex is slightly open.
H*:	(1) Apex is completely closed and (2) periodontal membrane has a uniform width around the root and apex.
GH:	Stages G and H pooled.
* Whenever possible, stages G and H have been assigned according to the distal root.*	

Figure-1: Staging of Tooth Maturation

Stage description	Attainment
CS1: lower borders of the second, third, and fourth vertebrae (C2, C3, and C4) flat and the bodies of C3 and C4 trapezoid in shape	At least 2 years before the pubertal growth spurt
CS2: only the lower border of C2 with concavity and the bodies of C3 and C4 trapezoid	About 1 year before the pubertal growth spurt
CS3: lower borders of C2 to C4 with concavities and the bodies of C3 and C4 either trapezoid or rectangular horizontal in shape	At coincidence of the ascending portion of the pubertal growth spurt
CS4: lower borders of C2 to C4 with concavities and the bodies of both C3 and C4 both (or at least one, [a]) rectangular horizontal	At coincidence of the descending portion of the pubertal growth spurt
CS5: lower borders of C2 to C4 with concavities and at least one or both of the bodies of C3 and C4 squared.	About 1 year after the pubertal growth spurt
CS6: lower borders of C2 to C4 with concavities and at least one or both of C3 and C4 rectangular vertical	At least 2 years after the pubertal growth spurt

Figure-2: Staging of Skeletal Maturity

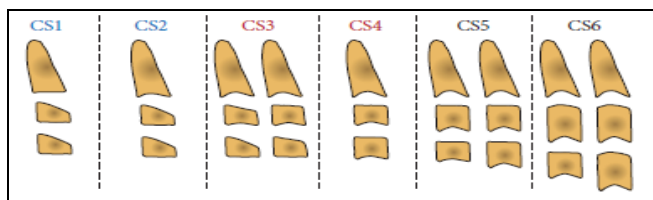


Figure-3: Diagram of Cervical Vertebral Maturation stages. Blue=Pre-Pubertal Stage; Red=Pubertal Stage; Black=Post-Pubertal Stage

Skeletal maturity was examined by using cervical vertebra maturation technique by using lateral cephalograms. This comprises of six stages, which are as follows. SPSS version 22 was used for analysis. Skeletal & dental maturity stages were presented as frequency.

RESULTS

The mean age of individuals was 12.34±6.55 years. There were 11 males and 39 females. There was significantly strong correlation observed between skeletal maturity and dental maturation of mandibular third molar i.e. $r=0.633$ ($p < 0.001$)

Table: Correlation of Dental Maturation of Canine with Skeletal Maturation in Growing Individuals (n=50)

Dental-maturation	n	Skeletal Maturation					
		CS1	CS2	CS3	CS4	CS5	CS6
D	20	20 (100%)	-	-	-	-	-
E	20	15 (75%)	5 (25%)	-	-	-	-
F	20	8 (40%)	6 (30%)	4 (20%)	2 (10%)	-	-
G	20	4 (20%)	5 (25%)	5 (25%)	5 (25%)	1 (5%)	-
H	20	2 (10%)	2 (10%)	3 (15%)	4 (20%)	4 (20%)	5 (25%)

Figure-4 showing the relationship of dental maturation with skeletal maturation. It showed a strong positive correlation between dental maturation stage and skeletal stage ($p < 0.05$).

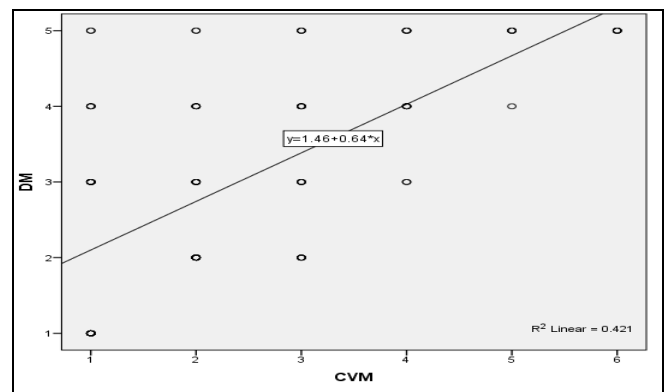


Figure-4: Correlation between Dental Maturity and Skeletal Maturity (n=50)

DISCUSSION

Human growth displays significant difference in chronological age at which every adolescent or child influences parallel developmental phenomena. Assessment of growth is very important for the estimation of age in the field of forensic science and for the growth modification in the orthodontics & dentofacial ortho-

paedics. Timings of orthopedic growth modification treatment is characteristically associated with individual's highest level of skeletal maturity to exploit the growth potential.¹⁰

The best time of application of an orthodontic treatment is still a controversial topic, as it has been under research for several decades with timely therapy to be notified or certainly to avert the skeletal divergences in the three longitudinal planes and to improve the assembling in routine dental practices. However, regarding to the effectiveness, generally idealizing an early interventions did not show superiority over to the late interventions.^{11,12} Assessment of dental maturation is the only suitable method for the diagnosis of prepubertal phase of growth, and therefore, detailed information about the timing of onset of growth spurt is not provided by these indexes.¹³

Interceptive orthodontics is very common all over the world. With the current advancement in investigative tools, innovative possible therapeutic tools and methods have been acknowledged. This method is developed as the deep-rooted policy and established numerous uses in the dental clinics or is in different clinical researches.¹⁴⁻¹⁶

Perinetti *et al.* found that the correlation of dental maturation stages with cervical vertebral maturation stages were $r=0.71$ for canines and $r=0.77$ for 2nd molars. This value was very close to that of our study which is 0.63 .¹⁷

Another study conducted by Dzemiczic *et al.* it was reported that the correlation of calcification stage of the mandibular canines with the skeletal maturity stage were $r=0.895$ for males and $r=0.701$ for females. It was concluded that the significant correlation exist for the calcification stage of the mandibular canines with the skeletal maturity stage. The calcification phase of mandibular canines showed the reasonable diagnostic presentation but only for evaluation of the prepubertal development phases.¹⁸

But according to the study, conducted by Lopes *et al.* the conclusions of the study were barely sustained by study results that are consistent with previous proof as a substitute that disappoints the application of the dental maturation phase to evaluate appropriate scheduling for the orthodontics treatment.¹⁹ The researchers acceptably reported that A high correlation coefficient does not provide information about whether the dental maturation stage is satisfactory for diagnostic identification of the skeletal maturation stage.¹⁹

None of the cervical vertebral maturation phase 2,3, & 4 touched the adequately diagnostic consistency for the detection of the coming up mandibular developmental peaks.²⁰ Though, the maximum momentous blockade to provide the interceptive orthodontics care by a dental practitioner is yet the absence of self-confidence relating to the efficiency of the selected therapeutic strategy.²¹

The matter of the proper exploration regarding the diagnostic consistency of dental maturation phase in the assessment of the developmental phases were elevated several decades ago, which recommended the utilization of proper investigative performance analysis rather than correlation analysis.² Out of all the diagnostic parameters, the likelihood ratio (positive) was introduced, which offers the approximation of how much the given dental maturation phase alters the probabilities of having the given developmental stage.²²

Information regarding the growth status of an individual is important to formulate and start an accurate treatment strategy.²³ Because of the disparities among different populations and ever varying circumstances, it is important to properly assess the growth phase of an individual.^{24,25} The awareness about early maturation of girls than boys has been recognized for several years. Girls also show the progressive increasing dentition.

CONCLUSION

Thus circumpubertal dental maturation phase is appropriate way for identification of individual specific maturation phase using mandibular canine. We found a significant strong correlation but further studies are required to be done on large sample size and more reliable results with other parameters also.

Conflict of Interest: None.

Author's Contribution

Following authors have made substantial contributions to the manuscript as under:

SH & NM: Data acquisition, data analysis, data interpretation, critical review, approval of the final version to be published.

FN & MS: Conception, study design, drafting the manuscript, approval of the final version to be published.

Authors agree to be accountable for all aspects of the work in ensuring that questions related to the accuracy or integrity of any part of the work are appropriately investigated and resolved.

REFERENCES

1. Sheikh S, Nene S, Kalia AJ, Gautam R, Hegde A, Thakur PP, et al. Relationship between age at menarche, body mass index

Circumpubertal Dental Maturation Phases

- percentile, and skeletal maturity stages in Indian female orthodontic patients. *APOS Trend Orthodont* 2019; 9(1): 32-39.
- Perinetti G, Westphalen GH, Biasotto M, Salgarello S, Contardo L. The diagnostic performance of dental maturity for identification of the circumpubertal growth phases: a meta-analysis. *Prog Orthodont* 2013; 14(1): 8.
 - Antony T, Amin V, Hegde S, Hegde S, Shetty D, Khan MB, et al. The evaluation and clinical efficiency of power scope: An original research. *J Int Soc Prevent Commun Dent* 2018; 8(3): 264.
 - Perinetti G, Contardo L. Reliability of growth indicators and efficiency of functional treatment for skeletal Class II malocclusion: current evidence and controversies. *BioMed Res Int* 2017; 2017: 1367691.
 - Diz Dios P, Limeres J, Salgado A, Tomás Carmona I, Delgado L, Vázquez E, et al. Correlation between dental maturation and chronological age in patients with cerebral palsy, mental retardation, and Down syndrome. *Res Develop Disab* 2011; 32: 808-817.
 - Perinetti G, Primožic J, Franchi L, Contardo L. Treatment effects of removable functional appliances in pre-pubertal and pubertal Class II patients: a systematic review and meta-analysis of controlled studies. *PloS one* 2015; 10(10).
 - Perinetti G, Primožic J, Furlani G, Franchi L, Contardo L. Treatment effects of fixed functional appliances alone or in combination with multibracket appliances: a systematic review and meta-analysis. *Angle Orthodont* 2015; 85(3): 480-92.
 - Perinetti G, Sbardella V, Contardo L. Diagnostic reliability of the third finger middle phalanx maturation (MPM) method in the identification of the mandibular growth peak. *Eur J Orthodont* 2017; 39(2): 194-201.
 - Perinetti G, Sossi R, Primožic J, Ierardo G, Contardo L. Diagnostic reliability of mandibular second molar maturation in the identification of the mandibular growth peak: A longitudinal study. *Angle Orthodont* 2017; 87(5): 665-671.
 - Mini M, Thomas V, Bose T. Correlation between dental maturity by demirjian method and skeletal maturity by cervical vertebral maturity method using panoramic radiograph and lateral cephalogram. *J Indian Acad Oral Med Radiol* 2017; 29: 362-367.
 - Fleming P. Timing orthodontic treatment: early or late? *Australian Dent J* 2017; 62(S1): 11-19. <https://doi.org/10.1111/adj.12474>.
 - Nakas E, Lauc T, Tiro A, Dzemiđić V, Zukanović A, Franic M, et al. Dose-and time-dependent effects of clodronate on orthodontic tooth movement. *Bosnian J Basic Med Sci* 2017; 17(1):23-28. <https://doi.org/10.17305/bjbm.2017.1715>.
 - Perinetti G, Contardo L, Gabrieli P, Baccetti T, Di Lenarda R. Diagnostic performance of dental maturity for identification of skeletal maturation phase. *Eur J Orthodont* 2012; 34(4): 487-492.
 - Borrie F, Bonetti D, Bearn D. What influences the implementation of interceptive orthodontics in primary care? *Br Dent J* 2014; 216(12): 687.
 - Baldini A, Nota A, Santariello C, Assi V, Ballanti F, Cozza P, et al. Influence of activation protocol on perceived pain during rapid maxillary expansion. *Angle Orthodont* 2015; 85(6): 1015-1020.
 - Perinetti G, Contardo L, Primožic J. Diagnostic accuracy of the cervical vertebral maturation method. *Eur J Orthodont* 2018; 40(4): 453-4. <https://doi.org/10.1093/ejo/cjy043>
 - Perinetti G, Contardo L, Gabrieli P, Baccetti T, Di Lenarda R. Diagnostic performance of dental maturity for identification of skeletal maturation phase. *Eur J Orthodont* 2012; 34(4): 487-492.
 - Dzemiđić V, Tiro A, Zukanović A, Redžić I, Nakas E. Skeletal maturity assessment using mandibular canine calcification stages. *Acta Med Acad* 2016; 45(2).
 - Lopes LJ, de Oliveira Gamba T, Visconti MAPG, Ambrosano GMB, Haiter-Neto F, Freitas DQ. Utility of panoramic radiography for identification of the pubertal growth period. *Am J Orthodont Dentofac Orthop* 2016; 149(4): 509-515.
 - Perinetti G, Primožic J, Sharma B, Cioffi I, Contardo L. Cervical vertebral maturation method and mandibular growth peak: a longitudinal study of diagnostic reliability. *Eur J Orthodont* 2018; 40(6): 666-672. <https://doi.org/10.1093/ejo/cjy018>
 - Tecco S, Baldini A, Nakaš E, Primožic J. Orthodontics in Growing Patients: Clinical/Biological Evidence and Technological Advancement 2018. *BioMed Res Int* 2018; 2018. <https://doi.org/10.1155/2018/7281846>
 - Perinetti G, Di Lenarda R, Contardo L. Diagnostic performance of combined canine and second molar maturity for identification of growth phase. *Prog Orthodont* 2013; 14(1): 1.
 - Kamal AT, Shaikh A, Fida M. Assessment of skeletal maturity using the calcification stages of permanent mandibular teeth. *Dent Press J Orthodont* 2018; 23: 44.e1-e8. <https://doi.org/10.1590/2177-6709.23.4.44.e1-8.onl>.
 - Singh S, Verma S. Orthodontics: Current principles and techniques. SAGE Publications Sage India: New Delhi, India; 2017, [internet] available at: https://www.researchgate.net/publication/316173680_Orthodontics_Current_Principles_and_Techniques
 - Graber LW, Vanarsdall RL, Vig KW, Huang GJ. Orthodontics-E-Book: current principles and techniques: Elsevier Health Sciences; 2016.
-