

ACCURACY OF ULTRASOUND IN DETECTION OF ANTERIOR CRUCIATE LIGAMENT TEAR OF KNEE IN COMPARISON TO MAGNETIC RESONANCE IMAGING

Adil Qayyum, Ruqqayia Adil, Zafar Amin*, Adeel Azhar, Tariq Aziz, Sarah Khan

Combined Military Hospital Multan/National University of Medical Sciences (NUMS) Pakistan, *Combined Military Hospital Bahawalpur/National University of Medical Sciences (NUMS) Pakistan

ABSTRACT

Objective: To determine the accuracy of ultrasound in detection of anterior cruciate ligament injury.

Study Design: Cross sectional validation study.

Place and Duration of Study: This study was carried out at Radiology department, Combined Military Hospital (CMH) Multan, from Nov 2017 to Jul 2018.

Methodology: Patients of both genders, 15 to 30 years age who sustained trauma to knee with clinical suspicion of anterior cruciate ligament (ACL) injury referred for magnetic resonance imaging (MRI) were include in the study. Ultrasound of knee was performed through ventral knee approach, followed by dynamic scan with ventral translation of tibia and findings for anterior cruciate ligament tear were recorded. This was followed by MRI and anterior cruciate ligament injury was documented.

Results: A total of 59 patients were referred from Orthopedic department of CMH Multan with clinical suspicion of anterior cruciate ligament tear for magnetic resonance imaging of knee. Ultrasound depicted positive results in 42 patients while magnetic resonance imaging scan confirmed presence of anterior cruciate ligament tear in 48 patients. Accuracy of ultrasound taking magnetic resonance imaging as gold standard was calculated to be 86.4%. Positive and negative predictive values, sensitivity and specificity were calculated. The comparison of results of ultrasound and magnetic resonance imaging showed statistically insignificant difference between the two imaging modalities ($p \leq 0.001$).

Conclusion: When combined with dynamic scanning, ultrasound was found a reliable diagnostic investigation due to its easily availability, high diagnostic accuracy and least invasive investigation for early diagnosis and prompt management.

Keywords: Anterior cruciate ligament injury, Knee joint injury, Magnetic resonance imaging, Ultrasonography.

This is an Open Access article distributed under the terms of the Creative Commons Attribution License (<http://creativecommons.org/licenses/by/4.0>), which permits unrestricted use, distribution, and reproduction in any medium, provided the original work is properly cited.

INTRODUCTION

Knee is most commonly injured joint by athletes with an estimated incidence of 2.5 million sports related injuries presenting to Emergency departments annually¹. Individuals with ages between 15 to 24 years had the highest rate for knee injury². The anterior cruciate ligament (ACL) is the most commonly injured knee ligament³ apart from other injuries. An estimated 70% of ACL injuries result through non-contact mechanisms, while the remaining 30% occur from direct trauma⁴. Accurate diagnosis of ACL

tear may be difficult clinically; however it is essential to give early treatment to avoid secondary changes of ACL tear to knee joint. ACL provides primary restraint to anterior translation of tibia and offers secondary stabilization in response to internal tibial rotation and to varus and valgus angulation⁵. ACL is torn most commonly in middle portion of the ligament, although this can occur at proximal and distal attachments on knee. The femoral attachment is weaker than the tibial attachment.

Magnetic resonance imaging (MRI) plays an important role in confirming the clinical suspicion, by defining the extent of ligament injury and diagnosing other associated lesions^{4,5}. MRI is currently considered noninvasive, gold

Correspondence: Dr Adil Qayyum, Asst Prof of Radiology, Combined Military Hospital, Multan Pakistan

Email: qayyum.adil@gmail.com

Received: 12 Oct 2018; revised received: 30 Jan 2019; accepted: 31 Jan 2019

standard modality for the detection of knee joint injuries, in contrast to invasive Arthroscopy. MRI may not be readily available in every setup; it has long waiting lists, long examination times and it is expensive^{6,7}. Ultrasound examination on the other hand is a simple, easily available, inexpensive and non-invasive imaging modality for the diagnosis of knee injury. It is increasingly used for the diagnosis of musculoskeletal soft tissue lesions and promises accurate diagnosis of such cases^{8,9}. Ultrasound has the advantage of combining dynamic clinical tests in real time with direct visualization of lesions or injuries.

Although currently used direct and indirect ultrasound methods can diagnose complete ruptures of the ACL and posterior cruciate ligament, they do not accurately diagnose partial ruptures. These methods have achieved a wide range of sensitivity varying from 79% to 92.6% and a specificity in the range of 60% to 98%, in comparison to non invasive gold standard investigation MRI¹⁰. Similarly, MRI has achieved about 89% sensitivity and 92% specificity, when compared to the invasive gold standard arthroscopy^{1,4}. Routinely, the cruciate ligaments are assessed on oblique sagittal MRI, with T2-weighted sequences. T2WS are associated with greater sensitivity, specificity, and accuracy for detection of ACL tear than are T1-weighted sequences.

Currently, there is no consensus regarding use of ultrasound for detection of ACL tear, because no consistent data for sensitivity and specificity of ACL injury has been proposed. To best of our knowledge, there was only scarce literature available on the diagnosis of anterior cruciate ligament injury by ultrasound and comparing the results with MRI. The objective of the present study was to observe whether ultrasound can be used effectively to evaluate the ACL injuries; and if MRI is not readily available in that setup, can it be used as first line imaging technique when ACL insufficiency is suspected. Early management can be started and patients can be filtered for MRI exam, if screened through ultrasound.

METHODOLOGY

This was a cross sectional validation study conducted at Radiology department, Combined Military Hospital Multan from November 2017 to July 2018. Sample was collected by non-probability purposive sampling and sample size was collected by CPSP calculator which appeared to be 59. After approval of ethical committee, a total of 59 patients with age ranging from 15 to 30 years who sustained trauma to knee joint were registered. All these patients were referred for MRI of knee joint with suspicion of ACL injury. Patients with previous history of injury to same knee joint, bleeding diathesis and any fracture around the injured knee were excluded from the study.

These patients had an Ultrasound scan of the injured knee prior to MRI, and findings regarding the ACL tear were recorded. This was followed by MRI scan of the same knee and presence or absence of ACL tear was documented. MRI was done through Toshiba Vantage Atlas 1.5 Tesla MRI machine using dedicated coil at knee. Ultrasound of ACL was performed through anterior knee approach, while patient is in lying supine. Toshiba Xario-100 machine was used, having Linear (10MHz) probe over infrapatellar region. Tear or discontinuity of ACL was recorded with adjacent secondary findings.

Ultrasound shows complete discontinuity of ACL fibers with wavy pattern of posterior cruciate ligament and adjacent joint effusion. Dynamic scan with anterior translation of tibial head was recorded during scan after posterior movement of leg. Tibial translation of >5 mm is significantly associated with ACL tears. MRI confirms presence or absence of ACL tear and was diagnosed on T2W sequences having complete discontinuity of ACL fibers in full thickness tear with adjacent secondary findings. All these findings along with demographic details were recorded on a separate proforma.

SPSS-23 for windows was used for data analysis. The continuous data such as age was described in terms of mean \pm SD while

frequencies or percentages were calculated for categorical variables like gender, presence or

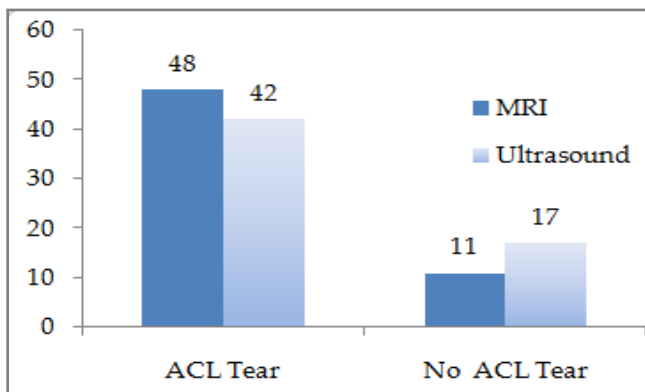


Figure-1: Frequency of anterior cruciate ligament Tear on Ultrasound and MRI (n=59).

absence of anterior cruciate ligament tear on Ultrasound & MRI scans and accuracy is calculated.

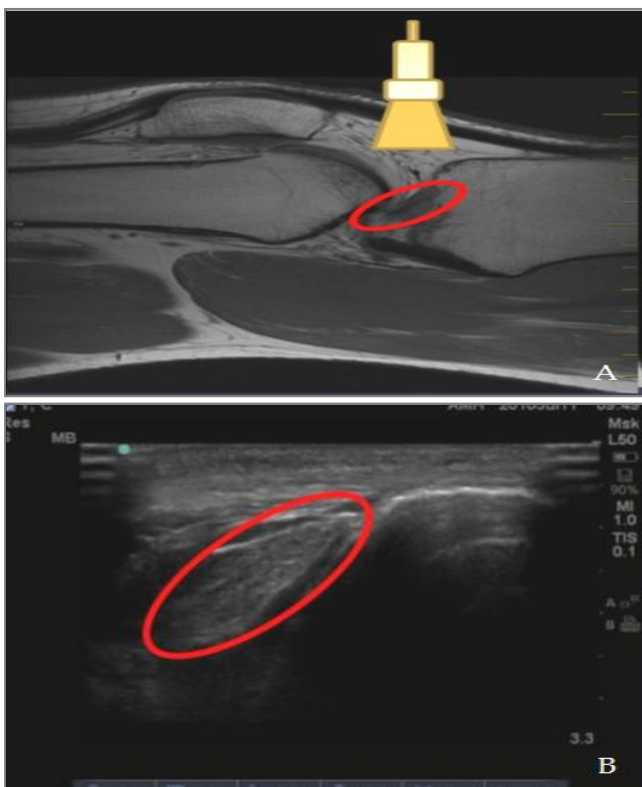


Figure-2: Sagittal MRI (A) for anterior cruciate ligament evaluation, in comparison to Ultrasound (B) for assessment of ACL tear.

All results are presented as table and/or figures. Mc Nemars test was applied. A *p*-value of <0.05 was taken significant.

RESULTS

A total of 59 patients were referred from Orthopedic department of CMH Multan, with suspected anterior cruciate ligament tear of knee for an MRI scan of knee. Fifty Six patients were males (95%), while 3 were female (5%). Right

Table-I: Evaluation of imaging findings of Ultrasound/MRI.

		MRI anterior cruciate ligament Tear		<i>p</i> -value
		Tear	No tear	
Ultrasound (ACL Tear)	Tear	n (%) 41 (85.4)	n (%) 1(9.1)	0.07
	No tear	7 (14.6)	10 (90.9)	

knee joint was more commonly involved in 31 patients (52.5%) in comparison to left knee in 28 patients (47.4%). Mean age of the patients were 21.53 ± 2.956 years. The results of ACL tear on ultrasound & MRI were depicted in fig-1.

Ultrasound confirmed presence of ACL tear

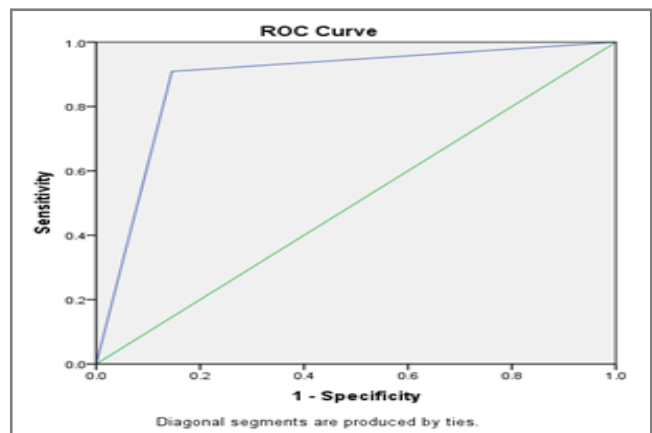


Figure-3: ROC curve through data & variables, depicting true positive and true negative cases of anterior cruciate ligament tears on Ultrasound vs MRI.

in 42 (71.1%) patients. However, MRI confirms presence of ACL tear in 48 (81.4%) patients. By ultrasound, 7 (11.9%) patients were misdiagnosed as false negative while 1 (1.7%) patient was misdiagnosed as false positive, taking MRI as a Gold standard. Dynamic scan with anterior translation of >5 mm of tibial head is significantly associated with ACL tears. MRI confirms ACL tear on T2W

sequences, having complete discontinuity of ACL fibers in full thickness tear (fig-2).

A 2x2 table showed of ultrasound and MRI results. The comparison showed statistically insignificant difference between the two imaging modalities ($p=0.070$). Accuracy of ultrasound taking MRI as gold standard was calculated to be 86.4%. Positive and negative predictive values were calculated according to formula. Figure-III showed receiver operating curve (ROC) through data & variables, depicting true positive and true negative cases of ACL tears on Ultrasound vs MRI.

Assuming MRI as gold standard, accuracy of Ultrasound was calculated as follows:

Sensitivity	= 85.4%
Specificity	= 90.9%
Positive Predictive value	= 97.6%
Negative Predictive value	= 58.8%
Diagnostic Accuracy	= 86.4%

DISCUSSION

Most of the injuries associated with anterior cruciate ligament (ACL) tear are generally sports-related with nearly three quarters being non-contact¹¹⁻¹⁴. The ACL is anatomically divided into anteromedial and posterolateral bundles and its main action is to limit forward slip of tibia over femur. Internal derangement of knee joint is a term used for presence of either ACL, posterior cruciate ligament, or meniscal injury and associated with amount of knee joint effusion^{15,16}. There is a growing need in orthopedic practice for any easily available diagnostic method that would assess ACL tear in simple and accurate way. This paper presents the possibility of using ultrasound in ACL injury directly observing the ligament tear and assessment during dynamic exam.

MRI is a noninvasive technique that remains a clinician's first choice for the clinical diagnosis of ACL injury with sensitivity ranging from 73% to 100% and specificity ranging from 68% to 100%¹⁷. A meta-analysis carried out by Oei *et al*

defined the specificity and sensitivity of MRI in detecting ACL injuries as 94.4% (95% CI: 92.3-96.6) and 94.3% (95% CI: 92.7-95.9), respectively¹⁸, which is similar to our study. In an acute complete ACL tear, the primary signs are most valuable and include non-visualization or discontinuity of the ligament, with abnormal increased T1 and T2 signals because of edema and hemorrhage; abnormal morphology such as a thickening, wavy, or retracted appearance; and angulation towards the horizontal plane¹⁹. Secondary signs include anterior tibial translation greater than 5 mm, acute hemarthrosis and buckling of posterior cruciate ligament. Most of these primary and secondary signs were also detected in our study. MRI is expensive and sometimes unavailable in some setups as a routine diagnostic tool. Limitation of MRI is also artifacts due to metallic implant placement. This can decrease the efficiency of the cruciate ligaments evaluation²⁰. MRI is less accurate in the detection of chronic ACL disruption.

Most of the patients referred to our department for MRI were males (95.5%). Sensitivity and specificity of Ultrasound in detecting ACL injury of knee in this study is 85.4% and 90.9% respectively. Accuracy of ultrasound in this regards was found as 86.4% as compared to MRI. These findings are in concordance with the previous similar literature of Friedl *et al*²¹. Though our study showed that ultrasound is less accurate in diagnosing ACL injury of knee with 86.4% accuracy in comparison to MRI, this difference has not been found statistically significant ($p=0.079$). Ultrasound examination of knee joint allows dynamic assessment in various positions and different methods are suggested to be used in assessing a traumatic knee joint²². Lateral wall of Intercondylar notch can be localized on transverse view and ACL rupture can be diagnosed associated with hematoma on posterior aspect.

The great advantage of ultrasound is its ability to assess the dynamic range of motion in a quantitative manner. Gebhard *et al*²³ uses dynamic scan with features of the Lachman test and the anterior drawer test allowing for reliable knee assessment under sonographic control. We also

performed dynamic scan during knee movement in our patients, which also showed >5mm tibial head ventral translation in ACL tear patients, and can be compared with contralateral normal knee. There is a great variance of absolute knee joint laxity in population and difference between two knees of the same patient gives more information than the absolute translation²⁴.

Luhmann *et al* in their studies concluded that almost 90% of acute knee injury patients were found to have both knee effusion and internal derangement, as confirmed by MRI²⁵. We also observed secondary findings during our scans and are noted on proforma. Hypothesis mentioned in the article is true, as there is statistically insignificant difference between ultrasound and MRI for diagnosing ACL tear ($p < 0.001$).

CONCLUSION

Ultrasound can be used as first line imaging technique when MRI is not readily available. When combined with dynamic scanning, was found to be remarkable investigation with high accuracy and many advantages such as giving an early clue, easily availability, least costly and least invasive investigation for diagnosis and immediate management purpose.

CONFLICT OF INTEREST

This study has no conflict of interest to be declared by any author.

REFERENCES

- Martínez HLE, Hernández DC, Pegueros PA. Subclinical findings in the knees of taekwondo athletes: diagnostic ultrasound study. *Gac Med Mex* 2014; 150 (suppl-2): 259-65.
- Orlando N, Souza LD, Oliveira NH. Diagnosis of knee injuries: Comparison of the physical examination and magnetic resonance imaging with the findings from arthroscopy. *Revistabrasileira de ortopedia* 2015; 50(6): 712-19.
- Brady MP, Weiss W. Clinical Diagnostic Tests versus MRI Diagnosis of ACL Tears. *J Sport Rehabil* 2018; 27(6): 596-600.
- Sarfraz S, Ahmed S. Diagnostic efficacy of magnetic resonance imaging in evaluation of injured knee. *Pak J Med Health Sci* 2013; 7(1): 144-48.
- Antunes LC, Souza JMG, Cerqueira NB, Dahmer C, Tavares BAP. Evaluation of clinical tests and magnetic resonance imaging for knee meniscal injuries: correlation with video arthroscopy. *Revista Brasileira de Ortopedia* 2017; 52(5): 582-88.
- Ahmad M, Ayub Z, Hadi N. Prevalence of various types of intra-articular injuries detected by Magnetic Resonance Imaging in trauma to the knee joint. *J Med Sci* 2005; 13(2): 136-9.
- Devitt BM, O'Sullivan R, Feller JA, Lash N, Porter TJ. MRI is not reliable in diagnosing of concomitant anterolateral ligament and anterior cruciate ligament injuries of the knee. *Knee Surg Sports Traumatol Arthrosc* 2017; 25(4): 1345-51.
- Xia XP, Chen HL, Zhou B. Ultrasonography for meniscal injuries in knee joint: A systematic review and meta-analysis. *J Sports Med Physical fitness* 2016; 56(10): 1179-87.
- Pobozy T, Kielar M. A review of ultrasonographic methods for the assessment of the anterior cruciate ligament in patients with knee instability - diagnostics using a posterior approach. *J Ultrason* 2016; 16(66): 288-95.
- Grzelak P, Podgorski M, Stefanczyk L, Domzalski M. New sonographically guided test for anterior knee instability-preliminary report. *J Ultrason* 2014; 14(58): 252-7.
- Donell ST, Marshall TJ, Darrach C, Shepstone L. Cruciate ligament assessment in MRI scans: a pilot study of a static drawer technique. *Knee* 2006; 13(2): 137-44.
- Li K, Du J, Huang LX, Ni L, Liu T, Yang HL. The diagnostic accuracy of magnetic resonance imaging for anterior cruciate ligament injury in comparison to arthroscopy: A meta-analysis. *Sci Rep* 2017; 7(1): 75-83.
- Kosy JD, Schranz PJ, Patel A, Anaspure R, Mandalia VI. The magnetic resonance imaging appearance of the anterolateral ligament of the knee in association with anterior cruciate rupture. *Skeletal Radiol* 2017; 46(9): 1193-1200.
- Faruch BM, Cavaignac E. Anterolateral ligament injuries in knees with an anterior cruciate ligament tear: Contribution of ultrasonography and MRI. *Eur Radiol* 2018; 28(1): 58-65.
- Cavaignac E, Faruch M, Wytrykowski K, Constant O. Ultrasonographic Evaluation of Anterolateral Ligament Injuries: Correlation With Magnetic Resonance Imaging and Pivot-Shift Testing. *Arthroscopy* 2017; 33(7): 1384-90.
- Iqbal MN, Idrees Z, Najjad MKR, Noor SS. The Hand or the Scan: The best modality for diagnosing Internal Knee derangements. *Pak J Surg* 2015; 31(3): 208-12.
- Bari AA, Kashikar SV, Lakhkar BN, Ahsan MS. Evaluation of MRI versus arthroscopy in anterior cruciate ligament and meniscal injuries. *J Clin Diagn Res* 2014; 8(12): 14-8.
- Oei EH, Nikken JJ, Verstijnen AC, Ginai AZ, Myriam Hunink MG. MR imaging of the menisci and cruciate ligaments: A systematic review. *Radiol* 2003; 226(3): 837-48.
- Khan HA, Ahad H, Sharma P, Bajaj P, Hassan N. Correlation between magnetic resonance imaging and arthroscopic findings in the knee joint. *Trauma Mon* 2015; 20(1): e18635.3.
- Irrazaval S. Gross Arthroscopic and radiographic anatomies of the anterior cruciate ligament: Foundations for anterior cruciate ligament surgery. *Clin Sports Med* 2017; 36(1): 9-23.
- Friedl W, Glaser F. Dynamic sonography in the diagnosis of ligament and meniscal injuries of the knee. *Arch Orthop Trauma Surg* 1991; 110(3): 132-38.
- Lee SH, Yun SJ. Diagnosis of simultaneous acute ruptures of the anterior cruciate ligament and posterior cruciate ligament using point of care ultrasound in the emergency department. *J Emerg Med* 2018; 54(3): 335-8.
- Gebhard F, Authenrieth M. Ultra-sound evaluation of gravity induced anterior drawer following anterior cruciate ligament lesion. *Knee Surg Sports Traumatol Arthrosc* 1999; 7(3): 166-72.
- Grzelak P, Podgorski M, Stefanczyk L, Domzalski M. Ultrasonographic test for complete anterior cruciate ligament injury. *Indian J Orthop* 2015; 49(2): 143-49.
- Wang CY, Wang HK, Hsu CY, Shieh JY, Wang TG. Role of sonographic examination in traumatic knee internal derangement. *Arch Phys Med Rehabil* 2007; 88(8): 984-87.