

Endoscopic Pilonidal Sinus Treatment (EPSiT) Vs Total Excision with Primary Closure (EPC) for Pilonidal Sinus Disease in Combined Military Hospital Rawalpindi

Muhammad Ali Muazzam, Syed Mukarram Hussain*, Muhammad Tanvir Ahmed Quraishi**

Combined Military Hospital Quetta/National University of Medical Sciences (NUMS) Pakistan, *Combined Military Hospital/National University of Medical Sciences (NUMS) Rawalpindi Pakistan, **Armed Forces Post Graduate Medical Institute/National University of Medical Sciences (NUMS) Rawalpindi Pakistan

ABSTRACT

Objective: To compare endoscopic pilonidal sinus treatment (EPSiT) vs total excision with primary closure (EPC) for pilonidal sinus disease in Combined Military Hospital Rawalpindi regarding intra and post-operative outcomes.

Study Design: Comparative cross-sectional.

Place and Duration of Study: Department of Surgery, Combined Military Hospital Rawalpindi, from Sep 2017 to Aug 2018.

Methodology: A total of 94 patients, all male patients were included. All 94 have primary pilonidal sinus; Patient were randomized in a double-blind study to undergo EPSiT or EPC by non-probability, consecutive sampling into two equal groups.

Results: The mean \pm age SD of patients was 28 years \pm 2.6 years. All patients completed the follow-up. All 94 patients divided equally for EPSiT and EPC. The patients completed the follow-up. All 94 patients divided equally for EPSiT and EPC. Surgery duration of EPSiT with a median duration of 34.5 minutes (IQR 30-39) and EPC 40.5 minutes (IQR 35-46); The median hospital stay was 8.5 hours (IQR 4-14) in EPSiT and 21.5 hours (IQR 15-28) in EPC. Complete wound healing in EPSiT was 93.6% and EPC was 81%. Wound complication rate was lower for EPSiT 3 (6.3%) and 8 (17%) or EPC (p-value 0.108). One case of wound dehiscence reported in EPC. Recurrence occurred in EPSiT was 3(6.3%) and EPC 9(19.1%).

Conclusions: In our experience, EPSiT was viable as EPC in the treatment of pilonidal sinus.

Keywords: Excision with primary closure, Endoscopic pilonidal sinus treatment, Pilonidal sinus.

How to Cite This Article: Muazzam MA, Hussain SM, Quraishi MTA. Endoscopic Pilonidal Sinus Treatment (EPSiT) Vs Total Excision with Primary Closure (EPC) for Pilonidal Sinus Disease in Combined Military Hospital Rawalpindi. Pak Armed Forces Med J 2022; 72(Suppl-2): S127-131. DOI: <https://10.51253/pafmj.v72iSUPPL-2.3304>

This is an Open Access article distributed under the terms of the Creative Commons Attribution License (<https://creativecommons.org/licenses/by-nc/4.0/>), which permits unrestricted use, distribution, and reproduction in any medium, provided the original work is properly cited.

INTRODUCTION

Pilonidal Sinus (PS) is a tiny track, arising from an infectious source. It opens to the overlying skin with a discharge. It is an agonising condition for the patients. It is a frequent health problem of the sacrococcygeal region, occurring mainly in young men, it is linked with BMI, inactive lifestyle, regional irritation, and hirsutism. It is considered an acquired ailment resulting from blockade of hair follicle in natal groove.¹

This disease has substantial impact on life quality, causing absenteeism from work and school. The several surgical options and the variable results suggest that perfect surgical management is still being searched for, and number of observed recurrences leaves much room for improvement. The best operating procedure should exterminate cyst and should clean and eradicate the sinus tracts. Open excision and healing by secondary intention is used as treatment option, but this technique offers a meagre postoperative life quality and needs frequent clinical observation, as reported in

the literature.²

Conversely, the gold standard seems to be Pilonidal Sinus excision with primary closure, using different techniques—mainly midline closure or flap-based procedures.^{3,4,5} These surgical modalities have variable results with different healing times and complications.

In a recent meta-analysis, Enriquez-Navascues *et al*,³ reported a wide range of recurrence rates, from 0-40%, for different surgical approaches, concluding that in the treatment of PS, “less is more.” Over the past decade, for other colorectal procedures, as well, some surgeons have suggested new least invasive procedures in the management of PS, such as radiosurgery,⁴ fibrin glue injection,⁵ and, more recently, endoscopy.

The latter was proposed by Meinerio *et al*,⁶ who developed a dedicated fistuloscope with the possibility of destroying the sinus cavity and sinus tracts under direct vision through an operative channel, and by Milone *et al*,⁷ who used a hysteroscope. The minimally invasive approach has been named endoscopic pilonidal sinus treatment (EPSiT), adding a possible effective tool for this disease.^{8,9}

Correspondence: Dr Muhammad Ali Muazzam, Department of Surgery, Combined Military Hospital Quetta-Pakistan

Received: 12 Oct 2019; revision received: 24 Jun 2020; accepted: 26 Jun 2020

Despite the huge morbidity associated with pilonidal sinus disease, there is still an open debate on the optimal treatment and management associated with the best patient outcome. Hence, this study was undertaken in order to study the possible benefits and disadvantages of the EPSiT.

This study aimed to determine the efficacy, safety and potential benefits of EPSiT compared to conventional treatment for pilonidal sinus in CMH Rawalpindi.

METHODOLOGY

A total of 94 male patients consulted surgical OPD of CMH Rawalpindi. Study was conducted from Sep 2017 to Aug 2018. The sample size was calculated with the Open EPI sample size calculator, with a pilonidal disease prevalence of 0.7%,¹⁰ confidence level of 99.9%, and margin of error to be 5%, for a population size of greater than one million. The calculated sample size was 43. After approval from ethical review board and informed consent from all patients

Inclusion Criteria: Patients who had primary pilonidal sinus were included in the study.

Exclusion Criteria: Non-consenting patients were excluded.

Patients were divided into two equal groups to undergo EPSiT or EPC. Postsurgical complications, wound infection, recurrence rate and time until return to work were logged during follow-up or at the last interview. Complication free post-operative duration was presumed in lack of stated symptoms after recovering. Long term data composed of pain history, abscess formation, wound infection and dehiscence. Main completion point of our study was complete wound healing, as defined by the through epithelization of surgical site.

Disease recurrence was considered when symptoms and signs such as discharge occurred after an interval following complete wound healing. Secondary end-points were healing time, procedure duration and occurrence of intra and postoperative complications, such as wound infection or dehiscence. Healing time defined as time to complete wound epithelization. Patients were selected in a non-probability, consecutive sampling double-blind way to undergo EPSiT and EPC procedures. Antibiotic prophylaxis (Cefotaxime 1g) was administered half hour before surgery.

All EPSiT and EPC procedures were performed by Classified Surgical Specialist of one-year experience of both procedures and senior surgery resident under direct supervision. All patients underwent an elective

surgery procedure under spinal anaesthesia while prone, with the buttocks separated by two large plasters. This study was not supported by any commercial company.

EPSiT is performed with a fistuloscope manufactured by Karl Storz (Southbridge, Massachusetts, USA). The kit consists of electrode connected to electrosurgical knife power unit, endobrush, tongs along with a Volkmann spoon. Fistuloscope has 8° angle eyepiece attached with optical conduit 14 cm long with a handle, an operative channel, and an irrigation channel. The latter channel was attached to a 1000-mL bag containing a solution of normal saline.

The EPSiT technique comprises of 02 phases; diagnostic phase, necessary to characterize tract anatomy and the operative phase, in which there is intraluminal destruction and removal of waste material. During the diagnostic phase, fistuloscope is introduced from the exterior opening, and sinus cavity and fistula's tract are identified. In operative stage, an electrode is introduced through the pathway, and cavity and fistula's tract are ablated. All the granulation tissue is destroyed and removed by a brush inserted into the operative channel or by a Volkmann spoon. If hairs are identified during the procedure, they are removed with tongs designed for that purpose inserted through the operative channel. The continuous lavage of the washing solution allows full elimination of debris and the blood (Figure-1 & 2).

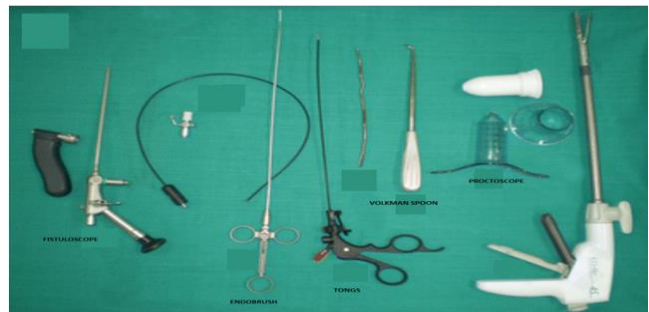


Figure-1: Intraoperative view of EPSiT set.

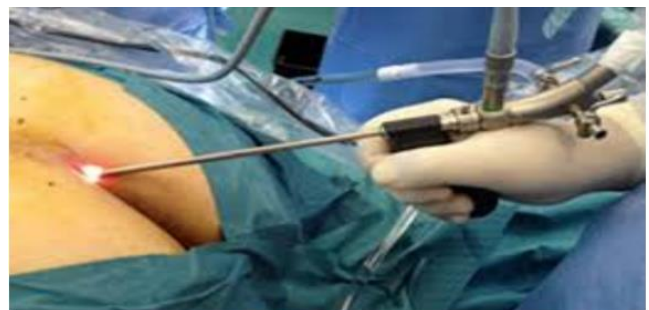

Figure-2: Introduction of fistuloscope through exterior opening.

For the conventional management group, EPC was carried out with non-absorbable sutures. After both the surgeries, compressive dressing was used.

Patients were admitted on the operation day. In case of no post-surgery complication, patients were discharged on same day. All the participants were guided to change dressing daily, take care of cleanliness of wound site and to remove hair after epithelization of site. After EPSiT, no constraints of daily activity were advised. However, after EPC, 15 days of bed rest was advised. Collected data was analysed using SPSS-23. Descriptive analysis was executed for all variables. The continuous variables were presented as median with interquartile ranges. The categorical variables were presented as frequency and percentages. The chi-square was used to find association between categorical variables. The *p*-value <0.05 was considered statistically significant.

RESULTS

During our study period 94 male patients were enrolled with a mean age of 28 years ± 2.6 years admitted through surgical OPD of CMH at Rawalpindi. The patients completed the follow-up. All 94 patients divided equally for EPSiT and EPC. Surgery duration of both sets was comparable with a median duration of 34.5 minutes (IQR 30-39) and 40.5 minutes (IQR 35-46) respectively. The median hospital stay was 8.5 hours (IQR 4-14) in EPSiT and 21.5 hours (IQR 15-28) in EPC respectively. The median number of days required to return to work in EPSiT was 4.5 days (IQR 2-7) and in EPC group it was 12 days (IQR 8-16). The median healing time was also comparable for EPSiT 29 days (IQR 22-36) and EPC 40 days (IQR 28-53) respectively. The median study follow-up was 10.5 months (IQR 8-13) for the EPSiT group and 11.5 months (IQR 9-14) for EPC group (Table-I & -II).

Table-I: Operative outcomes of patients in group EPSiT n=94.

Operative Outcomes	Median	IQR
Surgery duration in minutes	34.5	30-39
Hospital Stay in Days	8.5	4-14
Time to Return to Work in Days	4.5	2-7
Time to Complete Healing in Days	29	22-36
Patient Follow-up in Months	10.5	8-13

Table-II: Operative outcomes of patients in group EPC n=94.

Operative Outcomes	Median	IQR
Surgery duration in minutes	40.5	35-46
Hospital Stay in days	21.5	15-28
Time to return to work in days	12	8-16
Time to complete healing in days	40	28-53
Patient Follow-up in months	11.5	9-14

Overall full wound healing was reported as 82 (87%), with 44 (93.6%) in EPSiT and 38 (81%) in EPC (*p*-value 0.06). Postoperative wound complication was reported in 11 (11.7%), wound complication rate was lesser for EPSiT 3 (6.3%) and 8 (17%). Wound infection for EPSiT is 1 (2.1%) and EPC 2 (4.2%) (*p*-value 0.344) wound dehiscence rate was found in EPC patients.

Overall disease recurrence was reported in 12 (12.7%) with three patients in the EPSiT group (6.3%) versus nine patients in EPC group (19.1%) (*p*-value 0.06).

In EPSiT group, the recurrence was reported after 79, 85 and 103 days. In EPC group, the mean time ± SD for recurrence was 180 ± 5.6 days for recurrence. Recurrent cases of EPSiT were resubmitted to EPSiT with thorough wound healing at 10th, 15th and 4th weeks postoperatively respectively (Table-III).

Table-III: Postoperative outcomes of patients in group EPSiT and EPC n=94.

Post-operative Outcomes		EPSiT(47) n (%)	EPC(47) n (%)	<i>p</i> - values
Post-Operative Wound Complications	Present	3 (6.3%)	8 (17%)	0.108
	Absence	44(93.6%)	39 (83%)	
Wound Infection	Present	1 (2.1%)	2 (4.2%)	0.344
	Absent	46(97.9%)	45(95.8%)	
Wound Dehiscence	Present	-	1 (2.1%)	0.314
	Absent	47 (100%)	46(97.9%)	
Recurrence	Yes	3 (6.3%)	9 (19.1%)	0.06
	No	44(93.7%)	38(80.9%)	
Complete Wound Healing	Yes	44(93.6%)	38 (81%)	0.06
	No	3 (6.3%)	9 (19.1%)	

DISCUSSION

Pilonidal sinus (PS) is considered an insidious disease. Surgical management is still debatable. A lot of studies have debated that the area of pilonidal sinus should be completely excised, and also surgeons' debate about primary closure or layopen technique.^{3,10,11}

In a study by Kumar *et al*,⁹ it was reported that open excision and healing by secondary intention leads to lower recurrences (recurrence rate nil) but is associated to a longer hospitalization and longer healing time (60 ± 9.6 days).

Better outcome was observed following primary closure.¹²⁻¹⁴ The major problems in these series are the high rates of infection and recurrence.^{15,16}

A recent meta-analysis by Enriquez-Navascules *et al*,³ compared different techniques with primary closure and conservative open management, and concluded that en bloc or radical excision with off-midline

wound closure offers some benefits, but a higher risk of recurrence (75% vs 25%) comparing to open healing.

In a previous study, comparing EPSiT and Limberg flap surgery for PS, EPSiT total complication rate of 11.5% while Limberg flap group complication rate of 26.5% were demonstrated.¹⁷

Obviously, these percentages offer large room for improvement and the need of an alternative, less invasive procedure. The use of an endoscope may represent a solution allowing a simple and complete diagnosis of all fistula tracts if present, followed by the intraluminal eradication of the cyst, its contents, and the tract itself. Moreover, there is no scar, because the external orifice is used.

In addition Meinero *et al*,⁶ reported a multicentre series of 250 patients treated with EPSiT, showing a success rate close to 95% also safe and effective even for complex recurrent PS.^{11,17} Giarratano *et al*, reported overall satisfaction rate of 97%.¹⁸

In review EPSiT case study, Tien T, *et al*, demonstrated EPSiT has good complete healing rate and low recurrences.¹⁹ An EPSiT case study in Asian Population, shows Satisfaction rate was 78%.^{20,21}

Postoperative outcomes of EPC patients were in accordance to literature, which reported wound complication and recurrence rate of 20% and 19-25% respectively (VS 17% and 19.1%). On the other hand, in our study dehiscence rate of 2.1% was observed as compared to some studies reporting up to 56%.¹⁶ It may be due to use of deep tension sutures, with better holding ability.

Regarding EPSiT, our post-surgical results are analogous to those stated in a previous study, 94.8% thorough healing and 5% recurrence rate 10 (vs 93.6% and 6.3%).²²

EPSiT offers the possibility of obtaining the complete obliteration of the sinus cavity and sinus tracts and hair removal under direct vision and subsequent closure of the primary sinus with a negligible incision and minimal discomfort. The success rate of >90% is similar to the best reports of the open technique according to a recent metaanalysis,²³ but without the need for longer hospitalization, pain, and prolonged interruption of daily activities. EPSiT can be carried out as single day operation with early return to workplace with minimal pain and no postoperative infection or wound dehiscence.^{8,20} The open,¹⁴ and flap procedures,¹⁵ are associated with poor patient satisfaction because of the presence of a large scar. On the

other hand, the endoscopic approach offers very good aesthetic results, since the scar is 5 mm, no suture stitches are present, and no tension is present. While analysing in a study Milone, *et al*, demonstrated fewer infections (1 [1.3%] vs 5 [7.2%]) in the minimally invasive treatment group.²³

Less discomfort, no scar, earlier recovery and return to day-to-day doings, and lesser chances of wound dehiscence or recurrence may describe higher satisfaction rate observed in our study. Furthermore, this technique can be easily repeated, and, in cases with recurrence, patients, if well informed, prefer to repeat the minimally invasive treatment rather than being immobilized for weeks after a traditional treatment.

CONCLUSION

In the present study, experience with endoscopic pilonidal sinus treatment (EPSiT) was found to be more effective in comparison with the total excision with primary closure (EPC) for the treatment of pilonidal sinus disease.

Conflict of Interest: None.

Authors' Contribution

MAM.; Direct Contribution, SMH.; MTAQ: Intellectual contribution.

REFERENCES

1. De Parades V, Bouchard D, Janier M, Berger A. Pilonidal sinus disease. *J Visc Surg* 2013; 150(4): 237-247.
2. Segre D, Pozzo M, Perinotti R, Roche B. Italian society of colorectal surgery. The treatment of pilonidal disease: guidelines of the Italian Society of Colorectal Surgery (SICCR). *Tech Coloproctol* 2015; 19(10): 607-613.
3. Enriquez-Navascues JM, Emparanza JI, Alkorta M, Placer C. Meta-analysis of randomized controlled trials comparing different techniques with primary closure for chronic pilonidal sinus. *Tech Coloproctol*. 2014; 18(10): 863-872.
4. Gupta PJ. Radio Surgery in pilonidal sinus: a new approach for the old problem. *Acta Chir Belg*. 2005; 105(2): 183-186.
5. Isik A. The use of fibrin glue without surgery in the treatment of pilonidal sinus disease. *Int J Clin Exp Med* 2014; 7(4): 1047-1051.
6. Meinero P, Mori L, Gasloli G. Endoscopic pilonidal sinus treatment (E.P. Si.T.). *Tech Coloproctol* 2014; 18(4): 389-392.
7. Milone M, Musella M, Di Spiezio Sardo A. Video-assisted ablation of pilonidal sinus: a new minimally invasive treatment—a pilot study. *Surg* 2014; 155(3): 562-566.
8. Jain Y, Javed MA, Singh S, Joshi H. Endoscopic pilonidal abscess treatment: a novel approach for the treatment of pilonidal abscess. *Ann R Coll Surg Engl* 2017; 99(2): 134-136.
9. Kumar R, Hastir A, Walia R, Goyal S, Kaur A. Prospective randomized study of surgical treatment of pilonidal sinus; primary midline closure after elliptical excision versus rhomboid excision with limberg flap reconstruction versus open excision and healing by secondary intention. *Int Surg J* 2017; 4(11): 3646.
10. Brasel KJ, Gottesman L, Vasilevsky CA. Members of the evidence-based reviews in surgery group. Meta-analysis comparing healing by primary closure and open healing after surgery for pilonidal sinus. *J Am Coll Surg* 2010; 211(3): 413-414.

Endoscopic Pilonidal Sinus Treatment

11. Meinero P, Stazi A, Carbone A, Fasolini F, Regusci L, La Torre M. Endoscopic pilonidal sinus treatment: a prospective multicenter trial. *Colorectal Dis* 2016; 18(5): 164-170.
 12. Topgul K, Ozdemir E, Kilic K, Gokbayir H, Ferahkose Z. Long-term results of Limberg flap procedure for treatment of pilonidal sinus: a report of 200 cases. *Dis Colon Rectum* 2003; 46(11): 1545-1548.
 13. Theodoropoulos GE, Vlahos K, Lazaris AC, Tahteris E, Panoussopoulos D. Modified Bascom's asymmetric midgluteal cleft closure technique for recurrent pilonidal disease: early experience in a military hospital. *Dis Colon Rectum* 2003; 46(9): 1286-1291.
 14. Rao MM, Zawislak E, Kennedy R, Gilland R. A prospective randomized study comparing two treatment modalities for chronic pilonidal sinus with a 5-years follow-up. *Int J Colorectal Dis* 2010; 25(3): 395-400.
 15. El-Khadrawy O, Hashish M, Ismail K, Shalaby H. Outcome of the rhomboid flap for recurrent pilonidal disease. *World J Surg* 2009; 33(5): 1064-1068.
 16. Smíd D, Novák P, Liska V, Treska V. Pilonidal sinus surgical management at our surgical clinic. *Rozhl Chir* 2011; 90(5): 301-305.
 17. Meinero P, La Torre M, Lisi G, Stazi A, Carbone A, Regusci L, Fasolini F. Endoscopic pilonidal sinus treatment (EPSiT) in recurrent pilonidal disease: a prospective international multicenter study. *Int J Colorectal Dis* 2019; 34(4): 741-746.
 18. Giarratano G, Toscana C, Shalaby M, Buonomo O, Petrella G, Sileri P. Endoscopic Pilonidal Sinus Treatment: Long-Term Results of a Prospective Series. *JSLS* 2017; 21(3): e2017.00043.
 19. Tien T, Athem R, Arulampalam T. Outcomes of endoscopic pilonidal sinus treatment (EPSiT): A systematic review. *Tech Coloproctol* 2018; 22(5): 325-331.
 20. Velotti N, Manigrasso M, Di Lauro K, Araimo E, Calculli F, Vertaldi S, Arnoldo P, Aprea G, Simone G, Vitiello A, Musella M, Milone M, De Palma GD, Milone F, Sosa Fernandez LM. Minimally invasive pilonidal sinus treatment: A narrative review. *Open Med* 2019; 14(1): 532-536.
 21. Kalaiselvan R, Bathla S, Allen W, Liyanage A, Rajaganeshan R. Minimally invasive techniques in the management of pilonidal disease. *Int J Colorectal Dis* 2019; 34(4): 561-568.
 22. Chia CL, Tay VW, Mantoo SK. Endoscopic pilonidal sinus treatment in the Asian population. *Surg Laparosc Endosc Percutan Tech* 2015; 25(3): 95-97.
 23. Milone M, Fernandez LM, Musella M, Milone F. Safety and efficacy of minimally invasive video-assisted ablation of pilonidal sinus: A randomized clinical trial. *JAMA Surg* 2016; 151(6): 547-553.
 24. Romaniszyn M, Swirta J, Walega P. Long-term results of endoscopic pilonidal sinus treatment vs Limberg flap for treatment of difficult cases of complicated pilonidal disease: A prospective, nonrandomized study. *Colorectal Dis* 2019; 22(3): 319-324.
-