

## CLINICAL AND LABORATORY FEATURES OF ANCA ASSOCIATED VASCULITIS: EXPERIENCE AT A TERTIARY CARE HOSPITAL IN LAHORE, PAKISTAN

Muhammad Zeeshan Aslam, Asadullah Kakar, Haseeb Ahmed Khan, Saira Elaine Anwar khan

Fatima Memorial Hospital, Lahore Pakistan

### ABSTRACT

**Objective:** To determine the clinical and laboratory features during the disease course in patients of anti cytoplasmic antibody (ANCA) associated vasculitis in Pakistani patients presenting to a tertiary care center.

**Study Design:** Case series.

**Place and Duration of Study:** Fatima Memorial Hospital Shadman Lahore, from Dec 2018 to Mar 2019.

**Methodology:** A collection of 20 patients regarding demographic data, constitutional symptoms, mucocutaneous symptoms and signs, upper respiratory symptoms, lower respiratory symptoms, orbital and ocular manifestation, cardiovascular, peripheral vascular manifestation, central and peripheral neurologic manifestation, abdominal manifestation and renal manifestation

**Results:** Sixteen patients (80%) had a diagnosis of Granulomatosis with Polyangiitis, and 4 patients (20%) were of microscopic polyangiitis. The most common systemic involvement in descending order were constitutional symptoms (75%), ear nose and throat symptoms (50%), renal (50%), respiratory (45%), ocular (40%) and neurologic (40%). Most common laboratory abnormalities in our patients included leukocytosis (45%), anemia (35%), hematuria (50%), proteinuria (45%), and elevated serum creatinine (45%). Cytoplasmic-anti cytoplasmic antibody (C-ANCA) was positive in 11 (55%), all cases were of granulomatosis with polyangiitis, P-ANCA was positive in 5 (25%) of all patients, with 4 (100%) in Microscopic polyangiitis. Analysis of Granulomatosis with Polyangiitis according to gender and cytoplasmic-anti cytoplasmic antibody status showed correlation of renal involvement with cytoplasmic-anti cytoplasmic antibody status with statistical significance of  $p=0.036$ . Plain chest X-rays showed infiltrates in 2 (10%), nodularity 2 (10%), cavitation in 2 (10%), effusion in 1 (5%), and reticulonodular showing in 1 (5%) patients. High-resolution computed tomography findings included ground-glass opacification in 5 (25%) and Cavitory lesions in 4 (20%).

**Conclusion:** Granulomatosis with polyangiitis was found to be the more prevalent form of anti cytoplasmic antibody associated vasculitis in our population, with upper respiratory, lower respiratory ocular and neurologic symptoms being the common manifestations. A significant proportion of granulomatosis with polyangiitis is anti cytoplasmic antibody negative, with renal involvement being its common manifestation.

**Keywords:** Anti cytoplasmic antibody associated vasculitis, Eosinophilic granulomatosis with polyangiitis, Granulomatosis with polyangiitis, Microscopic polyangiitis.

---

This is an Open Access article distributed under the terms of the Creative Commons Attribution License (<http://creativecommons.org/licenses/by/4.0>), which permits unrestricted use, distribution, and reproduction in any medium, provided the original work is properly cited.

---

### INTRODUCTION

Antineutrophil cytoplasmic antibodies associated vasculitis (AAV) is a heterogeneous group of vasculitic disorders in which there is necrotizing inflammation of small and medium vessels. These comprise of Granulomatosis with Polyangiitis (GPA), Microscopic Polyangiitis (MPA) and Eosinophilic Granulomatosis with Polyangiitis (EGPA)<sup>1,2</sup>. These disorders differ from each other in Clinical as well as Laboratory Features

(ANCA pattern and histopathology of involved organs)<sup>3</sup>. GPA manifests mainly with upper and lower respiratory tract manifestations like epistaxis, paranasal sinus involvement, nasal crusting, recurrent otitis media, sensorineural and conductive hearing loss, mastoiditis, proptosis, subglottic stenosis, saddle nose, cavitation and/or nodular lesions on lung imaging<sup>4</sup>. It can also involve kidneys. MPA mainly presents as a pulmonary-renal syndrome and/or mono neuritis multiplex and vasculitic rash<sup>5</sup>. EGPA can present as a constellation of the above-mentioned signs and symptoms with additive features of asthma,

---

**Correspondence:** Dr Muhammad Zeeshan Aslam, Department of Rheumatology, Fatima Memorial Hospital, Lahore Pakistan

Received: 05 Aug 2019; revised received: 27 Jan 2020; accepted: 12 Feb 2020

systemic vasculitis, and eosinophilia<sup>6</sup>. These conditions also differ in their immunological pattern of ANCA antibodies. There are two patterns of ANCA antibodies, cytoplasmic ANCA (c-ANCA) directed against proteinase-3 (PR3) and perinuclear ANCA (p-ANCA) directed against myeloperoxidase (MPO). C-ANCA is commonly associated with GPA while p-ANCA is commonly associated with MPA and EGPA but any pattern can be seen in these conditions<sup>7</sup>. ANCAs are found in 90% of GPA patients, 70% of MPA patients and 45% of EGPA patients<sup>8</sup>. However, there are a few cases in which both c-ANCA and p-ANCA are negative<sup>9</sup>. With the introduction of immunosuppressants, the survival of this fatal disease has improved up to 79% at 5 years<sup>10</sup>. It is usually treated with high dose corticosteroids along with immunosuppressants and/or immunomodulators like cyclophosphamide or rituximab<sup>11,12</sup>.

We present here, a cohort analysis of patients of ANCA associated vasculitis. We sought to characterize clinical characteristics and laboratory features of these vasculitides.

## METHODOLOGY

It was a prospective case series of 20 consecutive patients in the out-patient and in-patient department of Fatima Memorial Hospital (FMH), which is a tertiary care hospital Lahore Pakistan. All patients with clinical features and laboratory parameters of AAV were included in the study from December 2018 to March 2019. The study was approved by the Institutional Review Board of FMH (IRB # FMH-11-2018-IRB-550-M) and informed consents were obtained from all patients.

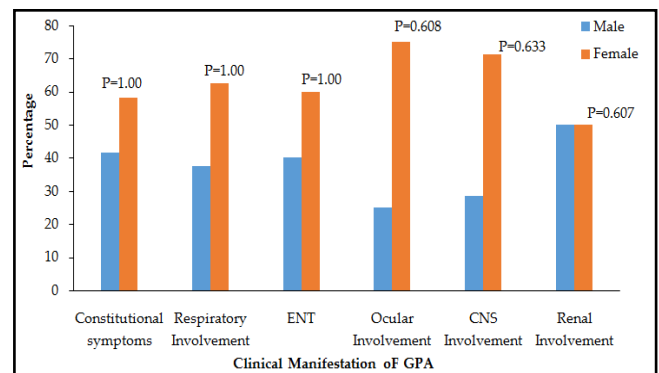
We collected data of 20 patients regarding demographic data, constitutional symptoms, mucocutaneous symptoms and signs, upper respiratory symptoms, lower respiratory symptoms, orbital and ocular manifestation, cardiovascular, peripheral vascular manifestation, central and peripheral neurologic manifestation, abdominal manifestation and renal manifestation. Laboratory investigations performed included complete blood picture, erythrocyte sedimentation rate (ESR), C-reactive protein (CRP), urine complete

examination, liver and kidney function tests. Immune markers such as RA-Factor, ANA, c-ANCA, p-ANCA, PR3-ANCA, MPO-ANCA. In addition, data of HRCT findings, imaging of upper or lower respiratory tract and biopsy of kidneys were collected. Data regarding treatment provided was collected as synthetic DMARDs, corticosteroids, Cyclophosphamide therapy, Rituximab, and plasmapheresis. Systems patterns at disease onset and during follow-up were analyzed.

Statistical analysis was performed by SPSS using version 25. All the categorical were presented in the form of frequency and percentage whereas quantitative variables were presented in the form of Mean  $\pm$  SD. Association between gender and C-ANCA positivity with clinical manifestation was assessed by Chi-square or Fisher's Exact test. Mann Whitney U test was applied for the comparison of the age for gender.

## RESULTS

Out of 20 patients included in the study, 12 (60%) were female and 8 (40%) were males (fig-1). The mean age was  $44 \pm 15.28$  years. Sixteen patients (80%) had a diagnosis of Granulomatosis with Polyangiitis (GPA), and 4 patients (20%) were of microscopic polyangiitis (MPA), while



**Figure-1: Clinical manifestation of GPA according to gender.**

ENT= Ear, nose and throat. P value of each manifestation is given above the specific bar.

there was no patient of Eosinophilic Granulomatosis with Polyangiitis (EGPA). Patients with MPA were of the earlier age of onset (mean  $37.5 \pm 23.0$  years) as compared to patients with GPA

(mean  $43.19 \pm 13.5$  years) with a non significant  $p$ -value of 0.637. Besides, there was no statistical difference in AAV subgroups in gender ( $p$ -value 1.00).

In overall cohort, the most prevalent systemic involvement in descending order was ENT involvement in 10 (50%) patients, renal involvement 10 (50%), respiratory involvement in 9 (45%), ocular involvement 8 (40%) and neurologic involvement 8 (40%). Cardiovascular, cutaneous and gastrointestinal manifestations were present in less than 4 (20%) patients.

Constitutional symptoms of fever, arthralgia, and myalgia were present in 15 (75%) of patients. Myalgia and arthralgia were more confined to

**Table-I: Clinical characteristics of different types of ANCA associated vasculitis.**

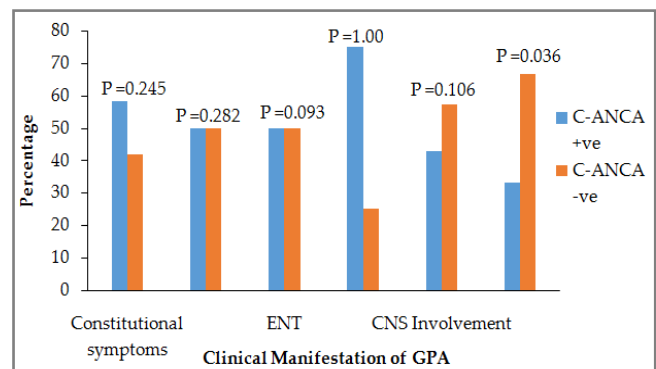
Characteristics	GPA (n=16)	MPA (n=4)	$p$ -value
Age (Mean $\pm$ SD)	45.19 $\pm$ 13.53	39.5 $\pm$ 23.01	0.637
<b>Gender</b>			
Male	6 (37.5%)	2 (50%)	1.00
Female	10 (62.5%)	2 (50%)	
Constitutional Symptoms	12 (75%)	3 (75%)	1.00
ENT Involvement	10 (62.5%)	-	0.087
Renal Involvement	6 (37.5%)	4 (100%)	0.087
Respiratory Involvement	8 (50%)	1 (25%)	0.591
Ocular Involvement	8 (50%)	-	0.117
Neurological Involvement	7 (43.8%)	1 (25%)	0.619
Gastrointestinal Involvement	-	3 (75%)	0.004
Cardiovascular Involvement	2 (12.5%)	-	1.00
Skin Manifestation	1 (6.3%)	1 (25%)	0.368

GPA=Granulomatosis with polyangiitis, MPA=Microscopic polyangiitis, ENT=Ear, nose, throat.

GPA as compared to MPA being 10 (62.5%) vs 2 (50%) and 9 (56.3%) vs 0% respectively. Ear, nose and throat (ENT) involvement in 10 (62.5%) in form of earache, conductive deafness or ear discharge, saddle nose deformity, chronic sinusitis; ocular involvement in 8 (50%) in the form of uveitis, scleritis, proptosis, vasculitis; and cardiovascular involvement in the form of ischemic heart

disease were all confined to GPA alone ( $p$ -values of 0.08, 0.17 and 1.00 respectively). Neurological involvement consisting of headache, neuropathy, and cerebrovascular accident was more prominent in GPA than MPA being prevalent in 7 (43%) vs 1 (25%) patients with a  $p$ -value 0.629; while renal involvement was a more prominent feature of MPA ( $p$ -value 0.004) being present in 4 (100%) vs 6 (37.5%); similarly GIT involvement in 3 (75%) vs 0% was a more prominent feature of MPA ( $p$ -value 0.004). A total of 2 patients (10%) had a cutaneous manifestation in the form of purpura and gangrene (table-I).

Analysis of GPA patients with positive clinical manifestation according to gender and C-ANCA status is shown in fig-1 & 2 respectively. Only renal involvement showed a statistically significant association with C-ANCA status. ANCA negative vasculitis consisting of 5 (25%)



**Figure-2: Clinical manifestation of GPA according to C-ANCA positivity.**

ENT=Ear, nose and throat  $p$ -value of each manifestation is given above the specific bar.

showed relatively earlier age of onset (33.4 vs 44 years), all patients had constitutional symptoms with fever and arthralgia being most prevalent (80% each). There was respiratory involvement in 4 patients (80%); renal involvement in 4 patients (80%  $p$ -value of 0.036); ENT and ocular involvement in 2 patients (40%); and no GIT, Cardiac, or CNS manifestation.

The most common hematological abnormalities in our patients included leukocytosis in 9 (45%), followed by anemia in 7 (35%); there was no case of thrombocytopenia. Mean ESR was 10

mm higher in cases of GPA as compare to MPA (32 mm/hr vs 23.7mm/hr). Urinary abnormalities in the form of hematuria and proteinuria were present in 10 (50%) and 9 (45%) of the cases respectively. Forty five percent of the patients showed elevated serum creatinine. Immunological features included rheumatoid factor (RAF) positivity in 25% of patients, and anti nucleic acid (ANA) antibodies positive in 20%. C-ANCA was positive in 11 patients (55%) all of whom were cases of GPA while P-ANCA was positive in 5 patients (25%) of which one patient was of GPA (table-II).

**Table-II: Laboratory characteristics of different AAV.**

Lab Parameter	GPA	MPA	p-value
Anemia	4 (25%)	3 (75%)	0.10
Leukocytosis	6 (37.5%)	3 (75%)	0.28
ESR (mean)	32.3	23.7	0.60
Raised Creatinine	6 (37.5%)	3 (75%)	0.28
Proteinuria	6 (37.5%)	4 (100%)	0.08
Hematuria	5 (31.3%)	4 (100%)	0.02
RAF positive	4 (25%)	1 (25%)	1.00
ANA positive	2 (12.5%)	2 (50%)	0.16
C-ANCA positive	11 (68.8%)	-	0.02
P- ANCA positive	1 (6.3%)	4 (100)	0.00

ESR = Erythrocytes sedimentation rate, RAF = Rheumatoid factor, ANA = Anti nucleic acid antibody, ANCA = anti cytoplasmic antibody.

Plain chest X-rays were reported normal in 12 (60%) patients; infiltrates in 10%, nodularity in 10% and cavitations in 10%; effusion in 5% and reticulonodular shadows in 5% of patients. The most common high-resolution computed tomography (HRCT) included ground-glass opacification (25%) followed by cavitatory lesions (20%); consolidation, nodularity, and effusion were present in 1 case each.

Five (25%) patients underwent a renal biopsy. All cases showed pauci-immune glomerulonephritis. Three out of the five cases were patients of GPA, 2 of which showed crescentic glomerulonephritis and presented clinically as rapidly progressive glomerulonephritis (RPGN). Remaining two biopsies were of patients of MPA which showed focal necrotizing glomerulonephritis.

## DISCUSSION

We presented here the case series of 20 patients reporting the clinical and laboratory manifestation of AAV. GPA was more prevalent (60%) than MPA (40%) in our study. Ocular, ENT, respiratory, and renal manifestation were the prominent involvement of GPA, while renal, gastrointestinal involvement being prominent features of MPA. The localized form of GPA was ANCA negative. C-ANCA was more positive in GPA and P-ANCA in MPA respectively.

Our results are in concordance with Al Faraj et al which showed similar results of increased prevalence of GPA as compared to MPA, and increased prevalence of C-ANCA positivity than P-ANCA in their patient population from Saudi Arabia<sup>13</sup>. They, however, concluded an increased male to female ratio of 1.61:1, in addition, mean age of onset in their study was 60 years while this study population had comparatively earlier age of onset around 43.6 years, and also showed a female predominance of 1.5:1 female to male ratio. Rest of the clinical and laboratory features of our study are comparable.

Pamuk *et al* previously has concluded similar results of increased prevalence of GPA and C-ANCA positive vasculitis in their retrospective analysis conducted at Turkey<sup>14</sup>. However, their results also showed male predominance with a male to female ratio of 1.38:1, and peak age of onset around 50 years as compared to 40 years in this study, in addition, their data showed C-ANCA positivity of 96% in GPA, as compared to 68.8% in our study.

Fujimoto *et al* in their prospective analysis of AAV epidemiology pointed out the increased prevalence of GPA than MPA in the UK<sup>15</sup>. Our study shows favorable results to these findings. The reasons for geographical variation are still unclear and the proposed mechanisms include latitude and altitude differences; genetic variation; vitamin D deficiency etc<sup>16</sup>.

In one study by Seck *et al*, C-ANCA positive granulomatosis with polyangiitis was present in 92% of their patients however only 4% of patients

had P-ANCA positive granulomatosis with polyangiitis. This is similar to the results in this study where we also found the GPA patients were predominantly C-ANCA positive while we also had a single patient of P-ANCA positive GPA. Also similar to our study all patients with microscopic polyangiitis were only P-ANCA positive. These findings support the pattern of immunological laboratory findings found in our study as mentioned in results<sup>17</sup>.

In another study conducted in children, GPA was found to be 42.4% and MPA was 57.6% while no patient of EGPA was identified. In an adult population like in our study, GPA was found to be the predominant type of ANCA associated vasculitis as compared to MPA (80% vs 20%) however, no case of EGPA was found similar to children population. In our study, the adult population also showed a female predominance (60%)<sup>18</sup>.

Our findings should be reviewed in the light of limitations like Small sample size, the inclusion of patients only from rheumatology clinic, lack of long-term follow-up may be a factor for some of the altered clinical manifestations as vasculitis tends to present different systemic manifestations throughout the course. This study did not have any patient of EGPA likely causes besides its low prevalence can be predominant self and/or physician referral to pulmonologist instead of the rheumatologist.

### ACKNOWLEDGMENT

Special thanks to my colleagues, Miss Afshan Khanam and Ahsan Khan.

### CONCLUSION

GPA is the more prevalent form of AAV in our population. AAV clinically manifests as respiratory, ENT, ocular and neurological manifestation, confined to GPA, and GIT manifestation confined to MPA, and renal involvement in both. Among GPA, C-ANCA negative GPA is more likely associated with renal involvement.

### CONFLICT OF INTEREST

This study has no conflict of interest to be declared by any author.

### REFERENCES

1. Yates M, Watts R. ANCA-associated vasculitis. *Clin Med* 2017; 17(1): 60-64.
2. Jennette J, Falk R, Bacon P, Basu N, Cid M, Ferrario F, et al. Revised international chapel hill consensus conference nomenclature of vasculitides. *Arthritis Rheumat* 2012; 65(1): 1-11.
3. Hilhorst M, van Paassen P, Tervaert J. Proteinase 3-ANCA vasculitis versus myeloperoxidase-ANCA vasculitis. *J Am Soc Nephrol* 2015; 26(10): 2314-27.
4. Grygiel-Górniak B, Limphaibool N, Perkowska K, Puszczewicz M. Clinical manifestations of granulomatosis with polyangiitis: key considerations and major features. *Postgrad Med* 2018; 130(7): 581-96.
5. Rajagopala S, Sagar BK, Thabab MM, Srinivas BH, Venkateswaran R, Parameswaran S. Pulmonary-renal syndromes: experience from an Indian intensive care unit. *Indian J Crit Care Med* 2015; 19(6): 316.
6. Stone J, Imboden J, Hellmann D. *Current diagnosis & treatment in rheumatology*. 3rd ed. New York: McGraw Hill; 2013; 264-84.
7. Smith M. Pathology of antineutrophil cytoplasmic antibody-associated pulmonary and renal disease. *Arch Pathol Lab Med* 2017; 141(2): 223-31.
8. Puéchal X. Antineutrophil cytoplasmic antibody-associated vasculitides. *Joint Bone Spine* 2007; 74(5): 427-35.
9. Al Arfaj A, Khalil N. ANCA associated vasculitis in patients from Saudi Arabia. *Pak J Med Sci* 2018; 34(1): 88.
10. Salmela A, Törnroth T, Poussa T, Ekstrand A. Prognostic factors for survival and relapse in ANCA-associated vasculitis with renal involvement: A clinical long-term follow-up study. *Int J Nephrol* 2018; 2018: 6369814.
11. Yates M, Watts R, Bajema I, Cid M, Crestani B, Hauser T, et al. EULAR/ERA-EDTA recommendations for the management of ANCA-associated vasculitis. 2019.
12. Holle JU, Gross WL. Treatment of ANCA-associated vasculitides (AAV). *Autoimmun Rev* 2013; 12(4): 483-86.
13. Al Arfaj AS, Khalil N. ANCA associated vasculitis in patients from Saudi Arabia. *Pak J Med Sci* 2018; 34(1): 88-93.
14. Pamuk ÖN, Dönmez S, Calayır GB, Pamuk GE. The epidemiology of antineutrophil cytoplasmic antibody-associated vasculitis in northwestern Turkey. *Clin Rheumatol* 2016; 35(8): 2063-71.
15. Fujimoto S, Watts RA, Kobayashi S, Suzuki K, Jayne DR, Scott DG, et al. Comparison of the epidemiology of anti-neutrophil cytoplasmic antibody-associated vasculitis between Japan and the U.K. *Rheumatology (Oxford)* 2011; 50(10): 1916-20.
16. Ramagopalan SV, Heger A, Berlanga AJ, Mageri NJ, Lincoln MR, Burrell A, et al. A ChIP-seq defined genome-wide map of vitamin D receptor binding: associations with disease and evolution. *Genome Res* 2010; 20(10): 1352-60.
17. Seck SM, Dussol B, Brunet P, Burtey S. Clinical features and outcomes of ANCA-associated renal vasculitis. *Saudi J Kidney Dis Transpl* 2012; 23(2): 301-05.
18. Sacri A, Chamberaud T, Ranchin B, Florquin B, See H, Decramer S, et al. Clinical characteristics and outcomes of childhood-onset ANCA-associated vasculitis: a French nationwide study. *Nephrol Dial Transplant* 2015; 30 (Suppl-1): 104-12.