

## DIAGNOSTIC ACCURACY OF CONTRAST ENHANCED COMPUTED TOMOGRAPHY IN DIAGNOSING RENAL CELL CARCINOMA, TAKING HISTOPATHOLOGY AS GOLD STANDARD

Ayesha Munir, Shahla Zameer, Umairah Kalim\*

Pakistan Institute of Medical Sciences Islamabad Pakistan, \*Islamabad Diagnostic Centre Islamabad Pakistan

### ABSTRACT

**Objective:** To determine the diagnostic accuracy of contrast enhanced computed tomography (CECT) scan in detecting renal cell carcinoma taking histopathology as gold standard.

**Study Design:** Validity Study.

**Place and Duration of Study:** Study was conducted in Department of Radiology, Pakistan Institute of Medical Sciences, and Islamabad, from Aug 2017 to Mar 2018.

**Material and Methods:** The study was done on 60 patients with renal masses on ultrasonography. Pregnant females and patients not willing for surgery were excluded. All the subjects underwent pre-contrast and contrast-enhanced CT scanning of the abdomen using a multi-sectional spiral CT device. All CT scan findings were interpreted by one consultant radiologist for presence or absence of renal cell carcinoma. CT scan findings were correlated with histopathological findings. Data was analyzed with SPSS v 20.

**Results:** Mean age at the time of presentation was  $56.79 \pm 9.25$  years. Out of these 60 patients, 41 (68.33%) were males and 19 (31.67%) were females with male to female ratio of 2.2:1. In CT scan positive patients, 34 were true positive and 2 were false positive. Among CT scan negative patients, 4 were false negative (FN) where as 20 were true negative (TN) ( $p=0.0001$ ). Overall sensitivity, specificity, positive predictive value (PPV), negative predictive value (NPV) and diagnostic accuracy of contrast enhanced computed tomography (CT) in detecting renal cell carcinoma patients was 89.47%, 90.91%, 94.44%, 83.33% and 90.0% respectively.

**Conclusion:** This study concluded that CECT scan is a highly sensitive and accurate non-invasive modality for detecting renal cell carcinoma.

**Keywords:** Computed tomography, Renal cell carcinoma, Sensitivity.

---

This is an Open Access article distributed under the terms of the Creative Commons Attribution License (<http://creativecommons.org/licenses/by/4.0>), which permits unrestricted use, distribution, and reproduction in any medium, provided the original work is properly cited.

---

### INTRODUCTION

Renal cell carcinoma (RCC) is the commonest primary renal malignant tumour in adults and accounts for approximately 85-90% of renal malignancy<sup>1</sup>. Most of the patients with renal cell carcinoma presented with various symptoms. Majority of patients are asymptomatic until the tumour is advanced. It was seen that about 25% patients presented with either distant metastasis or locally advanced disease. Some asymptomatic patients with locally advanced tumour are incidentally diagnosed on radiological imaging which is done for other indications<sup>2</sup>. RCCs can enlarge locally, invade surrounding fascia and adjacent organs, and/or metastasize. The most

common sites of metastases are the regional lymphatics, lungs, bone, liver, brain, the ipsilateral adrenal gland, and the contralateral kidney<sup>3,4</sup>.

The challenges of renal tumor imaging include not only reliable differentiation between benign and malignant lesions but also accurate staging to ensure optimal treatment planning<sup>5</sup>. Ultrasonography, computed tomography (CT) scanning and magnetic resonance imaging (MRI) are the prime imaging modalities of the kidneys<sup>6</sup>. Ultrasonography has been used primarily for characterizing the cystic versus solid nature of renal masses but this modality has a low sensitivity and specificity with significant limitations in characterizing and staging the malignancy<sup>2</sup>. Multi-detector CT scan and MRI are the modalities used more reliably in the diagnosis, staging and surveillance of renal cancers with com-

---

**Correspondence:** Dr Ayesha Munir, Pakistan Institute of Medical Sciences Islamabad Pakistan (Email: [ayesha.mnr78@gmail.com](mailto:ayesha.mnr78@gmail.com))

Received: 18 Jun 2018; revised received: 15 Jul 2018; accepted: 15 Aug 2018

parable diagnostic accuracy<sup>7</sup>. Contrast-enhanced computed tomography (CECT) scanning is used in staging the renal cell carcinoma and also has the advantage of characterizing the cystic and solid nature of the mass as well as the extent of the tumour<sup>8</sup>.

Early diagnosis of renal cell carcinoma is important because it aids selection of appropriate therapy of this severe condition and improves clinical outcome, symptom management and

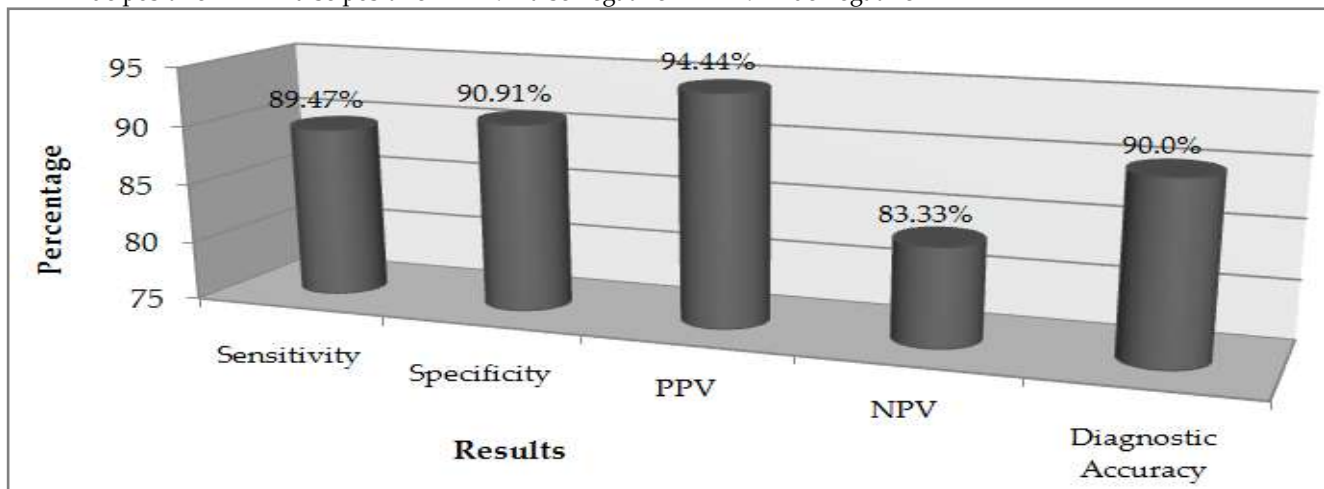
Radiology, Pakistan Institute of Medical Sciences, and Islamabad on 60 patients with solid renal mass on ultrasonography. These patients then underwent computed tomography examination. Pregnant females and patients not willing for surgery were excluded from the study. Sample size was calculated by using WHO calculator by taking 95% confidence level and precision of 0.05. Consecutive sampling technique was used.

After taking informed consent and relevant

**Table: Findings of CT scan and Histopathology.**

	RCC on Histopathology (Yes)	RCC on Histopathology (No)	Total
RCC on CT scan (Yes)	34 (TP)*	02 (FP)**	36
RCC on CT scan (No)	04 (FN)**	20 (TN)****	24
Total	38	22	

\*-TP=True positive \*\*-FP=False positive \*\*\*-FN=False negative \*\*\*\*-TN=True negative



**Figure-1: Diagnostic accuracy of contrast enhanced computed tomography (CT) in detecting renal cell carcinoma.**

prognosis. Thus, we have conducted this study to determine the diagnostic accuracy of contrast enhanced computed tomography in diagnosing renal cell carcinoma, taking histopathology as gold standard. The results of current study will help in providing patients with an imaging modality for pre-operative assessment of renal cell carcinoma and thus to take proper management plan in order to reduce the morbidity and mortality of these patients.

**MATERIAL AND METHODS**

This validity study was conducted from August 2017 to March 2018 in Department of

history, all the subjects underwent pre-contrast and contrast-enhanced abdominal CT scan using a multi-slice spiral CT device. All CT scan findings were interpreted by the same consultant radiologist for presence or absence of renal cell carcinoma. All patients were then operated in the concerning surgical ward and specimen was sent for histopathology in the institutional laboratory where histopathology report was interpreted by consultant pathologist (with at least 5 years of post-fellowship experience). CT scan findings were correlated with histopathology findings. Data was analyzed by SPSS v 23.0. Quantitative

variables were presented as mean and standard deviation. Qualitative variables were presented in the form of frequency and percentage. A 2×2 contingency table was used to calculate sensitivity, specificity, PPV, NPV and diagnostic accuracy of contrast enhanced computed tomography in renal cell carcinoma.

## RESULTS

Mean age at the time of presentation was  $56.79 \pm 9.25$  years. Out of these 60 patients, 41 (68.33%) were males and 19 (31.67%) were females with ratio of 2.2:1. CT scan supported the diagnosis of renal cell carcinoma in 36 (60.0%) patients and no renal cell carcinoma in 24 (40.0%) patients. Histopathology findings confirmed

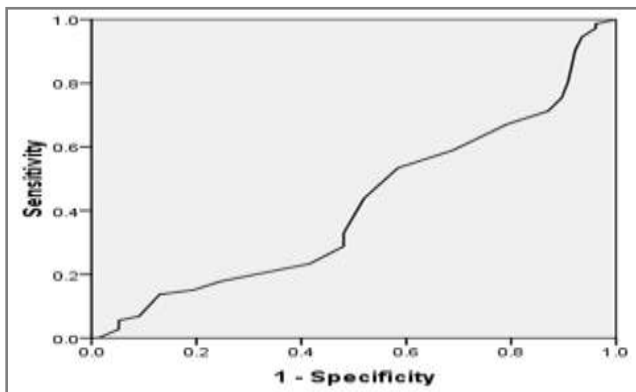


Figure-2: ROC Curve.

renal cell carcinoma in 38 (63.33%) patients and no renal cell carcinoma in 22 (36.67%) patients. In CT scan positive patients, 34 (true positive) had renal cell carcinoma and 2 (false positive) had no renal cell carcinoma on Histopathology. Among 24, CT scan negative patients, 4 (false negative) had renal cell carcinoma on histopathology whereas 20 (true negative) had no renal cell carcinoma on histopathology as shown in table.

Overall sensitivity, specificity, positive predictive value (PPV), negative predictive value (NPV) and diagnostic accuracy of contrast enhanced computed tomography (CECT) in detecting renal cell carcinoma patients was 89.47%, 90.91%, 94.44%, 83.33% and 90.0% respectively shown in fig-1. ROC curve was shown in fig-2.

## DISCUSSION

The advancement of CT technology and introduction of triphasic protocols provide extra accuracy of RCC staging. Early detection of RCC helps in improving prognosis<sup>9</sup> therefore we conducted the study to determine the diagnostic accuracy of contrast enhanced CT scan in detecting renal cell carcinoma patients taking histopathology as gold standard.

Nazim *et al*<sup>10</sup> in his retrospective study assessed 98 patients presenting with renal cell carcinoma. The author preoperatively assessed renal tumor staging using multidetector computer tomography (MDCT) and found specificity of computed tomography for capsular invasion as 85.0%, nodal disease as 82.0% and adrenal involvement as 98.0% respectively.

In one study conducted in Turkey, 51 of 57 tumors were staged correctly while 5 were overstaged and 1 was understaged by MDCT. The author has shown the overall diagnostic accuracy of 89.0%<sup>11</sup>. Catalano *et al* reported sensitivity, specificity, PPV, NPV and diagnostic accuracy of contrast enhanced computed tomography (CT) in detecting perinephric fat infiltration renal cell carcinoma patients was 96.0%, 93.0%, 100.0%, 93.0% and 95.0% respectively<sup>12</sup>.

Liu *et al*<sup>13</sup> in his study has found the sensitivity and specificity of CT in detecting perinephric fat invasion as 32.26% and 85.87%, in detecting tumor thrombosis as 84% and 100%, in detecting adrenal gland invasion as 60% and 95.79%, in detecting lymph node involvement as 50% and 96.36%, in detecting distant metastasis as 100% and 99.67%, respectively. The author has shown that the 237 out of 314 were diagnosed correctly by computed tomography with diagnostic accuracy of 75.48%.

In a study done in India by Anghong *et al*<sup>14</sup> reported 8 of 28 patients with perinephric involvement in comparison with operative findings and histological findings. All 8 patients also had capsular involvement. The author found the sensitivity of 75% and specificity of 70% of computed tomography (CT) in detecting perinephric fat

infiltration in renal cell carcinoma patients. Sheth *et al*<sup>15</sup> and Hallscheidt *et al*<sup>16</sup> suggested that staging of the renal tumor remains a difficult task with computed tomography and reduced diagnostic accuracy of 64.0% in staging renal cell carcinoma.

In our study, sensitivity, specificity, PPV, NPV and diagnostic accuracy of CECT in detecting RCC patients was 89.47%, 90.91%, 94.44%, 83.33% and 90.0% respectively. Our results were in agreement with studies conducted in other parts of world. Kim *et al* found diagnostic accuracy of CT to be 79.7% in diagnosing RCC<sup>17,18</sup>.

## CONCLUSION

This study concluded that CECT scan is a highly sensitive and accurate non-invasive modality for detecting renal cell carcinoma.

## CONFLICT OF INTEREST

This study has no conflict of interest to be declared by any author.

## REFERENCES

- Jemal A, Siegel R, Xu J, Ward E. Cancer statistics, 2015. *CA Cancer J Clin* 2015; 33: 331-53.
- King SC, Pollack LA, Li J, King JB, Master VA. Continued increase in incidence of renal cell carcinoma, especially in young patients and high grade disease: United States 2001 to 2010. *J Urol* 2014; 191: 1665-70.
- Laguna MP, Algaba F, Cadeddu J, Clayman R, Gill I, Gueglio G, et al. Clinical research office of the endourological society renal mass study: Current patterns of presentation and treatment of renal masses: A clinical research office of the endourological society prospective study. *J Endourol* 2014; 28: 861-70.
- Brufau BP, Cerqueda CS, Villalba LB, Izquierdo RS, Molina CN. Metastatic renal cell carcinoma: radiologic findings and assessment of response to targeted antiangiogenic therapy by using multidetector CT. *Radiographics* 2013; 33(6): 1691-1716.
- Nakashima K, Kitagawa Y, Izumi K, Mizokami A, Gabata T, Namiki M. Diagnostic accuracy of pre-operative imaging findings in presumed clinical T1a renal cell carcinomas. *Oncology Letters* 2016; 11(5): 3189-193.
- Sankineni S, Brown A, Cieciera M, Choyke PL, Turkbey B. Imaging of renal cell carcinoma. *Urol Oncol* 2016; 34(3): 147-55.
- El-Hefnawy AS, Mosbah A, El-Diasty T, Hassan M, Shaaban AA. Accuracy of multi-detector computed tomography (MDCT) in staging of renal cell carcinoma (RCC): Analysis of risk factors for mis-staging and its impact on surgical intervention. *World J Urol* 2013; 31(4): 887-91.
- Ganeshan D, Morani A, Ladha H, Bathala T, Kang H. Staging, surveillance, and evaluation of response to therapy in renal cell carcinoma: Role of MDCT. *Abdom Imaging* 2014; 39: 66-85.
- Lane BR. Prognostic factors for localized renal cell carcinoma. *Renal Cell Carcinoma* 2013; 83-102.
- Nazim SM, Ather MH, Hafeez K, Salam B. Accuracy of multidetector CT scans in staging of renal carcinoma. *Int J Surg* 2011; 9(1): 86-90.
- Türkvatan A, Akdur PO, Altinel M, Olçer T, Turhan N, Cumhuri T, et al. Preoperative staging of renal cell carcinoma with multidetector CT. *Diagn Interv Radiol* 2009; 15(1): 22-30.
- Catalano C, Fraioli F, Laghi A. High resolution multidetector CT in the preoperative evaluation of patients with renal cell carcinoma. *AJR Am J Roentgenol* 2003; 180: 1271-77.
- Liu Y, Song T, Huang Z, Zhang S, Li Y. The accuracy of multi-detector Computed Tomography for preoperative staging of renal cell carcinoma. *Int Braz J Urol* 2012; 38 (5): 1590.
- Angthong W, Muangsombon S, Parichatikanond P, Cheun-suchon B, Na Songkhla N, Muangsombon K. Accuracy of Multi-Detector CT Scan in Pre-operative staging of renal cell carcinoma: Comparison of radiological and histopathological findings. *Siraj Med J* 2010; 62(1): 18-22.
- Sheth S, Scatarige JC, Horton KM, Corl FM, Fishman EK. Current concepts in the diagnosis and management of renal cell carcinoma: Role of multidetector CT and three-dimensional CT. *Radio Graphics* 2001; 1(suppl): 237S-254S.
- Hallscheidt P, Wagener N, Gholipour F. Multislice computed tomography in planning nephron-sparing surgery in a prospective study with 76 patients: comparison of radiological and histopathological findings in the infiltration of renal structures. *J Comput Assist Tomogr* 2006; 30: 869-74.
- Kim JH, Sun HY, Hwang J, Hong SS. Diagnostic accuracy of contrast-enhanced computed tomography and contrast enhanced magnetic resonance imaging of small renal masses in real practice: Sensitivity and specificity according to subjective radiologic interpretation. *World J Surg Oncol* 2016; 14: 260.
- Xu L, Rong Y, Wang W. Percutaneous radiofrequency ablation with contrast-enhanced ultrasonography for solitary and sporadic renal cell carcinoma in patients with autosomal dominant polycystic kidney disease. *World J Surg Oncol*. 2016;14:193 .