

## RIGHT SUBCLAVIAN ARTERY ANEURYSM WITH COARCTATION OF AORTA PRESENTING WITH HORNER'S SYNDROME IN AN ADULT

Muhammad Waseem, Hafsa Inam, Javeria Kamran, Rehana Javaid

Armed Forces Institute of Cardiology/ National Institute of Heart Diseases (AFIC/NIHD)/ National University of Medical Sciences (NUMS) Rawalpindi Pakistan

### ABSTRACT

Coarctation of aorta is congenital narrowing of the upper descending aorta adjacent to the site of attachment of the ductus arteriosus. The combination of subclavian artery (SCA) aneurysm with coarctation of the aorta is a rare condition. This causes hypertension in arms, while the blood pressure in legs is lower. We report a case of 42 years old male with coarctation of the aorta and right subclavian artery aneurysm who presented with Horner's syndrome due to pressure effects of right subclavian aneurysm.

This is an Open Access article distributed under the terms of the Creative Commons Attribution License (<http://creativecommons.org/licenses/by/4.0/>), which permits unrestricted use, distribution, and reproduction in any medium, provided the original work is properly cited.

### INTRODUCTION

As the aorta proximal to coarctation is anomalous, including its main branches, aneurysm formation can occur in both subclavic arteries due to prolonged hypertension<sup>1</sup> Aorta coarctation is a narrowing of the aorta, which most often occurs just beyond the left subclavian artery<sup>2</sup>. When diagnosed, the coarctation segment and aneurysm can be surgically treated because of the risk of ischemic complications secondary to thromboembolic phenomena caused by aneurysm leading to embolization in the upper extremity and vertebral vessels<sup>3</sup>.

### CASE REPORT

A 42 years old male patient who had type II diabetes mellitus, hypertension and right sided Horner's syndrome with absent femoral pulses presented to us for evaluation. On chest x-ray a mediastinal shadow was visible on the right side of the cardiac shadow. CT angiography of the chest showed coarctation of aorta at the level of ductus arteriosus with 6 x 6 cm aneurysm of second part of the right subclavian artery. His coronary angiography was unremarkable and aorto gram showed no communication across the coarctation segment.

He underwent patch-plasty with a Dacron patch for coarctation through posterolateral left

thoracotomy in 4<sup>th</sup> intercostal space in first stage. Three weeks later, in second stage, through a

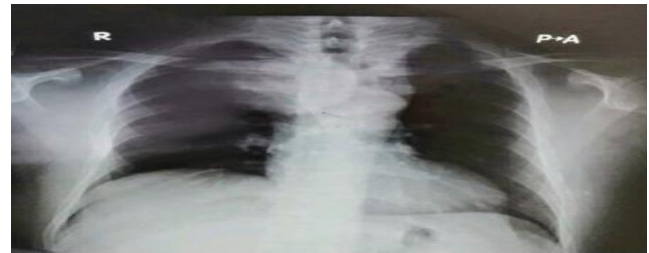

Figure-1(a): A mediastinal shadow was visible on the right side in chest x-ray.

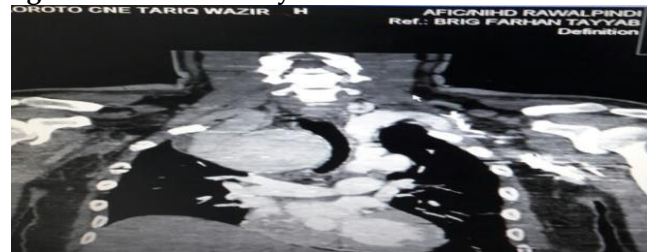


Figure-1(b): Coarctation of aorta at the level of ductus arteriosus.

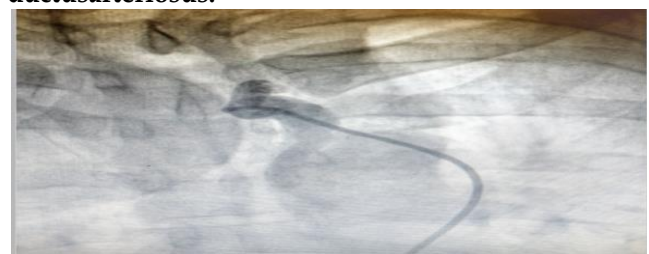

Figure-1(c): The aneurysm was replaced with a 6 mm Teflon graft.

trap door incision right subclavian artery was exposed. With proximal and distal control the aneurysm was opened and the ostium of ver-

Correspondence: Dr Muhammad Wasim, Dept of Cardiac Surgery, Armed Forces Institute of Cardiology, Rawalpindi Pakistan  
Email: [mwaseemmd@gmail.com](mailto:mwaseemmd@gmail.com)

tebral artery was stitched from within with a 2/0 silk suture. The aneurysm was replaced with a 6 mm Teflon graft.

## DISCUSSION

Aortic coarctation is a congenital heart disease that occurs in about 7% of patients. It is associated with various abnormalities that affect the proximal and distal aorta adjacent to the coarctation; the ascending and transverse aorta; the radial, brachial, and carotid arteries; and the retinal vascular bed<sup>3-4</sup>. These anomalies may include collateral arteries, vascular rings, aortic bicuspid valve, dissecting aneurysms, cerebral aneurysms and decreasing to the left interpa-pillary ventricular distance<sup>5</sup>.

It has only been shown in recent years that the wall of the proximal aorta to coarctation is abnormal and that the abnormalities extend to all the major arteries supplied by the proximal aorta to the coarctation. Because of the shear effects of hypertension, aneurysm can form in left or right subclavian arteries<sup>6</sup>. SCA Aneurysms are rare<sup>7</sup>, And only 1 percent of all peripheral arteries are subclavian and innominate<sup>8</sup>. Various studies reported that only 2 out of 1488 cases of atherosclerotic aneurysm had SCAA, with an incidence of about 0.13%. The largest aneurysm thus far reported measured 12 cm<sup>9</sup>. A literature review conducted by Hobson *et al* identified 195 cases of aneurysms in this topography, accounting for 1% of all peripheral aneurysms, 88% of

which were in the subclavian artery. Coarctation of aorta in adults can be treated with stenting and subclavian aneurysm can be excluded with covered stents endo-luminally. Surgical correction of aortic coarctation and resection and replacement of subclavian aneurysm can be exercised easily<sup>10</sup>.

## CONFLICT OF INTEREST

This study has no conflict of interest to declare by any author.

## REFERENCES

1. Cardoso G, Abecasis M, Anjos R, Marques M, Koukoulis G, Aguiar C, Neves JP Aortic coarctation repair in the adult. *J Card Surg* 2014; 29: 512-18.
2. Hoffman JI. The challenge in diagnosing coarctation of the aorta. *Cardiovasc J Afr* 2018; 29(4): 252-55.
3. Mengal MN, Ashraf T, Badini AM. Successful Percutaneous Intervention for Subclavian Arterial Aneurysm. *Vascular Disease Management* 2016; 13(12): E275-E280.
4. Liu X, Li Z, He Y. Right Subclavian Artery Aneurysm A Rare Complication of Coarctation of the Aorta. *Tex Heart Inst J* 2012; 39(2): 290-91.
5. Perloff JK. The variant associations of aortic isthmus coarctation. *Am J Cardiol* 2010; 106(7): 1038-41
6. Malik MK, Kraev AI, Hsu EK, Clement MHC, Landis GS. Spontaneous axillary artery aneurysm: a case report and review of the literature. *J Vascular* 2012; 20 (1): 46-48.
7. Delton L, Farquharson BA. Right Subclavian Artery Aneurysm: A First for the Bahamas. *J Vascular Disease Management* 2011; 8(8): 138-40.
8. Singh Y, Verma H, Tripathi R. Giant subclavian artery aneurysm: Case report and review of literature. *Indian J Vasc Endovasc Surg* 2017; 4(2): 73-75.
9. Lam AKK, Abayasekara K, Management of Subclavian Aneurysms. *J Clin Stud Med* 2015, 2: 026
10. Ongun N, Tumkaya F, Ongun ED, Ozcan V. A Rare Cause of Horner Syndrome: ArteriaLusoria, *J Neurol Neurophysiol* 2017; 8: 5.