

CLINICAL MANIFESTATIONS OF RIGHT VENTRICULAR INFARCT IN PATIENTS OF INFERIOR WALL MYOCARDIAL INFARCTION

Syed Ihtisham Ul Haque, Sarfraz Ali Zahid*, Farhan Tuyyab*, Tahir Mukhtar Sayed, Ijaz Ahmed**, Amina Tahir, Rehana Khadim*

Pak Emirates Military Hospital/National University of Medical Sciences (NUMS) Rawalpindi Pakistan, *Armed Forces Institute of Cardiology (AFIC)/National Institute of Heart Diseases (NIHD)/National University of Medical Sciences (NUMS) Rawalpindi Pakistan, **Scouts Hospital SWS, Wana Pakistan

ABSTRACT

Objective: To determine the clinical manifestations of right ventricular infarct in patients of inferior wall myocardial infarction.

Study Design: Descriptive cross-sectional study.

Place and Duration of Study: The study was conducted at AFIC & NIHD Rawalpindi, from Jul 2017 to Jun 2018.

Material and Methods: Patients with inferior wall myocardial infarction were enrolled. Data regarding age, gender, clinical presentation especially typical chest pain, decreased level of consciousness, hypotension, raised jugular venous pressure and changes in standard 12 lead ECG along with right sided leads were noted. Patients with previous history of any myocardial infarction, chronic kidney disease and chronic liver disease or hypotension were excluded from the study and patients with electrolyte imbalances were also excluded from the study. Data was entered and analysed using SPSS-21.

Results: A total of 264 patients of inferior wall MI were enrolled out of whom 82 (31%) had inferior wall MI with RV infarction and 182 (69%) had inferior wall MI without RV infarction. The mean age of the patients was 56.95 ± 8.9 years. In patients of inferior wall myocardial infarction with right ventricular involvement, chest pain, hypotension, raised JVP and decreased level of consciousness was seen in 79 (96.3%), 51 (62.1%), 18 (21.9%), 16 (19.5%) respectively while in patients with no right ventricular involvement chest pain, hypotension, raised JVP and decreased level of consciousness was seen in 179 (98.3%), 2 (1%), 7 (3.84%), 3 (1.64%) respectively.

Conclusion: The results showed that chest pain, decreased level of consciousness, hypotension, raised JVP were more frequent in inferior MI with RV involvement patients as compared to inferior MI without RV involvement.

Keywords: Clinical manifestations, RV infarction, Inferior wall MI.

This is an Open Access article distributed under the terms of the Creative Commons Attribution License (<http://creativecommons.org/licenses/by/4.0>), which permits unrestricted use, distribution, and reproduction in any medium, provided the original work is properly cited.

INTRODUCTION

Inferior wall myocardial infarction accounts for 40% of all myocardial infarctions globally. Generally the mortality rates associated with inferior wall myocardial infarction are <10%¹. Acute myocardial infarction causes a lot of complications including heart failure, cardiogenic shock, acute mitral valve prolapse and stroke². Patients who have right ventricular involvement with inferior wall myocardial infarction are at greater risk of mortality and morbidity associated with inferior wall myocardial infarction. Moreover the risk of developing different arrhythmias in inferior wall myocardial infarction with RV

infarction is also high^{3,4}. Chest pain remains the most frequent presenting complaint in inferior wall myocardial infarction as of all MIs and better hospital care can decrease the associated mortality⁵. In around 80% of patients, the right coronary artery through the posterior descending artery (PDA) supplies the inferior wall of the heart. In the remaining, the PDA is a branch of the circumflex artery⁶.

Characteristically in RVMI, the ST elevation in lead III is greater than in lead II, and the ST elevation in lead aVF is greater than the ST segment depression in lead V2^{7,8}. ST elevation >1mm in V4R is taken as diagnostic of right ventricular myocardial infarction⁹. Poor contractility of RV results in septal push to left ventricle that further impairs ventricular filling.

Correspondence: Dr Syed Ihtisham Ul Haque, Dept of Internal Medicine, PEMH Rawalpindi Pakistan
Email: syedihhtishamulhaq@gmail.com

Once right ventricular myocardial infarction is confirmed diuretics and beta blockers must be avoided as they can further cause decrease in BP that can be catastrophic³.

Delay in management of inferior wall myocardial infarction especially those with right ventricular infarct was associated with more atrio ventricular blocks¹⁰. Percutaneous coronary angioplasty remains the most successful treatment option for inferior wall ST elevation myocardial infarction¹¹.

Right ventricular (RV) infarction complicates 30% to 50% of cases of inferior wall MI⁸. Patients with RV infarction have higher incidence of cardiogenic shock, complete heart block, RV free wall rupture, cardiac tamponade, pulmonary embolism, and atrial fibrillation, resulting in poor clinical outcomes in patients with Inferior wall MI^{9,10}. Further, there are limited data and studies on Inferior wall MI in our population. Thus, the primary aim of the present study was to evaluate complications, subsequent morbidity and mortality, and effect of thrombolytic therapy in patients with inferior wall MI.

MATERIAL AND METHODS

The study was conducted at Armed Forces Institute of Cardiology and National Institute of Heart Diseases, Rawalpindi. A total of 264 patients with inferior wall myocardial infarction were enrolled (164 male and 100 female patients) out of which 82 (31.0%) had right ventricular infarct; of which 56 (21.2%) were males and 26 (9.8%) were female patients. Data regarding age, gender, clinical presentation specially typical chest pain, decreased level of consciousness, hypotension, raised jugular venous pressure and changes in standard 12 lead ECG along with right sided leads were noted. Patients with previous history of any myocardial infarction, chronic kidney disease and chronic liver disease or hypotension were excluded from the study. Typical chest pain was defined as central aching chest pain associated with sweating, vomiting, radiation to left arm or jaw for more than 30 mins, decreased consciousness was defined as

Glasgow Coma Scale of <10/15, patients with a blood pressure of <90/60 mm Hg or Mean Arterial Pressure of <65mmHg with non-invasive standard sphygmomanometer were taken as hypotensive. Raised jugular venous pressure (JVP) was taken as pressures >4cm of water from sternal angle. RV infarct was confirmed by presence of ST segment elevation of >1mm in right sided leads or echocardiographic evidence of right ventricular infarct. Diagnostic criteria for inferior myocardial infarction was typical chest pain, ST segment elevation over than 1mm on two or more than two contiguous leads II, III and aVF, and serially raised Troponin I levels. Renal function tests, liver function tests and electrolyte levels were done. Patients with a previous history of MI or its sequel, Chronic liver disease, chronic kidney disease (eGFR < 60 ml/min/1.73m²) and patients with electrolyte imbalances were excluded from the study. Data was entered and analysed using SPSS 21.0.

RESULTS

A total of 264 patients of inferior wall myocardial infarction were enrolled for the study. There were 164 (62.1%) male patients and

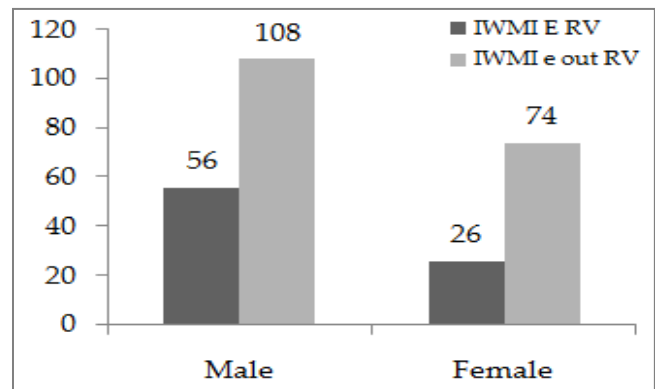


Figure-1: Frequency of right ventricular Infarct in Inferior Wall Myocardial Infarction (Gender Wise).

100 (37.8%) female patients. Mean age of patients was 56.95 ± 8.9 , 82 years. 82 (31.0%) patients had RV infarct along with inferior wall myocardial infarction; out of which 56 (21.2%) were males and 26 (9.8%) were female patients. While 182 (68.9%) had inferior wall myocardial infarction with no RV infarction, out of which 108 (40.9%)

were males and 74 (28.0%) were females (fig-1). Chest pain, hypotension, raised jugular venous pressure (JVP) and decreased level of consciousness was seen in 79 (96.3%), 51 (62.1%), 18 (21.9%), 16 (19.5%) in patients of IWMI with RV involvement and in 179 (98.3%), 2 (1%), 7 (3.84%), 3 (1.64%) in patients with no RV involvement respectively (fig-2).

DISCUSSION

This study mainly focused on complications associated with IWMI leading to poor clinical outcomes and worsened prognosis in our study population. In our study we found that the frequency of loss of consciousness, hypotension

myocardial infarction^{13,14}. AV blocks associated with inferior MI causes a lot of increase in the mortality¹⁵. In conclusion chest pain along with loss of consciousness, hypotension and raised JVP are clinically significant markers of RV infarct. Acute RV infarct has almost an equal mortality as compared to LV shock but the management is different as diuretics decrease preload that worsens right heart failure³. Thus early identification of RV infarct especially the RV leads can help in immediate management steps that can help reduce the increased mortality associated with RV infarct¹⁰. Pirzada emphasized the importance of right sided leads in the diagnosis of RV infarct in patients of inferior wall

	IWMI* with RV* Infarct N=82		IWMI without RV Infarct N=182		p-value
	Present	Absent	Present	Absent	
Chest Pain	79 (96.3%)	3	179 (98.3%)	3	0.3
Hypotension	51 (62.1%)	31	2 (1%)	180	<0.05
Raised JVP	18 (21.9%)	64	7 (3.84%)	175	<0.05
Decreased Level Of Consciousness	16 (19.5%)	66	3 (1.64%)	179	<0.05

Figure-2: IWMI-inferior wall myocardial infarction, RV= right ventricular.

and raised JVP was more common in those who had RV infarction along with IWMI as compared to those who no RV infarction along with IWMI while frequency of chest pain was more in patients with IWMI with no RV involvement.

Khosoosi Niaki compared the clinical manifestations of RV involvement in IWMI and found that the frequency of chest pain, loss of consciousness and hypotension was significantly higher in RV infarct group as compared to IWMI with no RV involvement¹². Our results were almost consistent with the findings of Khosoosi Niaki. In our study we found that symptoms of hypotension, decreased level of consciousness and raised JVP may serve as a clue to the diagnosis of RV infarct in patients of IWMI and therefore right sided chest leads should always be used in such patients presenting with 12 hours of their symptoms. Hemodynamic instability or ST-segment elevation of more than 1 mm in lead V1 raises the suspicion of right ventricular

myocardial infarction. The hypotension in RV infarct with IWMI is attributable to the large size of infarct and decreased contractility of right heart. Hypotension is the most important clinical indicator of RV infarct. Decreased level of consciousness was probably because of decreased perfusion of brain as a result of decreased blood pressures and decreased stroke volume. Raised JVP was attributable to increased pressures in right heart because of decreased contractility of right heart.

CONCLUSION

The results showed that chest pain, decreased level of consciousness, hypotension, raised JVP were more frequent in inferior MI with RV involvement patients as compared to inferior MI without RV involvement.

CONFLICT OF INTEREST

This study has no conflict of interest to be declared by any author.

REFERENCES

1. Warner MJ BS. Myocardial Infarction, Inferior. Treasure Island (FL): StatPearls Publishing 2018.
 2. Areeba Riaz MK, Sobia Mughal. Frequency of Complications of Anterior Wall Myocardial Infarction. *Pak Heart J* 2017; 50(3): 190-93.
 3. Malla RR. In hospital complications and mortality of patients of inferior wall myocardial infarction with right ventricular infarction. *JNMA J Nepal Med Assoc* 2007; 46(167): 99-102.
 4. Mehta SH. Impact of Right Ventricular Involvement on Mortality and Morbidity in Patients With Inferior Myocardial Infarction. *J Am Coll Cardiol* 2011; 37(1): 37-43.
 5. Senthil Kumar P NNT, Htoo Htoo Kyaw Soe. Clinical profile of acute inferior wall myocardial infarction in a semi urban population in India. *Int J Med Med Sci* 2013; 4(1): 17-21.
 6. Kakouros N1 CD. Right ventricular myocardial infarction: pathophysiology, diagnosis, and management. *Postgrad Med J* 2010; 86(1022): 19-28.
 7. Hamon M, Le Page O, Riddell JW, Hamon M. Prognostic impact of right ventricular involvement in patients with acute myocardial infarction. *Crit Care Med* 2008; 36(7): 2023-33.
 8. Nagarajan MV, Donald A. Underwood, MD. The clinical picture V1: The most important lead in inferior STEMI. *Cleveland Clinic J Medicine*. 2012; 79(10): 682-83.
 9. Somers MP, Bateman DC, Mattu A, Perron AD. Additional electrocardiographic leads in the ED chest pain patient: Right ventricular and posterior leads. *Am J Emerg Med* 2003; 21(7): 563-73.
 10. Pirzada AM, Mahmood K, Sagheer T, Mahar SA, Jafri MH. High degree Atrioventricular block in patients with acute inferior Myocardial Infarction with and without Right Ventricular involvement. *J Coll Physicians Surg Pak* 2009; 19(5): 269-74.
 11. Dubey GSK, Vinay V. Primary percutaneous coronary intervention for acute ST elevation myocardial infarction: Outcomes and determinants of outcomes: A tertiary care center study from North India. *Indian J Heart J* 2017; 69(3): 294-8.
 12. Niaki KM, Salehiomran M. Clinical manifestations of right ventricle involvement in inferior myocardial infarction. *Caspian J Intern Med* 2014; 5(1): 13-6.
 13. Morris F, ABC of clinical electrocardiography. ABC of clinical electrocardiography: Acute myocardial infarction-Part I. *BMJ* 2012; 324: 831.
 14. Te-Chuan Chou, Noble O. Fowler Marjorie Gabel Electrocardiographic and Hemodynamic Changes in experimental right ventricular infarction. *J Circulation* 2013; 67(6): 1258-67.
 15. Sclarovsky S, Hirshberg a advanced early and late atrioventricular block in acute inferior wall myocardial infarction. *Am Heart J* 2014; 108(1): 19-24.
-