

LEFT-SIDED ACUTE APPENDICITIS - A PITFALL IN THE EMERGENCY DEPARTMENT

Khalid Ibrahim Akhtar, Muhammad Adnan Akram

Combined Military Hospital Thal/National University of Medical Sciences (NUMS) Pakistan

ABSTRACT

Left-sided acute appendicitis is a diagnostic dilemma. Because the appendix is located in an abnormal position there are two different anatomic anomalies attributed to a left-sided appendix: situs inversus and malrotation of the midgut loop. In case of abnormal anatomical site of appendix as in situs inversus or gut malrotation, atypical presentation begins with epigastric pain radiating to left lower quadrant of abdomen along with tenderness confusing with diverticulitis. There has been an increasing use of imaging modalities, such as USG and CT, in the diagnosis of acute appendicitis. Diagnostic laparoscopy is the gold standard in cases with complicated differential diagnosis. Clinical assessment/judgment has no match in diagnosis and avoiding serious complications.

This is a case report of 25 years old young male who presented initially with pain epigastrium and vomiting with diagnosis of acute gastritis. Later on pain localized to lower abdomen more on left side than right lower side. It was initially treated conservatively, later on due to persistence of pain abdomen and increase in intensity clinical diagnosis of acute appendicitis was made and appendectomy was planned via traditional incision. Per-operatively, left-sided acutely inflamed appendix along with caecum and ascending colon were found in left lower abdomen, operation was completed via lower midline abdominal incision. The main aim was to stress on clinical assessment/judgment where highly sophisticated diagnostic facilities are not available.

Keywords: Clinical diagnosis, Laparoscopy, Left-sided acute appendicitis, Malrotation of Mid-Gut, Situs inversus.

This is an Open Access article distributed under the terms of the Creative Commons Attribution License (<http://creativecommons.org/licenses/by/4.0>), which permits unrestricted use, distribution, and reproduction in any medium, provided the original work is properly cited.

INTRODUCTION

Acute Appendicitis is the most common general surgical emergency. Diagnosis of appendicitis can be elusive, and a high index of suspicion is important especially when we are working in remote area where sophisticated diagnostic facilities such as ultrasonography/CT scan are not available. We present a case report on left sided- acute appendicitis (LSAA) in a young soldier. Aim was to give an overview of the literature on left-sided acute appendicitis (LSAA) associated with situs inversus totalis (SIT) and midgut malrotation (MM).

CASE REPORT

A 25 year old young soldier was referred to medical out-patient dept. with complaints of pain epigastrium and vomiting. There was no h/o constipation or burning micturition. He was

admitted in medical ward with provisional diagnosis of acute gastritis and patient was put on intravenous fluids, injectable 3rd generation cephalosporin (ceftriaxone) and intravenous infusion of omeprazole and no oral intake was permitted.

Blood complete picture revealed hemoglobin level 12.6 g/dl, total leucocyte count 11,500 /cmm. Serum amylase level was 64 I/L. Chest X-ray P-A view and X-ray plain abdomen (erect and supine) were unremarkable. Ultrasonography and CT scan were not available. Patient did not show any improvement in his symptoms during first day of admission and was referred to surgical out-patient dept. for surgical opinion where he was examined thoroughly and found to have mild tenderness more in left lower abdomen than right lower abdomen along with audible bowel sounds. Proctoscopy and digital rectal examination were unremarkable. Conservative treatment was continued. Next day patient complained of increase in intensity of pain, more in lower abdomen and tenderness on both sides

Correspondence: Dr Khalid Ibrahim Akhtar, Classified Surgical Specialist, CMH Thal Pakistan

Email: khalidibrahimsurg@hotmail.com.

Received: 23 Jan 2013; revised received: 24 Oct 2013; accepted: 20 Apr 2015

of lower abdomen and provisional diagnosis from acute gastritis to acute appendicitis was made and emergency appendectomy was planned.

Abdominal cavity was opened via right gridiron incision (fig-1a). Preoperatively, appendix, caecum and ascending colon were not found in right lower abdomen and small gut loops were found in right lower abdomen (fig-1c). Later on abdominal cavity was explored via lower midline vertical incision (fig-2a,b) and acutely inflamed markedly swollen pelvic appendix along with caecum, ascending colon were found in left lower abdomen (fig-2a,b). Liver and spleen were at their normal anatomical sites.

Appendectomy was done, the patient

downward out-pouching of the caecum and gradually rotates to a more postero-medial location as the gut rotates and the caecum becomes fixed in the right lower quadrant. At birth, the appendix is short and broad at its junction with the caecum, but differential growth of the caecum produces the typical tubular (appendix) structure at its posteromedial portion by the age of 2 years. During childhood, continued growth of caecum commonly rotates the appendix into a retrocaecal but intra-peritoneal position. In normal development, the midgut rotates in a 270° counter clockwise direction and the position of the appendix lies in the right lower quadrant of the abdomen. Primarily, there are two different anatomic anomalies attributed to a left-sided appendix: situs inversus and malrotation of the midgut

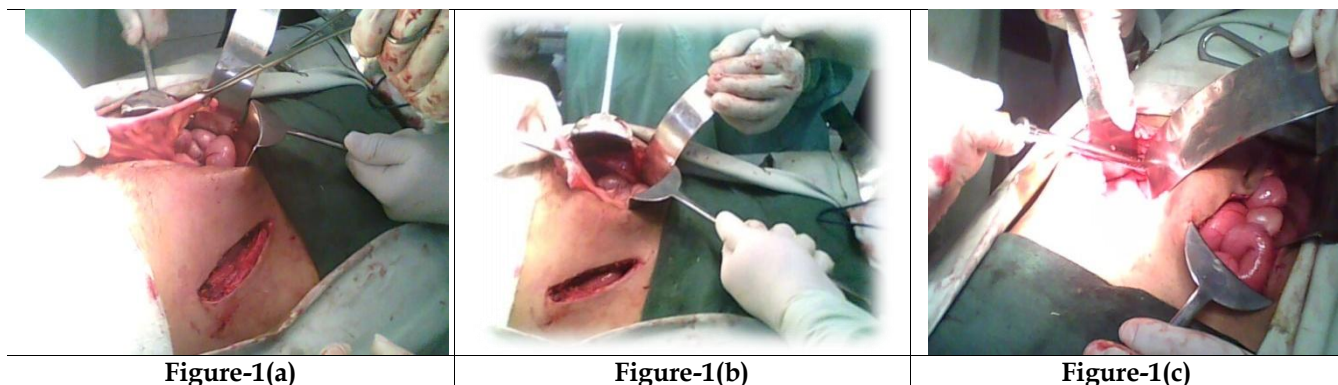


Figure-1(a,b,c): Right grid-iron and lower midline abdominal incisions showing left-sided inflamed appendix, right-sided small gut loops.

showed uneventful post-operative recovery and was discharged from hospital on 4th post-operative day.

DISCUSSION

The vermiform appendix is considered by most to be a vestigial organ. The appendix varies considerably in length and circumference. The average length is between 7.5 and 10 cm. Its importance in surgery results only from its propensity for inflammation, which results in the clinical syndrome known as "acute appendicitis".

The appendix, ileum, and ascending colon are all derived from the midgut. The appendix first appears at the 8th week of gestation as a

loop. Situs inversus totalis is a rare anatomic anomaly with an estimated incidence of 1:20,000 in the general population and an autosomal recessive mode of inheritance². SI develops when the rotation is made in a 270° clockwise direction and results in complete reversal of all abdominal viscera and a left-sided appendix. The incidence of acute appendicitis associated with SIT is reported to be between 0.016% and 0.024%.

Malrotation develops when there is nonrotation or incomplete rotation of the midgut loop around the axis of the superior mesenteric artery. The incidence of MM cited in the literature varies from 0.03% to 0.5% in live births. Because of the unusual displacement of the abdominal

viscera in SI, the symptom of acute appendicitis can involve left lower-quadrant pain, making diagnosis very difficult in these patients.

According to published reports in the literature, LSAA occurs between the age of 8 and 63 years and is 1.5-fold more frequent in men than in women. The mean age of the patients was 29.3 ± 16.1 (range: 8-82) years and the male/female sex ratio was 3:2.

Obstruction of the lumen is believed to be the major cause of acute appendicitis. This may be due to inspissated stool, lymphoid hyperplasia, vegetable matter or seed, parasites, or a neoplasm. The flora in the normal appendix is very similar to that in colon, with a variety of facultative aerobic and anaerobic bacteria.

Left-sided acute appendicitis is a diagnostic dilemma, because the appendix is located in an abnormal position. The differential diagnosis of LSAA may not be promptly established in the emergency setting and is often delayed due to lack of uniformity in the clinical signs. It is assumed that even though the viscera are transposed, the nervous system may not show the corresponding transposition, which may result in confusing symptoms and signs. In about 18.4%-31% of patients with SIT and MM, the pain caused by LSAA has been reported in the right lower quadrant.

The typical clinical presentation begins with periumbilical pain, anorexia and nausea. The pain then localizes to the right lower quadrant and a bout of vomiting may occur. Occasionally the patients may have urinary symptoms or microscopic hematuria, perhaps owing to inflammation of periappendiceal tissues adjacent to ureter or urinary bladder.

In case of abnormal anatomical site of appendix as in situs inversus or gut mal-rotation, atypical presentation begins with epigastric pain radiating to left lower quadrant of abdomen along with tenderness confusing with diverticulitis. Diverticulitis is hardly seen below the age of 40 years. Clinical presentation can be 'acute' or 'chronic'. The clinical picture of sigmoid diverti-

culitis very much resembles that of appendicitis and is often called 'left sided appendicitis'. Pain is the most important symptom. Pain is usually mild to moderate and is felt deep in the left lower quadrant or supra-pubic region.

The differential diagnosis of left lower quadrant abdominal pain includes: diverticulitis, renal colic, ruptured ovarian cyst, Meckel's diverticulitis, epididymitis, incarcerated or strangulated hernia, bowel obstruction, regional enteritis, psoas abscess, and right- and left-sided appen-

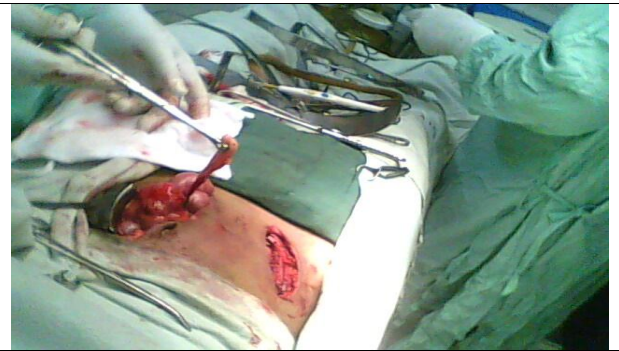


Figure-2(a)

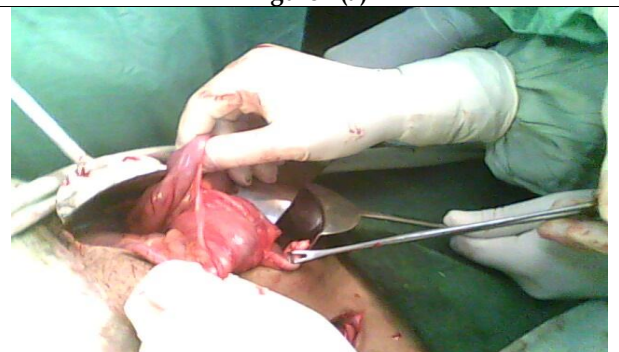

Figure-2(b)

Figure-2(a,b): Showing left-sided acutely inflamed appendix, left-sided mal positioned caecum, ascending colon.

dicitis (LSAA).

The diagnosis of acute appendicitis in patients with SIT or MM can be based on physical examination, electrocardiogram, chest x-ray, barium studies, USG, CT scan and diagnostic laparoscopy.

Blood complete picture generally shows elevated white blood count with more than 75% neutrophils in most patients. Urinalysis can also be helpful in excluding pyelonephritis or nephro-

lithiasis. Plain radiographs are usually not helpful for establishing the diagnosis of appendicitis. However, the detection of dextrocardia on chest x-ray and right-sided gastric bubble on abdominal plane x-ray is of considerable value in establishing the diagnosis of SIT. Barium enema with gastrografin can reveal MM or SIT, when there are difficulties in making the diagnosis of acute left lower quadrant pain.

Over the last two decades, there has been an increasing use of imaging modalities, such as USG and CT, in the diagnosis of acute appendicitis. USG is widely used in cases of appendicitis. Ultrasonography has a sensitivity of about 85% and a specificity of more than 90% for the diagnosis of acute appendicitis, however, it has significant limitations: it is operator-dependent, and examination of the lower quadrant can be compromised in patients with large body habitus or by overlying bowel gas.

The value of CT in the diagnosis of acute appendicitis has been well-documented, with a reported accuracy of 90%-98%. USG and CT may also be helpful in the detection of SIT and MM.

Diagnostic laparoscopy can provide direct examination of appendix and anatomical anomalies and is gold standard in diagnostic difficulties.

Most patients with acute appendicitis are managed by prompt surgical removal of appendix after a brief period of resuscitation.

Mortality rate after appendectomy is <1%. The morbidity of perforated appendicitis is higher than that of nonperforated cases and is related to increased rates of wound infection and intra-abdominal abscess formation.

CONCLUSION

Left-sided acute appendicitis should be considered in the differential diagnosis of young patients presenting with pain localized in the left lower quadrant. Left-sided appendix is rarely seen and is frequently associated with situs inversus totalis (SIT) and midgut malrotation (MM).

High degree of suspicion regarding abnormal anatomical site of appendix and

caecum should be kept in mind in cases of atypical clinical presentation. Chest x-ray, abdominal USG and CT provide quite useful information. Diagnostic laparoscopy is the gold standard in cases with complicated differential diagnosing. Clinical assessment/judgment has no match in diagnosis and avoiding serious complications.

CONFLICT OF INTEREST

This study has no conflict of interest to be declared by any author.

REFERENCES

- Hou SK, Chern CH, How CK, Kao WF, Chen JO, Wang LM et al. Diagnosis of Appendicitis with left lower quadrant pain. *J Chin Med Assoc* 2005; 68: 5999-603.
- Hollander SC, Springer SA. The diagnosis of acute left-sided appendicitis with CT scan. *Pediatr Radiol* 2003; 33: 70-71.
- Welte FJJ, Grosso M. Left-sided appendicitis in a patient with congenital gastrointestinal tract mal-rotation, a case report. *J Med Case reports* 2007; 1: 92.
- Norman S. Williams. Bailey & Love's Short Practice of Surgery 25th Edition 2008; chapter 67: 1205.
- Prystwsky JB, Pugh CM, Nagle AP. Current problems in surgery: Appendicitis. *Curr Probl Surg* 2005; 42: 688-72.
- John Maa, Kimberly S. Kirkwood. Sabistan Textbook of Surgery 19th Edition 2012; chapter 49: 1333-33.
- Schumpelick V, Dreuw B, Ophoff K, Prescher A. Surg Clin North Am. Appendix and cecum. Embryology, anatomy, and surgical applications. Department of Surgery, University Hospital, University of Technology at Aachen, Germany 2006; 80(1): 295-318.
- Keith JC, Thoma JJ, Bugay SJ, Price PD, Smear J. Asymptomatic midgut rotational anomalies in adults: 2 case reports and review of the literature. *Contemp Surg*. 2003; 59: 322-25.
- Akbulut S, Caliskan A, Ekin A. Left-sided acute appendicitis with situs inversus totalis: review of 63 published cases and report of two cases. *J Gastrointest Surg* 2010; 14(9): 1422-8.
- Welte FJ, Grosso M. Left-sided appendicitis in a patient with congenital gastrointestinal malrotation: a case report. *J Med Case Reports* 2007; 1: 92.
- Pillow MT, Valle C. Appendicitis in an uncommon location. *West J Emerg Med* 2010; 11: 115.
- Bedoui R, Ali Ouaer M, Nouria R, Dziri C. Acute left-sided appendicitis. *Tunis Med* 2009; 87(12): 873-4.
- Bedoui R, Ali Ouaer M, Nouria R, Dziri C. Acute left-sided appendicitis. *Tunis Med* 2009; 87(12): 873-4.
- Maa J, Kimberly S. Kirkwood. Sabistan Textbook of Surgery 18th Edition 2008; Chapter 49: 1334-34.
- Hou SK, Chern CH, How CK, Kao WF, Chen JD, Wang LM et al. Diagnosis of appendicitis with left lower quadrant pain. *J Chin Med Assoc* 2005; 68(12): 599-603.
- Williams NM, Johnston JM, Everson NW. The diagnostic value of symptoms and signs in childhood abdominal pain. *JR Coll Surg Edinb* 2007; 43(6): 390-92.
- Shapiro NM, Michels LM, Hurwitz S. Appendicitis with typical symptoms but ectopic appendix due to malrotation of colon. *Calif Med* 2004; 98: 158-59.

18. Schwartz JH, Manco LG. Left-sided appendicitis. *J Am Coll Surg* 2008; 206(3): 590.
 19. Ambrosetti P, Robert JH, Witzig JA. Acute left colonic diverticulitis in young patients. *J Am Coll Surg* 2004; 179: 156-60.
 20. Hou SK, Chern CH, How CK, Kao WF, Chen JD, Wang LM et al. Diagnosis of appendicitis with left lower quadrant pain.
 21. Perera WR, Hennessy OF. Clinical Images. An unusual case of appendicitis. *Am J Surg* 2010; 199(6): e79-81.
 22. Ooms HW, Koumans RK, Ho Kang You PJ, Puy Laert JB. Ultrasonography in the diagnosis of acute appendicitis. *Br J Surg* 2001; 78(3): 315-18.
 23. Hollander SC, Springer SA. The diagnosis of acute left-sided appendicitis with CT. *Pediat Radiol* 2003; 33: 70-71.
 24. Song JY, Rana N, Rotman CA. Laparoscopic appendicectomy in a female patient with situs inversus: case report and literature review. *JSLs* 2004; 8: 175-77.
 25. Faiz O, Clark J, Brown T. Traditional and laparoscopic appendicectomy in adults: outcomes in English NHS hospitals between 1996 and 2006. *Ann Surg* 2008; 248-70.
 26. Nadler EP, Reblock KK, Vaughan KG. Predictors of outcome for children with perforated appendicitis initially treated with non-operated management. *Surg Infect (larchmt)* 2004; 5: 349-56.
-