

DIAGNOSTIC ACCURACY OF SPLENIC ARTERY PULSATILITY INDEX IN PREDICTING FIBROSIS ASSOCIATED WITH CHRONIC HEPATITIS C

Hidayat Ullah, Atiq Ur Rehman*, Huma Aslam*

Yusra Medical and Dental College Islamabad Pakistan, *Armed Forces Institute of Radiology & Imaging/National University of Medical Sciences (NUMS) Rawalpindi Pakistan

ABSTRACT

Objective: To find the diagnostic accuracy of splenic artery pulsatility index in predicting fibrosis associated with chronic hepatitis C.

Study Design: Cross-sectional validation study.

Place and Duration of Study: Armed Forces Institute of Radiology and Imaging Rawalpindi, Departments of Medicine and Pathology, Pak Emirates Military Hospital Rawalpindi, from Sep 2014 to Feb 2015.

Material and Methods: Seventy-five patients with evidence of HCV infection as detected by positive anti HCV antibodies and HCV RNA for more than 6 months were recruited in this study using consecutive sampling. Ultrasound evaluation of liver and spleen was carried out after overnight fast along with doppler evaluation of splenic artery. Histopathological findings, of the subsequently done liver biopsy, were recorded as gold standard. Findings were recorded on the already prepared proforma. Statistical package for social sciences version 20 was used for the analysis of the data.

Results: The average age of the patients was 36.87 ± 8.16 years. Sensitivity, specificity, Positive predictive value, negative predictive value and diagnostic accuracy of increased splenic artery pulsatility index in assessing the severity of hepatic fibrosis were 80.8%, 91.8%, 84%, 90% and 88% respectively. ROC curve showed area under the curve to be 0.917 with $p < 0.001$.

Conclusion: Splenic artery pulsatility index is a simple, non-invasive and reproducible technique for assessing hepatic fibrosis in patients with chronic hepatitis C and can reduce the number of staging liver biopsies.

Keywords: Chronic hepatitis C, Hepatitis C infection, Splenic artery pulsatility index.

This is an Open Access article distributed under the terms of the Creative Commons Attribution License (<http://creativecommons.org/licenses/by/4.0>), which permits unrestricted use, distribution, and reproduction in any medium, provided the original work is properly cited.

INTRODUCTION

Chronic liver disease (CLD), with hepatitis C infection being one of its major causes, is a significant cause of morbidity and mortality all across the globe^{1,2}. It has been estimated that as many as 170 million people are affected by Hepatitis C (HCV) worldwide and it is like a viral pandemic³. In Pakistan more than 10 million people are infected with high morbidity and mortality⁴. Other causes of CLD apart from the chronic forms of viral hepatitis include alcohol abuse and metabolic disorders⁵. Some 50% of the cases with chronic liver disease progress to cirrhosis. The diagnosis of cirrhosis is based on histological proof of diffuse fibrosis associated with architecturally abnormal regenerative

nodules². Liver biopsy is the traditional gold standard to establish the diagnosis and grade degree of liver damage, stage chronic liver disease and evaluate extent of disease progression⁵. It is considered safe however it is not cost effective, causes discomfort to the patient and is associated with the potential risks of many complications like bleeding, damage to biliary tree and even pneumothorax⁶. Ultrasonography is a non-invasive, inexpensive and easily repeatable modality which is useful in the diagnosis and follow up of patients with chronic liver disease⁷. Doppler ultrasound of the portal and hepatic veins plays its role in the evaluation of chronic liver disease. With the progressive hepatic fibrosis, the portal resistance increases, causing the increased outflow resistance of the splenic artery⁸. Splenic artery impedance indices i.e. resistive index (RI) and pulsatility index (PI) have been shown to play a significant role in

Correspondence: Dr Atiq Ur Rehman, Assoc Prof of Diagnostic Radiology, Armed Forces Institute of Radiology & Imaging Rawalpindi Pakistan (Email: aq789@hotmail.com)

Received: 08 Sep 2017; revised received: 03 Jan 2018; accepted: 12 Mar 2018

diagnosing CLD⁹. Doppler assessment of splenic impedance indices is carried out within the splenic parenchyma, and a value of more than 0.63 for RI and more than 1.0 for PI are considered suggestive of fibrosis associated with chronic liver disease¹⁰. This increase in splenic impedance indices is the result of decreased diastolic velocity of the splenic artery due to increased splanchnic resistance. Pulsatility index is more sensitive than resistive index because it uses mean arterial velocity instead of the peak arterial velocity in detecting the waveform changes on increased portal resistance⁸. The present study was designed to determine the accuracy of splenic artery pulsatility index (SAPI) in predicting fibrosis associated with chronic hepatitis C in our set up using liver biopsy as a gold standard.

PATIENTS AND METHODS

In this cross-sectional validation study conducted at Pak Emirates Military Hospital Rawalpindi, from Sep 2014 to Feb 2015, 75 patients were included using consecutive (non-probability) sampling technique. Sample size was calculated with the help of WHO sample size calculator taking sensitivity 88%, specificity 93%, and prevalence 50%^{9,11}. The inclusion criteria were patients of both genders aged 13 to 50 years having chronic hepatitis C as evidenced by positive anti HCV antibodies and a positive HCV RNA by PCR study for more than 6 months. The exclusion criteria were any clinical signs of decompensated chronic liver disease (ascites, jaundice, porto-systemic encephalopathy, splenomegaly as shown by a size of 13cm with or without splenic varices, evidence of portal hypertension as shown by a portal vein caliber of >13 mm, hepatopetal velocity of <15 cm/sec or flow reversal in portal vein); history of drugs or alcohol abuse; previous history of liver biopsy or not consenting for liver biopsy; pregnant women and a history of hypertensive/ischemic heart disease. Approval of the study was obtained from the ethical committee of the hospital. Ultrasonography was performed in the morning after overnight fast using Toshiba Nemio XG (TA

312) real time Ultrasound scanner with doppler facility. Using a 3.75 MHz sector transducer through a trans-abdominal approach, B Mode, color doppler and spectral doppler ultrasound examination was carried out by a consultant radiologist having more than 5 years' experience in abdominal sonography. The patients were examined in supine position and SAPI was measured by placing the sampling cursor in the main branches of the intra splenic artery near the splenic hilum at the left 11th intercostal space. A splenic artery pulsatility index of value >1.0 was considered to be abnormal. Liver biopsy was performed in department of medicine. Findings of doppler ultrasound and histopathology report were recorded on an already prepared proforma. All data was entered and analyzed by using SPSS version 20. For continuous variable (age) descriptive statistics like mean with standard deviation was calculated. For categorical variables (like gender and splenic artery pulsatility index) frequencies along with percentages were calculated. A 2x2 table was used to determine sensitivity, specificity, positive predictive value, negative predictive value and diagnostic efficacy.

RESULTS

A total of 75 patients with evidence of HCV infection were recruited in this study with average of the patients being 36.87 ± 8.16 years (table-I). There were 61.33% (n=46) males and 38.67% (n=29) females with male to female ratio of about 1.59. Splenic artery pulsatility index is presented in fig-1. Diagnostic accuracy of splenic artery pulsatility index in predicting fibrosis associated with chronic hepatitis C as shown by liver biopsy is presented in table-II. Abnormal SAPI (>1.0) was observed in 33.3% (n=25), out of which 21 cases were true positive (TP) on histopathology with positive predictive value (PPV) of 88%. Normal SAPI was observed in 66.7% (n=50), out of which 5 cases were found to be false negative (FN) on histopathology with negative predictive value (NPV) of 90%. Histopathologically, 34.7% (n=26) cases were found to be positive for fibrosis, out of which 5 cases had

normal SAPI giving a sensitivity of 80.8%. Liver biopsy showed no fibrosis in 65.3% (n=49), out of which 4 had abnormal SAPI giving a specificity of 91.8%. Accuracy of the color Doppler/spectral Doppler for detecting fibrosis associated with in chronic hepatitis C was found to be 88%.

Receiver operating characteristic (ROC) curve for different cut off levels was plotted (fig-2). Sensitivity and specificity for cut off level

not only entails parenchymal but also porto-splanchnic hemodynamic changes, both subsequently leading to the development of irrevocable end stage chronic liver disease^{10,14}. In addition to hepatic parenchymal disease evaluation on grey scale imaging, the introduction of duplex doppler ultrasonography has proven to be a breakthrough in evaluation of splanchnic hemodynamic changes set in secondary to portal

Table-I: Descriptive statistics of age of the patients (n=75).

Statistics		Age (Years)
Mean		36.87
95% Confidence Interval for Mean	Lower Bound	34.99
	Upper Bound	38.74
Median		38.00
Std. Deviation		8.161
Minimum		21
Maximum		50
Interquartile Range		15

Table-II: Diagnostic accuracy of increased splenic artery pulsatility index by comparing it with histopathological changes.

Color Doppler and Spectral Doppler	Histopathology		Total
	Cirrhosis	Normal	
Abnormal splenic artery pulsatility index (>1.0)	21 (TP)	4 (FP)	25 (33.3%)
Normal splenic artery pulsatility index (≤1.0)	5 (FN)	45 (TN)	50 (66.7%)
Total	26 (34.7%)	49 (65.3%)	75
Sensitivity	=21/26	=80.8%	
Specificity	=45/49	=91.8%	
PPV	=21/25	=84%	
NPV	=45/50	=90%	
Accuracy	=(21+45)/75	=88%	

value of SAPI >1.0 was found to be 80.8% (95% confidence interval of 60.6-93.4) and 91.8% (95% confidence interval of 80.4-97.7) respectively.

DISCUSSION

Ultrasonography being a readily available imaging modality is widely considered as a method of choice for the initial evaluation of hepatic parenchymal disease. The imaging findings as detected on ultrasonography in patients suspected to have chronic liver disease show a reasonably high concordance ranging between 74-88% in detecting hepatic cirrhosis¹³. HCV associated chronic liver disease spectrum

hypertension, a known insidious complication of chronic liver disease^{10,15, 16}. Despite the availability of modern diagnostic facilities, the prevalence of advanced stage chronic liver disease among freshly diagnosed cases of hepatitis C is about 20%¹⁷. splenic artery impedance evaluation, although rarely employed in chronic liver disease evaluation, has proven to be an important indicator in assessing the severity of fibrosis in patients suffering from chronic liver disease¹⁸. In this study, the average age of the patients was 36.87 ± 8.16 years. Male to female ratio was 1.59. This corresponds well with Araujo who studied epidemiology of hepatitis B and C in Brazil and

reported a male predominance and a mean age of approximately 40 years¹⁹. Portal vein and splenic artery, although appear to be lying at two ends of vascular spectrum, are intricately interconnected hemodynamically with the intra splenic arterial impedance showing an unexpected rise, correla-

portal pressure could be predicted by using a formula using the splenic PI and the portal vein flow²² splenic artery pulsatility index, thus, offers a non-invasive method of assessing the spleno-portal haemodynamics and helps in predicting the status of the hepatic fibrosis and the resulting

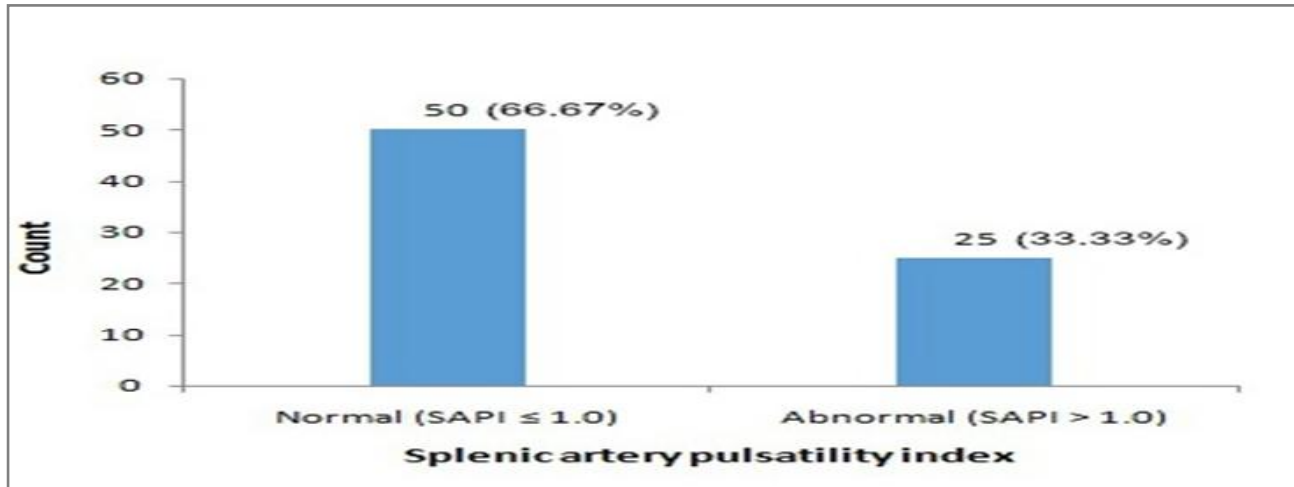


Figure-1: Splenic artery pulsatility index (n=75).

ting well with portal venous hypertension. The exact pathophysiology behind this altered flow impedance in splenic artery is based on the presupposition that although the peak systolic velocity is based on cardiac systole, the end diastolic velocity is dependent on portal venous outflow. As portal hypertension sets in, there is resistance to venous outflow with subsequent development of venous congestion in spleen attributable to erythrocyte accumulation within the red pulp of spleen. Since vascular impedance depends on arterial resistance, venous compliance and venous congestion, an increase in venous congestion within the spleen leads to reduced diastolic velocities in the splenic artery and subsequently elevated resistance indices²⁰. Normal value for resistive index (RI=peak systolic velocity–end diastolic velocity/peak systolic velocity) is ≤0.63 while the normal value for pulsatility index (PI = Peak systolic velocity–End diastolic velocity/Mean velocity) is taken as ≤1.0^{10,18}, because of taking in to account mean velocity instead of peak systolic velocity, pulsatility index is preferred as compared to resistive index^{9,21}. Bolognesi et al showed that

changes in the portal system due to chronic liver disease²². This study shows similar results confirming splenic artery pulsatility index to be a

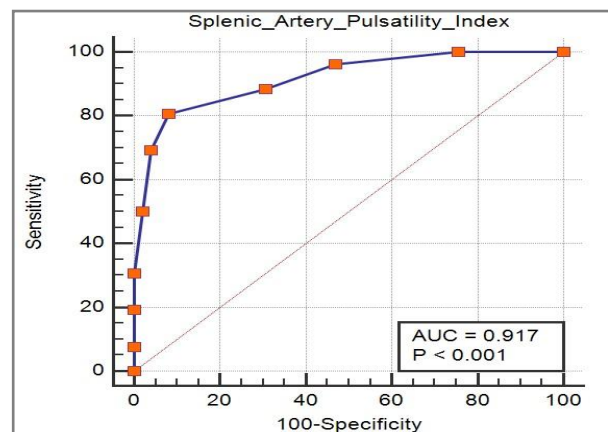


Figure-2: Receiver Operating Characteristic Curve: Area under the ROC curve is 0.917 with $p < 0.001$ and standard error of 0.0341 and 95% Confidence Interval 0.830 - 0.968.12 Sensitivity and specificity for cut off value of >1.0 for SAPI are 80.8% and 91.8% respectively.

reliable predictor of hepatic fibrosis and portal hypertension. Liver biopsy is considered to be the gold standard for evaluating and grading hepatic fibrosis. However, it is expensive and associated

with significant risk of complications including patient discomfort, significant morbidity, and mortality²³. Splenic artery pulsatility index offers a noninvasive tool for assessing chronic liver disease and associated hepatic fibrosis. This study shows that splenic artery PI is a good indicator of portal hypertension as a result of cirrhosis and the use of this simple technique can decrease the much invasive techniques like liver biopsy. This corresponds well with Liu et al who found splenic artery pulsatility index to be a precise and reproducible technique to assess the degree of hepatic fibrosis in chronic hepatitis C which could significantly reduce the number of staging liver biopsies⁸. Treatment given to patients of chronic liver disease depends on severity of liver damage. End stage of liver disease does not have specific treatment except the management of complications²⁴. On the other hand curative medical treatment in HCV infection can stop the progression of liver damage and is given to patients who have not already developed cirrhosis²⁵. High sensitivity and specificity of SAPI in predicting hepatic fibrosis associated with chronic hepatitis C as shown by this study make Doppler examination of the splenic artery a useful alternative to liver biopsy for identifying liver fibrosis in non cirrhotic patients. The strength of our study is the comparison of Doppler findings in splenic artery with histopathologic changes as seen on liver biopsy. This made the objective assessment of pulsatility index as an indicator of hepatic fibrosis in chronic hepatitis C possible.

LIMITATION OF STUDY

Using a relatively small sample size is a limitation of the study. The study focuses on one parameter for predicting fibrosis associated with chronic hepatitis C while to avoid liver biopsy other parameters might also need to be taken in to account.

CONCLUSION

Splenic artery pulsatility index is a simple, non-invasive and reproducible technique for assessing hepatic fibrosis in patients with chronic

hepatitis C and can reduce the number of staging liver biopsies.

RECOMMENDATION

Therefore, more studies with a large sample size and taking in to account other ultrasound parameters in local setup will be helpful in confirming the findings of this study and explore more relevant parameters.

CONFLICT OF INTEREST

This study has no conflict of interest to be declared by any author.

REFERENCES

1. Williams R. Global challenges in liver disease. *Hepatology* 2006; 44(3): 521-6.
2. Javed K, Azam MN, Akram MH. Correlation of doppler waveform abnormalities of hepatic veins with histological findings in chronic liver disease (Hcv Infection). *Pak Armed Forces Med J* 2008; 58: 414-17.
3. Lavanchy D. The global burden of hepatitis C. *Liver International* 2009; 29(s1): 74-81.
4. Raja NS, Janjua KA. Epidemiology of hepatitis C virus infection in Pakistan. *J Microbiol Immunol* 2008; 41(1): 4.
5. Allan R, Thoires K, Phillips M. Accuracy of ultrasound to identify chronic liver disease. *World J Gastroenterol* 2010; 16(28): 3510-20.
6. CarEy E, Carey WD. Noninvasive tests for liver disease, fibrosis, and cirrhosis: Is liver biopsy obsolete? *Cleve Clin J Med* 2010; 77(8): 519-27.
7. Najafizadeh M, Karayev Z, Farhadi N. Role of Liver Ultrasound in Diagnostic Process of Hepatitis C Disease: Comparison with Serum Inflammatory Indices Level and T-Helper 1 Cytokine Responses. *Res J Biol Sci* 2009; 4(2): 200-3.
8. Liu CH, Hsu SJ, Lin JW, Hwang JJ, Liu CJ, Yang PM, et al. Noninvasive diagnosis of hepatic fibrosis in patients with chronic hepatitis C by splenic Doppler impedance index. *Clin Gastroenterol Hepatol* 2007; 5(10): 1199-206.
9. Leão J, Brock M, Castilho M, Scariot A, Scariot A, Braga W. Non-invasive assessment of fibrosis using color Doppler ultrasound in patients with hepatitis C virus in the Amazon rainforest, Brazil. *Am J Trop Med Hyg* 2012; 86(2): 273-9.
10. Piscaglia F, Donati G, Serra C, Muratori R, Solmi L, Gaiani S, et al. Value of splanchnic Doppler ultrasound in the diagnosis of portal hypertension. *Ultrasound in medicine & biology* 2001; 27(7): 893-9.
11. Dienstong J. Harrison's principles of internal medicine. 17th ed. Fauci A, Kasper D, Longo D, Braunwald E, Hauser S, Jameson J, editors. New York: McGraw Hill; 2008.
12. DeLong ER, DeLong DM, Clarke-Pearson DL. Comparing the areas under two or more correlated receiver operating characteristic curves: A nonparametric approach. *Biometrics* 1988; 837-45.
13. Vezozzo D. Radiologia convencional e ultra-sonografia. *Doenças do Fígado e Vias Biliares Sao Paulo: Atheneu* 2001:173-93.
14. Cerri G. Estudo Doppler na Hipertensão Portal. *Radiol Bras* vol.37 no.1.

15. Moriyasu F, Nishida O, Ban N, Nakamura T, Sakai M, Miyake T, et al. "Congestion index" of the portal vein. *Am J Roentgenol* 1986; 146(4): 735-9.
 16. Smith J, Sterling R. Systematic review: non invasive methods of fibrosis analysis in chronic hepatitis C. *Alimentary pharmacology & therapeutics* 2009; 30(6): 557-76.
 17. Ullah H, Rehman AU, Zafar A. Prevalence of different sonographic stages among newly diagnosed cases of chronic hepatitis C. *Pakistan Armed Forces Med J* 2017; 67(2): 276-82.
 18. Bolognesi M, Sacerdoti D, Merkel C, Gerunda G, Maffei Faccioli A, Angeli P, et al. Splenic Doppler impedance indices: influence of different portal hemodynamic conditions. *Hepatology* 1996; 23(5): 1035-40.
 19. Araújo ARSd. Hepatites B e C em Manaus: perfil clínico-epidemiológico e distribuição espacial de casos conhecidos desde 1997 a 2001-2004.
 20. Sacerdoti D, Gaiani S, Buonamico P, Merkel C, Zoli M, Bolondi L, et al. Interobserver and interequipment variability of hepatic, splenic, and renal arterial Doppler resistance indices in normal subjects and patients with cirrhosis. *J Hepatol* 1997; 27(6): 986-92.
 21. Rifkin MD, Needleman L, Pasto ME, Kurtz AB, Foy PM, McGlynn E, et al. Evaluation of renal transplant rejection by duplex Doppler examination: value of the resistive index. *Am J Roentgenol* 1987; 148(4): 759-62.
 22. Bolognesi M, Sacerdoti D, Merkel C, Bombonato G, Gatta A. Noninvasive grading of the severity of portal hypertension in cirrhotic patients by echo-color-Doppler. *Ultrasound in Medicine & Biology* 2001; 27(7): 901-7.
 23. Cadranet JF, Rufat P, Degos F. Practices of liver biopsy in France: results of a prospective nationwide survey. *Hepatology* 2000; 32(3): 477-81.
 24. Kamath PS, Wiesner RH, Malinchoc M, Kremers W, Therneau TM, Kosberg CL, et al. A model to predict survival in patients with end stage liver disease. *Hepatology* 2001; 33(2): 464-70.
 25. Ghany MG, Strader DB, Thomas DL, Seeff LB. Diagnosis, management, and treatment of hepatitis C: an update. *Hepatology* 2009; 49(4): 1335-74.
-