

THE SPECTRUM OF RADIOLOGICAL FINDINGS IN PATIENTS PRESENTING WITH DIFFERENT CLINICAL INDICATIONS FOR CRANIAL COMPUTED TOMOGRAPHIC SCAN

Hussain Rashid Ihsan, Salman Ahmad*, Saeed Bin Ayaz*

Pakistan Naval Ship (PNS) Shifa Karachi Pakistan, *Combined Military Hospital Quetta/National University of Medical Sciences (NUMS) Pakistan

ABSTRACT

Objectives: To identify the main reasons for seeking computed tomography (CT) scan evaluation and primary brain and skull pathologies seen on CT scan and to determine the percentage of negative and positive CT scans for a particular referring reason and correlate the commonest reason for seeking CT scan evaluation with age and gender.

Study Design: A cross-sectional study.

Place and Duration of Study: Department of Radiology, Sheikh Khalifa Bin Zaid Al Nahyan Hospital Muzaffarabad, Azad Jammu and Kashmir, from Jan to Sep 2016.

Material and Methods: Through consecutive sampling, we included 137 patients referred for radiological evaluation of skull and brain through CT scan. The study was performed by a senior CT scan technologist using CT scan machine Brilliance CT 16 slice - DS, taking 0.5 mm slices in all patients and reviewed by a consultant radiologist. The sample was divided into two age-groups i.e. age ≤ 36 years and age > 36 years. The data were analysed using statistical program Statistical Package for Social Sciences version 20.0.

Results: Out of 137 individuals, (mean age: 34 ± 23 years), 86 (62.8%) were male and 51 (37.2) were female. The majority (61.3%, $n=84$) of the individuals were referred for complaint of head trauma. The head trauma was significantly more common in age group of ≤ 36 years ($p < 0.001$) and males were more involved in head trauma than females (male-to-female ratio of 2:1, odds ratio: 1.53, confidence interval: 0.76-3.11). On CT scan evaluation, 19.7% ($n=27$) had a normal study while 80.3% ($n=110$) had at least one abnormal finding. Fracture of the skull bones (with or without other abnormalities) was the commonest abnormality found in 46.4% ($n=51$) patients. Higher percentage of positive CT scan was found in patients with all sorts of presenting complaints.

Conclusion: The majority were referred for cranial CT scan evaluation for the complaints of head trauma. Fracture of the skull bones was the commonest finding. Head trauma was significantly more common in age-group of ≤ 36 years and males were more commonly involved than females. Higher percentage of positive CT scan was found in patients with all sorts of presenting complaints.

Keywords: Brain pathologies, Computed tomography scan, Skull pathologies.

This is an Open Access article distributed under the terms of the Creative Commons Attribution License (<http://creativecommons.org/licenses/by/4.0>), which permits unrestricted use, distribution, and reproduction in any medium, provided the original work is properly cited.

INTRODUCTION

Computed Tomography (CT) scan is a radiological modality that makes use of computer-processed combinations of many X-ray images taken from different angles to produce cross-sectional (tomographic) images (often called slices) of specific areas of a scanned object, allowing the user to see inside of the object without cutting. Digital geometry processing is

used to generate a three-dimensional image of inside of the object from a large series of two-dimensional radiographic images taken around a single axis of rotation. The CT Scan is the investigation of choice in many clinical problems to identify the primary pathology and guide the management process.

In the modern era, CT scan is the modality of choice in initial assessment of many neurological emergencies, as it is widely available, faster, and highly accurate in detection of skull fractures and acute intracranial haemorrhage¹. CT scan is also the primary modality to detect ischemic or

Correspondence: Dr Hussain Rashid Ihsan, Consultant Radiologist, PNS Shifa Karachi Pakistan

Email: doctors74@hotmail.com

Received: 23 Jun 2017; revised received: 20 Oct 2017; accepted: 27 Nov 2017

haemorrhagic nature of a stroke². In cases of migraines, headaches, and loss of consciousness, CT scan is helpful in identifying the underlying pathology as it can detect brain tumours, abscess, hydrocephalus, sinus blockage, cerebrovascular accidents, vascular malformation, and haemorrhages, etc³.

CT scan is the first-line imaging modality for the investigation of acute neurological emergencies because it is fast and readily and widely available. Image findings, in combination with Glasgow Coma Scale can be used to classify the severity of the neurological issues and guide

evaluation and brain and skull pathologies seen on CT scan films in patients referred for such evaluation. Association of traumatic vs non-traumatic etiologies with age and gender and percentage of negative and positive CT scans for a particular referring reason were secondary goals.

MATERIAL AND METHODS

It was a cross-sectional study carried out at Sheikh Khalid Bin Zaid Al-Nahyan Hospital (SKBZH), Muzaffarabad. After approval from the hospital ethical review committee of SKBZH, we

Table-I: The demographic and clinical characteristics of the sample.

Characteristics	n (%)	Characteristics	n (%)
Gender		CT Scan Evaluation	
Male	86 (62.8)	Normal	27 (19.7)
Female	51 (37.2)	Abnormality	110 (80.3)
Primary reason for referral		Abnormality seen on CT scan	
Head trauma	84 (61.3)	Fracture of the skull bones	51 (46.4)
Generalized or localized weakness	25 (18.2)	Extradural hematoma	17 (15.4)
Loss of consciousness	17 (12.4)	Cerebral infarct	16 (14.5)
Headache	5 (3.6)	Intracerebral hemorrhage	15 (13.6)
Epilepsy	3 (2.2)	Subdural hematoma	14 (12.7)
Speech abnormality	3 (2.2)	Brain contusions	12 (10.9)
		Scalp hematoma	9 (8.2)
		Age related cerebral atrophy	8 (7.3)
		Subarachnoid hemorrhage	8 (7.3)
		Hemosinus	8 (7.3)
		Hydrocephalus	6 (5.4)
		Deep white tissue ischemic changes	6 (5.4)
		Sinusitis	4 (3.6)
		Dural sinus thrombosis	3 (2.7)
		Diffuse brain swelling	2 (1.8)

the treatment in the right direction. In fact, we have observed a positive CT scan, identifying abnormalities related to the expected pathology in 80.3% of the referred cases. In the literature, the incidence of abnormal CT scan findings has been quite variable and has ranged from 37% to 100%^{1,4-7}. The chances of getting an abnormality on CT scan was found to be directly related to the severity of clinical symptoms⁸.

The studies regarding the pattern of pathologies seen on CT scan are lacking in Azad Jammu and Kashmir. This study was aimed at identifying the main reasons for seeking CT scan

sampled 145 patients who were referred from various departments of SKBZH for radiological evaluation of skull and brain using CT scan through consecutive sampling from January to September 2016. The patients with already diagnosed status epilepticus, carcinoid tumours, and other neoplastic lesions of the brain, and history of a psychiatric disorder were not included in the study. The study was performed by a senior CT scan technologist. All studies were performed using CT scan machine Brilliance CT 16 slice - DS (Koninklijke Philips Electronics, Naamloze vennootschap, The Netherlands). In all

patients, 0.5 mm slices were taken. All reports were studied and reported by a consultant radiologist.

All the data were analysed using statistical program Statistical Package for Social Sciences (SPSS) version 20.0 (IBM Corp., Armonk, NY, USA). For the analysis of association of traumatic vs non-traumatic etiologies with age, the sample was divided into two groups i.e. age ≤ 36 years and age > 36 years. Means and standard deviations were calculated for age. Frequencies and percentages were calculated for gender, the reasons for the referral, age-groups, and radiological

head trauma (table-I). The head trauma was significantly more common in the age-group of ≤ 36 years, while non-traumatic complaints were more common in the age-group of > 36 years ($p < 0.001$) (table-II). The males were more commonly involved in head trauma than females (Male-to-female ratio of 2:1, Odds ratio: 1.53, Confidence interval: 0.76-3.11) (fig-1).

On CT scan evaluation, 19.7% ($n=27$) had a normal study while 80.3% ($n=110$) had at least one abnormal finding. Fracture of the skull bones (with or without other abnormalities) was found in 46.4% ($n=51$) patients. Sixty-seven (79.8%)

Table-II: Association of traumatic vs non-traumatic etiology and age-groups.

Age group	Traumatic vs non-traumatic etiology	
	Traumatic etiology	Non-traumatic etiology
	n (%)	n (%)
Age ≤ 36 years	49 (74.2)	9 (24.3)
Age > 36 years	17 (25.8)	28 (75.7)

Thirty-four missing entries excluded; $p < 0.001$

Table-III: Correlation between clinical questions and computed tomography results.

Clinical questions	Total n (%)	Negative CT Scan n (%)	Positive CT Scan n (%)
Head trauma	84 (61.3)	17 (20.2)	67 (79.8)
Generalized or localized weakness	25 (18.2)	1 (4)	24 (96%)
Loss of consciousness	17 (12.4)	6 (35.3)	11 (64.7)
Headache	5 (3.6)	2 (40)	3 (60)
Epilepsy	3 (2.2)	1 (33.3)	2 (66.7)
Speech abnormality	3 (2.2)	0	3 (100)

finding on CT scan. The odds ratio was calculated for gender association with traumatic vs non-traumatic etiologies, while Chi-square test was applied for the association of age-group with traumatic vs non-traumatic etiologies. A p -value less than 0.05 was considered significant.

RESULTS

Out of a total of 137 individuals finally included, 86 (62.8%) were male and 51 (37.2) were female. The mean age of the sample was 34 ± 23 years with a range of 2-85 years. Fifty-eight individuals were ≤ 36 years of age, while forty-five individuals were > 36 years of age (56.3% and 43.7% respectively after eliminating thirty-four missed entries). The majority (61.3%, $n=84$) of the individuals were referred for the radiological evaluation by CT scan for the complaints of

individuals with a history of head trauma showed an abnormal pathology on CT scan related to trauma. The common abnormalities other than the fracture were extradural hematoma ($n=17$), cerebral infarct ($n=16$), intracerebral haemorrhage ($n=15$), and subdural hematoma ($n=14$) (table-I). The correlation between clinical questions and CT scan results is shown in table-III.

DISCUSSION

We observed that the majority of individuals were referred for the radiological evaluation by CT scan for the complaints of head trauma. The cases of head trauma are increasing worldwide due to increased incidence of motor vehicle accidents (MVA) and acts of violence. Head trauma and the related traumatic brain injury is

more common in persons younger than 35 years and the male-to-female ratio is nearly 2:1¹⁹. We found a similar trend as head trauma was significantly more common in the age-groups of ≤ 36 years and male-to-female ratio was exactly 2:1. The apparent reason for male gender predominance appears to be greater participation of males in the outdoor activities. The social and cultural values in many countries entail male population to be more involved in work, sports, and other outdoor activities as compared to the females. Therefore, the exposure to MVA, acts of violence, and environmental calamities is greater among males than females.

CT is the imaging modality of choice for detecting fractures and depending on the type and location of fractures, quick surgical intervention can be done to prevent cerebrospinal fluid leak, infection, thrombosis, infarct or haemorrhage¹. The literature shows an incidence of 3.1% to 80% of skull fractures seen radio-logically in cases of acute head trauma^{1,10-18}. We found that 60.7% of individuals with a history of head trauma showed a fracture. While including pathologies related to fracture, this percentage increased to 79.8% and thus facilitated prompt appropriate treatment.

The other common abnormalities seen on CT scan were extradural hematoma (15.4%), cerebral infarct (14.5%), intracerebral haemorrhage (13.6%), subdural hematoma (12.7%), and brain contusions (10.9%). Tomar *et al*, in an Indian study, found the incidence of extradural hematoma, intracerebral haemorrhage, brain contusion, and subdural hematoma to be 12%, 26%, 22%, and 18% respectively in a sample of 100 patients of head trauma who underwent cranial CT scan¹. Imtiaz, in another Indian study found an incidence of 4%, 15%, 43%, and 21% respectively for the above-mentioned CT scan findings in a sample of 100 individuals¹⁷. Zimmerman and colleagues, in an American study, found incidence of the abnormalities in the same order as 4.9%, 6.3%, 21.3%, and 12.6% respectively in 286 patients of head trauma¹⁶. Hidayat, in an Iraqi study, observed incidence of 16%, 46%, 44%,

and 38% respectively for the same findings in the above-mentioned order¹⁹. Lobato *et al*, in a Spanish study, observed incidence of 13.7%, 31.4%, and 20.2% for extradural hematoma, brain contusions, and subdural hematoma in 277 cases of head injury²⁰.

For other complaints of generalized or localized weakness, loss of consciousness, headache, epilepsy, and speech abnormality, we also found a higher percentage of positive CT scans, which verifies the importance of CT scan evaluation in such abnormalities. The medical literature endorses the usage of CT scan in

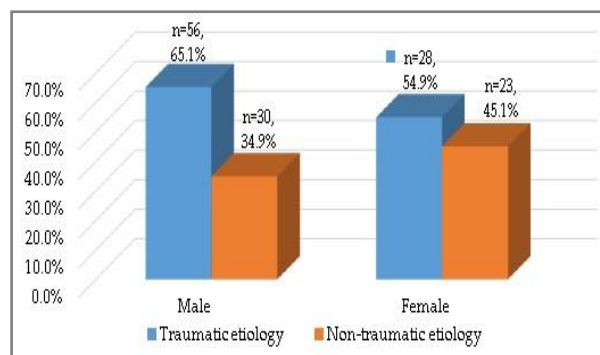


Figure: Distribution of traumatic etiology among the two genders.

evaluation, depending upon the clinically observed necessity, of patients with headaches, loss of consciousness, and suspected cerebrovascular accident²¹⁻²³. However, the literature advises against routine use of CT scan for all patients with new onset nonfebrile seizures²⁴. We suggest that all patients with suspected acute neurological emergency must be evaluated by CT scan examination. Advantages with CT scan evaluation include rapid diagnosis and real-time observation of etiologies that might be lethal to the patient. CT scan decreases the rate of mismanagement, hence better care of the patients can be warranted in time.

CONCLUSION

The majority of individuals were referred for the radiological evaluation by CT scan for the complaint of head trauma. Fracture of the skull bones was the commonest abnormality seen on CT scan evaluation. Head trauma was signi-

ificantly more common in age groups of ≤ 36 years and males were more commonly involved than females. Higher percentage of positive CT scan was found in patients with all types of presenting complaints. CT scan is a reliable, highly accurate, and sensitive modality in evaluation of patients with acute neurological emergencies. It may clearly outline those patients who require surgery or other form of intervention, so it can provide rapid, effective diagnostic information to guide appropriate clinical management.

CONFLICT OF INTEREST

This study has no conflict of interest to be declared by any author.

REFERENCES

- Tomar SS, Bhargava A, Reddy N. Significance of computed tomography scans in head injury. *Open J Clin Diagn* 2013; 3: 109-14.
- Barber PA, Demchuk AM, Zhang J, Buchan AM. Validity and reliability of a quantitative computed tomography score in predicting outcome of hyperacute stroke before thrombolytic therapy. ASPECTS Study Group. *Alberta Stroke Programme Early CT Score*. *Lancet* 2000; 355 (9216): 1670-4. Erratum in: *Lancet* 2000; 355(9221): 2170.
- Neurology emergencies. In: Cameron P, Jelinek G, Kelly AM, Brown A, Little M, eds. *Textbook of adult emergency medicine*, 4th Edn, GB: Elsevier Health Sciences, 2014; pp 368-401.
- Af-Geijerstam JL, Oredsson S, Britton M, OCTOPUS Study Investigators. Medical outcome after immediate computed tomography or admission for observation in patients with mild head injury: randomised controlled trial. *BMJ* 2006; 333(7566): 465.
- Mushtaq S, Bodla MA. Diagnostic accuracy of computed tomography for subarachnoid haemorrhage in patients presenting with thunderclap headache (Lumbar Puncture as Gold Standard). *Pak J Med Health Sci* 2014; 8(2): 344-6.
- Sosin DM, Sniezek JE, Thurman DJ. Incidence of mild and moderate brain injury in the United States, 1991. *Brain Inj* 1996; 10(1): 47-54.
- Brown AW, Elovic EP, Kothari S, Flanagan SR, Kwasnica C. Congenital and acquired brain injury. Epidemiology, pathophysiology, prognostication, innovative treatments, and prevention. *Arch Phys Med Rehabil* 2008; 89(3 Suppl-1): S3-8.
- Diagnosis and treatment of head injury in adults. In: Youmans JR, ed. *Neurological Surgery*, 3rd Edn, Philadelphia: Saunders, 1990; pp 1017-148.
- Ainsworth CR, Brown GS. Head Trauma [internet]. Medscape; 2015 [Cited 2017]. Available from: <http://emedicine.medscape.com/article/433855-overview#a6>.
- De Lacey G, Barker A, Harper J, Wignall B. An assessment of the clinical effects of reporting accident and emergency radiographs. *Br J Radiol* 1980; 53(628): 304-9.
- Arienta C, Caroli M, Balbi S. Management of head-injured patients in the emergency department: a practical protocol. *Surg Neurol* 1997; 48(3): 213-9.
- Haydel MJ, Preston CA, Mills TJ, Luber S, Blaudeau E, DeBlieux PM. Indications for computed tomography in patients with minor head injury. *N Engl J Med* 2000; 343(2): 100-5.
- Murshid WR. Role of skull radiography in the initial evaluation of minor head injury: A retrospective study. *Acta Neurochir (Wien)* 1994; 129(1-2): 11-4.
- Stein SC, Young GS, Talucci RC, Greenbaum BH, Ross SE. Delayed brain injury after head trauma: Significance of coagulopathy. *Neurosurgery* 1992; 30(2): 160-5.
- Servadei F, Ciucci G, Morichetti A, Pagano F, Burzi M, Staffa G, et al. Skull fracture as a factor of increased risk in minor head injuries. Indication for a broader use of cerebral computed tomography scanning. *Surg Neurol* 1988; 30(5): 364-9.
- Zimmerman RA, Bilaniuk LT, Gennarelli T, Bruce D, Dolinskas C, Uzzell B. Cranial computed tomography in diagnosis and management of acute head trauma. *AJR Am J Roentgenol* 1978; 131(1): 27-34.
- Imtiaz AM. Trauma Radiology: Importance of computed tomography scans in acute traumatic brain injury. *Int J Pharma Sci Bus Manag* 2016; 4(4): 7-15.
- Servadei F, Faccani G, Roccella P, Seracchioli A, Godano U, Ghadirpour R, et al. Asymptomatic extradural haematomas. Results of a multicenter study of 158 cases in minor head injury. *Acta Neurochir (Wien)* 1989; 96(1-2): 39-45.
- Hidayat SK. Acute Head Trauma-CT Scanning Study. *Dohuk Med J* 2007; 1(1): 78-87.
- Lobato RD, Cordobes F, Rivas JJ, de la Fuente M, Montero A, Barcena A, et al. Outcome from severe head injury related to the type of intracranial lesion. A computerized tomography study. *J Neurosurg* 1983; 59(5): 762-74.
- Hammond N, Ranta A. The yield of head computed tomography in patients with new onset of transient headaches. *Intern Med J* 2017; 47(10): 1141-46.
- Chalela JA, Kidwell CS, Nentwich LM, Luby M, Butman JA, Demchuk AM, et al. Magnetic resonance imaging and computed tomography in emergency assessment of patients with suspected acute stroke: A prospective comparison. *Lancet* 2007; 369(9558): 293-8.
- Halley MK, Silva PD, Foley J, Rodarte A. Loss of consciousness: when to perform computed tomography? *Pediatr Crit Care Med* 2004; 5(3): 230-3.
- Maytal J, Krauss JM, Novak G. The role of brain computed tomography in evaluating children with new onset of seizures in the emergency department. *Epilepsia* 2000; 41(8): 950-4.