

COMPARISON OF DIAGNOSTIC ACCURACY OF TRANSPERINEAL SONOGRAPHY WITH THE TRANSVAGINAL ULTRASONOGRAPHY IN DETERMINING ACCURATE CERVICAL LENGTH

Arooba Usman, Mobeen Shafique, Jawad Jalil, Umar Amin*, Saerah Iffat Zafar, Khadija Qamar**

Combined Military Hospital Multan/National University of Medical Sciences (NUMS) Pakistan, *HBS Medical & Dental College Islamabad Pakistan, **Army Medical College/National University of Medical Sciences (NUMS) Rawalpindi Pakistan

ABSTRACT

Objective: To evaluate the diagnostic accuracy of transperineal ultrasonography in assessing the accurate cervical length at 24-32 weeks of gestation in comparison with the TVS as gold standard.

Study Design: Cross sectional study.

Place and Duration of Study: Department of Radiology, CMH Multan, from 12th Apr 2014 to 11th Dec 2014.

Material and Methods: A total of 157 patients of 20-35 years of age with singleton pregnancy of gestational age 24 to 32 weeks were included in the study. Patients with premature rupture of membrane, cervical incompetence, cervical injury, multiparity and h/o co-morbid conditions were excluded. Cervical length was measured first by transperineal ultrasound followed by trans-vaginal ultrasound.

Results: Of the total 157 patients assessed, 96 were true positive, 4 were false positive, 13 were false negative and 44 were true negative. Among 57 transperineal ultrasound negative patients, 13 (False Negative) had short cervical length on trans-vaginal sonography where as 44 (True Negative) had normal length. So, the sensitivity, specificity, positive predictive value, negative predictive value and accuracy of transperineal sonography in assessing accurate cervical length are 88.07%, 91.67%, 96.0%, 77.19% and 89.17% respectively.

Conclusion: This study concluded that transperineal sonography is a reliable, easily available and cost effective method with high diagnostic accuracy for assessing the cervical length at 24-32 weeks of gestation which nearly approaches the value of trans-vaginal sonography.

Keywords: Diagnostic accuracy, Short cervical length, Ultrasonography.

This is an Open Access article distributed under the terms of the Creative Commons Attribution License (<http://creativecommons.org/licenses/by/4.0>), which permits unrestricted use, distribution, and reproduction in any medium, provided the original work is properly cited.

INTRODUCTION

Labor that begins between 20 and 37 weeks gestation is appropriately termed preterm. Some of the precipitating factors of preterm labor are changes in cervical status including dilatation and effacement¹. Until recently, a digital pelvic examination was considered as gold standard for evaluating cervical changes². Ultrasonography of the cervix in pregnancy has been subject to a rapid development, since its introduction in the nineteen eighties. Initially, trans-abdominal ultrasound was performed to diagnose cervical incompetence. In last three decades, intensive research has been done to investigate the behavior of the cervix and the ability to predict

preterm labor by cervical measurements³.

Cervical sonography is a common practice in obstetric management nowadays. Studies have shown that early detection of a shortened cervix on sonography can predict preterm birth^{4,5}. The shorter the cervix, greater the risk for preterm delivery (10-18). Patients with a cervical length <15mm have an approximate 50% likelihood of preterm delivery <32 weeks, regardless of risk factors⁶. Various methods of cervical imaging include transabdominal, translabial / transperineal, and transvaginal approaches⁷. Transvaginal sonography is the gold standard for assessing the cervical length during pregnancy. Transabdominal and transperineal sonography may also provide an effective means of assessing the cervix, enabling a noninvasive method of detecting individuals at risk for preterm delivery⁸. Transperineal/transvaginal approaches are the

Correspondence: Dr Mobeen Shafique, House # 12, Street # 61, Sector G-9/4 Islamabad Pakistan

Email: mobeen_shafique@hotmail.com

Received: 16 Jan 2019; revised received: 24 Jan 2019; accepted: 25 Jan 2019

most accurate for assessing the cervix, although bladder distension and myometrial contractions may give a false normal cervical appearance. Since image resolution is better transvaginally, transperineal US should be reserved for and offered to women at risk of preterm birth for whom vaginal assessment unacceptably invasive or uncomfortable.

Transperineal ultrasonography is completely replaced by the transvaginal sonography in many developing countries as it is easily available in main cities as well as in periphery, an inexpensive modality and more accessible for general population as compared to transvaginal ultrasonography. While in Pakistan, this modality is still in testing phase and is not being used commonly in our hospitals although it can be done at any hospital because it does not require a special probe as for transvaginal sonography. We set out to do this study as no data on local population exists to evaluate the diagnostic accuracy of transperineal sonography in assessing the accurate cervical length at 24-32 weeks of gestation.

MATERIAL AND METHODS

This descriptive, cross sectional study was done on 157 primigravida with singleton pregnancy on transabdominal ultrasonography and gestational age between 24 to 32 weeks assessed on the basis of LMP, who presented in Obstetrics & Gynecology department of CMH, Multan and referred by gynecologist to the radiology department for ultrasonography were selected for the study. Patients with multiple pregnancies, h/o cervical surgery, cervical incompetency, preterm premature rupture of membrane, already undergone cervical encirclage and having any medical condition i.e. diabetes mellitus, hypertension were excluded from the study.

After taking permission from the hospital ethical review committee, 157 primigravida (fulfilling the inclusion criteria) were selected for the study. After taking an informed consent and relevant history, study was conducted using 7 MHz conventional curvilinear transducer for

transperineal US and 7 MHz TVS transducer for transvaginal US. Both kind of probes were covered with latex probe sheath before each examination and used with sterile gel to avoid the risk of infection transmission between selected subjects. Transperineal ultrasonography was performed first with post void patient lying supine on an examination couch with the knees and hips in a flexed position and placing the gloved curvilinear transducer on the perineum between the labia majora ensuring to keep the transducer in a sagittal orientation along the direction of vagina. Oblique or parasagittal movements of probe were performed to delineate the full length of cervical canal. A pillow was placed underneath the patient to elevate the hips and enhance visualization of the cervix as well as to alleviate rectal gas overlying the external os. Immediately after, transvaginal ultrasonography was done with 7 MHz TVS probe in every patient with urinary bladder completely empty. Patient was scanned while lying supine on an examination couch with the knees and hips slightly abducted in a flexed position. Cervix was imaged in the sagittal plane. Cervical lengths were measured with both transperineal and transvaginal approaches. On ultrasonography, measurements of cervical length began at the internal os, followed the path along the endocervical canal and ended at the external os and was considered short if $CL < 25\text{mm}$, otherwise normal if $CL > 25\text{mm}$. For measuring the minimally curved cervical canal, a straight line measurement was used. In cases of more pronounced cervical curves (with a deviation of $>5\text{mm}$ from the straight line), CL was measured with the sum of two straight lines. The collected data was analyzed accordingly using SPSS version 16. Mean and standard deviation was calculated for quantitative variables. Frequency and percentage was calculated for qualitative variables. 2x2 contingency table was used to calculate sensitivity, specificity, positive predictive value, negative predictive value and diagnostic accuracy of transperineal US in accurate

assessment of cervical length taking transvaginal US as gold standard.

RESULTS

Age range in this study was from 20 to 35 years with mean age of 27.76 ± 5.19 years. Sixty One patients (38.85%) were between 20 to 25 years of age. Mean gestational age was 28.69 ± 1.82 weeks. Mean cervical length was 34.43 ± 7.60

shown in table. So, the sensitivity, specificity, positive predictive value, negative predictive value and accuracy of transperineal sonography in assessing accurate cervical length are 88.07%, 91.67%, 96.0%, 77.19% and 89.17% respectively .

DISCUSSION

Transvaginal sonography is the reference standard for assessing the cervix; Transabdo-

Table: Summary of results.

	Positive result on Transperineal Ultrasonography	Negative result on Transperineal Ultrasonography	p-value
Positive result on transvaginal Ultrasonography	96 (TP)*	13 (FN)***	0.282
Negative result on transvaginal Ultrasonography	04 (FP)**	44 (TN)****	

*-TP=True positive **-FP=False positive ***-FN=False negative ****-TN=True negative

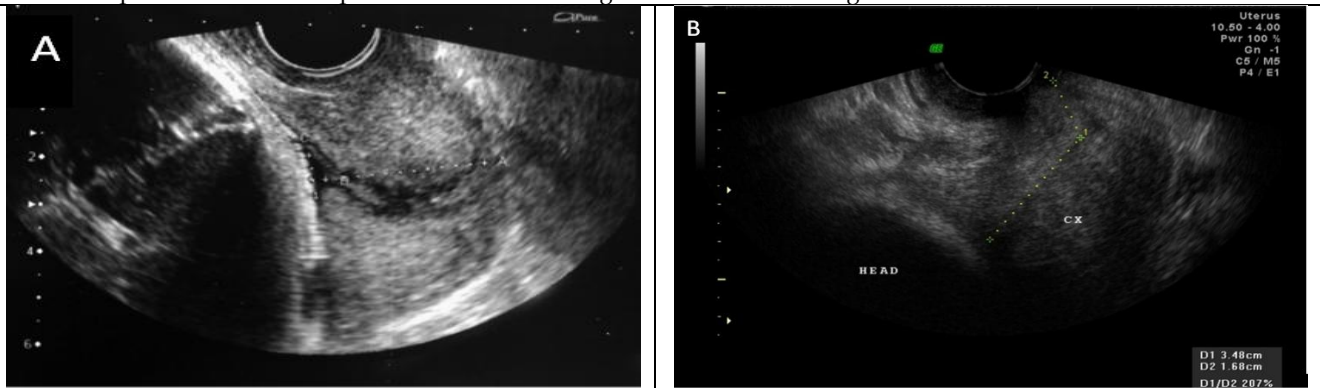


Figure-1: Transvaginal CL measurement in a curved cervix of two different patients. The cervix can be measured in a straight line (A) in curved (B).

mm. All the patients were subjected first to transperineal and then transvaginal US. Transperineal ultrasonography supported the diagnosis of short cervical length in 63.49% (n=100) patients. Transvaginal ultrasonography has shown short cervical length in 69.43% (n=109) cases where as 30.57% (n=48) patients revealed normal cervical length. In transperineal ultrasound positive patients, 96 (True Positive) had short cervical length and 04 (False Positive) had normal cervical length on trans-vaginal sonography. Among, 57 transperineal ultrasound negative patients, 13 (False Negative) had short cervical length on transvaginal sonography where as 44 (True Negative) had normal length as

minial sonography may also provide an effective means of assessing the cervix, enabling a non invasive method of detecting individuals at risk for preterm delivery. Translabial (also known as transperineal) ultrasound was originally used in France in the 1980s and proved to be more fruitful than the transabdominal approach. Initially, transperineal scanning of the cervix appeared to be a feasible alternative when compared with transabdominal ultrasound⁹. Particularly when transabdominal imaging of the cervix is difficult in the third trimester of pregnancy, the cervix can be well visualized by the transperineal method and proved to be an inexpensive, easily available, more comfortable

and acceptable alternative modality of transvaginal sonography¹⁰.

In a study done by Meijer-Hoogeveen *et al*¹¹, it was found that transperineal sonography in assessing the short cervical length (<25 mm) has sensitivity of 71%, specificity of 94%, positive predictive value of 63% and negative predictive value of 96%.

In our study, all the patients were subjected first to transperineal and then transvaginal

approach is only a reliable substitute for the transvaginal method in centers with extensive experience, which is in agreement with the conclusion made by Facco *et al*¹⁰. In the latter study, patients tolerated transperineal ultrasound of the cervix better than they did transvaginal ultrasound.

The reliability of transperineal cervical length measurements has been investigated mainly in very preterm pregnancies^{3,5,10,13},

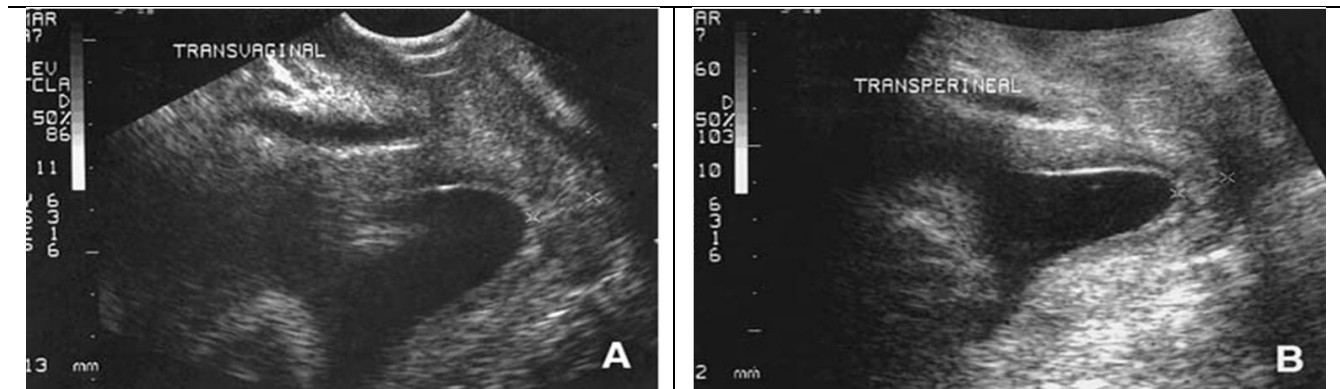


Figure-2: In majority of patients the cervix can be visualized adequately by transperineal USG (Image B) and measurements of cervical length (17mm) obtained by this approach are very similar to those obtained by transvaginal USG (16mm) (Image A).

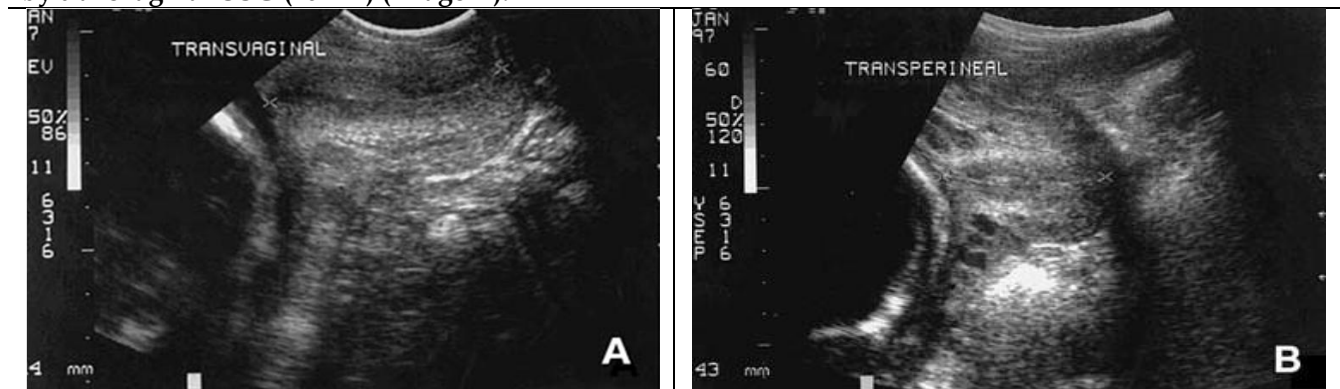


Figure-3: Cervical length measured by transperineal US demonstrates close correlation and agreement with transvaginal measurement in a 28 weeks pregnant female. Transvaginal CL of 55mm (Image A) closely correlates with transperineal CL of 53mm (Image B).

ultrasonography. The transperineal approach has been reported to correlate reasonably well with transvaginal measurement of the cervix, with correlation coefficients ranging from 0.77 to 0.97. Owen *et al*¹² reported a deviant correlation coefficient of 0.38 and a difference between the two methods of 20% or more in one third of the cases. They concluded, that the transperineal

although two studies included gestational ages of 30-34 weeks³, and one study also included term gestations but did not distinguish between these and preterm ones¹⁴. Gauthier *et al*¹⁵ in his study concluded that in case of preterm labor, cervical length measurement with transperineal ultrasonography seems reproducible and can be performed by the obstetric team on duty. He has

found that concordance was good between transperineal and transvaginal sonography with an intraclass correlation coefficient of 0.83 (IC 95% = (0.73–0.90)). Transperineal ultrasonography has been found to be as accurate as transvaginal ultrasound for examining the cervix, and one study found it more acceptable to women than trans-vaginal scanning¹⁶. Transperineal assessment is more accurate than digital examination for predicting preterm birth, and, when adequate images can be obtained, transperineal ultrasonography can predict preterm birth as accurately as trans-vaginal ultrasonography¹⁷.

Although, transvaginal ultrasonography is the best technique for assessing cervical length changes during pregnancy; However, it has a few limitations i.e. it is not easily available in main cities and periphery in our country, requires special probe and is expensive, and more difficult to access for general population as compared to transperineal ultrasonography which can be performed with a curvilinear probe. Transperineal ultrasonography has effectively replaced the transvaginal sonography in many countries due to its high diagnostic accuracy and being an inexpensive modality and more accessible for general population¹⁸. The downfalls to transperineal US are that most women find this method uncomfortable and embarrassing, this newly emerging technique of imaging is more challenging to master than other ultrasonographic methods and sometimes gas in the rectum may impede the view of external os.

CONCLUSION

This study concluded that transperineal sonography is a reliable, easily available and cost effective method with high diagnostic accuracy for assessing the cervical length at 24-32 weeks of gestation which nearly approaches the value of trans-vaginal sonography. Moreover, transperineal ultrasonography is also more comfortable and acceptable modality than transvaginal sonography for general population. So, we recommend that transperineal sonography

should be used as primary modality / screening tool for assessing cervical length in patients with high risk for preterm labor and thus proper managements could be taken in these patients in order to reduce the perinatal mortality and morbidity of both mother and fetus.

CONFLICT OF INTEREST

This study has no conflict of interest to be declared by any author.

REFERENCES

1. Awad EA, Dayem TA, Agwany AS. Comparison between different methods of sonographic cervical length assessment during pregnancy. *Int J Reprod Contracept Obstet Gynecol* 2016; 5(5): 1348-53.
2. Kurtzman JT, Goldsmith LJ, Gall SA, Spinnato JA. Transvaginal versus transperineal ultrasonography: A blinded comparison in the assessment of cervical length at midgestation. *Am J Obstet Gynecol* 2012; 179(4): 852-7.
3. Roh HJ, Ji Y, Jung CH, Jeon GH, Chun S, Cho HJ. Comparison of cervical lengths using transabdominal and transvaginal sonography in mid pregnancy. *J Ultrasound Med* 2013; 32(10): 1721-8.
4. Crane JM, Hutchens D. Transvaginal ultrasonographic measurement of cervical length in asymptomatic high-risk women with a short cervical length in the previous pregnancy. *Ultrasound Obstet Gynecol* 2011; 38(1): 38-43.
5. Owen J, Szychowski JM, Hankins G, Iams JD, Sheffield JS, Perez-Delboy A, et al. Does midtrimester cervical length ≥ 25 mm predict preterm birth in high-risk women? *Am J Obstet Gynecol* 2010; 203(4): 393-5.
6. Vaisbuch E, Romero R, Erez O, Kusanovic JP, Mazaki-Tovi S, Gotsch F, et al. Clinical significance of early (<20 weeks) vs. late (20–24 weeks) detection of sonographic short cervix in asymptomatic women in the mid-trimester. *Ultrasound Obstet Gynecol* 2010; 36(4): 471-81.
7. Moroz LA, Simhan HN. Rate of sonographic cervical shortening and the risk of spontaneous preterm birth. *Am J Obstet Gynecol* 2012; 206(3): e1-e5.
8. Conde-Agudelo A, Romero R, Nicolaidis K, Chaiworapongsa T, O'Brien JM, Cetingoz E, et al. Vaginal progesterone vs cervical cerclage for the prevention of preterm birth in women with a sonographic short cervix, previous preterm birth, and singleton gestation: A systematic review and indirect comparison meta-analysis. *Am J Obstet Gynecol* 2013; 208(1): e1-e18.
9. Di-Tommaso M, Berghella V. Cervical length for the prediction and prevention of preterm birth. *Expert Rev Obstet Gynecol* 2013; 8(4): 345-55.
10. Facco FL, Simhan HN. Short ultrasonographic cervical length in women with low risk obstetric history. *Obstet Gynecol* 2013; 122(4): 858-62.
11. Meijer-Hoogeveen M, Stoutenbeek P, Visser GHA. Transperineal versus transvaginal sonographic cervical length measurement in second and third trimester pregnancies. *Ultrasound Obstet Gynecol* 2008; 32(5): 657-62.
12. Owen J, Neely C, Northen U. Transperineal versus endovaginal ultrasonographic examination of the cervix in the midtrimester: A blinded comparison. *Am J Obstet Gynecol* 1999; 181(4): 780-3.

13. O'Hara S, Zelesco M, Sun Z. Cervical length for predicting preterm birth and a comparison of ultrasonic measurement techniques. *Australas J Ultrasound Med* 2013; 16(3): 124-34.
 14. Carr DB, Smith K, Parsons L, Chansky K, Shields LE. Ultrasonography for cervical length measurement: Agreement between transvaginal and translabial techniques. *Obstet Gynecol* 2000; 96(4): 554-8.
 15. Gauthier T, Marin B, Garuchet-Bigot A, Kanoun D, Catalan C, Caly H, et al. Transperineal versus transvaginal ultrasound cervical length measurement and preterm labor. *Archiv Gynecol Obstet* 2014; 290(3): 465-9.
 16. Raungrongmorakot K, Tanmoun N, Ruangvutilert P, Boriboonhirunsarn D, Tontisirin P, Butsansee W. Correlation of uterine cervical length measurement from transabdominal, transperineal and transvaginal ultrasonography. *J Med Assoc Thai* 2004; 87: 326-32.
 17. Yazici G, Yildiz A, Tiras MB, Arslan M, Kanik A, Oz U. Comparison of transperineal and transvaginalsonography in predicting preterm delivery. *J Clin Ultrasound* 2004; 32(5): 225-30.
 18. Benardis P, Daskalakis G. Screening for preterm labor. *Donald School J Ultra Obstet Gynecol* 2008; 2(1): 37-47.
-