

ARSENIC INDUCED HISTOMORPHOLOGICAL ALTERATIONS IN SIZE OF HEPATIC LOBULE AND AMELIORATIVE EFFECTS OF LAGENARIA SICERARIA

Saima Qureshi, Umbreen Noor*, Ayesha Baqar**, Khadija Qamar

Army Medical College/National University of Medical Sciences (NUMS) Rawalpindi Pakistan, *Riyadh Elm University, Riyadh KSA,

**Watim Dental College & Hospital Islamabad Pakistan

ABSTRACT

Objective: To study the effects of *Lagenaria siceraria* and arsenic on size of Hepatic lobule of Sprague Dawley rat.

Study Design: Laboratory-based randomized controlled trial.

Place and Duration of Study: Army Medical College, Rawalpindi, and National Institute of Health (NIH), Islamabad, for eight weeks, from 20th Mar 2017 to 14th May 2017.

Material and Methods: Fifty Sprague Dawley rats both male and female selected randomly and broadly allocated into five groups, each with 10 animals. Groups A and B animals were controls, C, D and E served as experimental groups. Sodium arsenite 5mg/kg body weight was initially given for a period of 4 weeks to the experimental groups C, D and E. After 4 weeks of therapy, the animals of groups A and C were sacrificed for histopathological study of liver to see the immediate effects of arsenic. Within the next 4 weeks group D animals were retained without any intervention. Group E animals were administered sodium arsenite (5mg/kg body weight) along with *Lagenaria siceraria* at a dose of 100mg/kg bodyweight. Group B served as a control for experimental group D and E. Animals of group B, D and E were sacrificed after last dose at the end these 4 weeks. Liver was removed and prepared for histological study. Size of hepatic lobule was studied. Data were analysed by SPSS V 22. A *p*-value ≤ 0.05 was considered statistically significant.

Results: Moderate increase in the size of hepatic lobule was seen in group C as compared to control group A. Group D showed slight increase in size of hepatic lobule and group E showed normal size of hepatic lobule when compared with control group B.

Conclusion: Sodium arsenite caused used disruption of hepatic architecture and increase in size of hepatic lobule of adult rats but administration of *Lagenaria siceraria* protected and reduced the arsenic-induced effects.

Keywords: *Lagenaria siceraria*, Sodium arsenite, Sprague dawley.

This is an Open Access article distributed under the terms of the Creative Commons Attribution License (<http://creativecommons.org/licenses/by/4.0>), which permits unrestricted use, distribution, and reproduction in any medium, provided the original work is properly cited.

INTRODUCTION

Contact with high concentration of inert arsenic is a key health issue in various parts of the world and lays risk on millions of people in developing countries and a lot of complications in various body systems¹. Water used for drinking and agricultural purposes mainly comes from ground, is the main source of arsenic contact. After ingestion, arsenic is deposited in the liver, spleen, kidneys, lungs and gastrointestinal tract². Arsenic is a deadly organic substance which is notorious in causing cancer, and when taken in large amounts it can be lethal³. Arsenic is added purposely in chicken feed. Wide

range of chicken is fed on arsenic to enhance the bodily growth on minimum food intake and in less time period, and chicken meat gives off a vibrant and fresh look. In view of food drug administration (FDA) findings, fifty percent of screened chicken had inert arsenic in their liver. Roxarsone, a preparation which comprises of lethal arsenic is mixed to chicken feed so that the meat gives a healthier look⁴. Uptake of solvable arsenic combinations is good through the gastrointestinal and respiratory tracts. Almost all of the absorbed inert arsenic undertakes methylation, chiefly in the liver, to monomethylarsonic acid and dimethylarsinic acid, which are expelled, along with remaining inert arsenic, in the urine⁵. Arsenic renders its toxic effects by interacting with sulfhydryl groups present in enzymes and interrupt enzymes

Correspondence: Dr Khadija Qamar, HOD Anatomy Dept, Army Medical College Rawalpindi Pakistan

Email: colkhadijaqamar@gmail.com

Received: 23 May 2018; revised received: 06 Jul 2018; accepted: 10 Jul 2018

concerning cellular respiration, which in turn is responsible for blocking glycolysis and Krebs cycle and replace phosphorus in a couple of biological processes⁶. Greater amount of arsenic in human body is accountable for higher levels of free radicals. These free radicals may lead to oxidative stress, hinders enzyme and mitochondrial activity⁷. The liver and kidney are the prime aims for toxic effects of arsenic and the

World health organization (WHO) survey reveals that majority of the residents of under developed world depend solely on old fashioned prescriptions for their vigor and vitality¹⁰. Besides these the herbs have some very essential lifesaving components used in the techniques of modern medicine. World over it is believed that traditional measures are harmless and less destructive anthropologically than man made

Table-I: Grouping of experimental study (Both male and Female Rats divided arbitrarily in following groups housed in separate cages).

Groups	Number of animals	Title of group	Duration of intervention	Intervention
A	10	Control	First 4 weeks	Laboratory Diet and water <i>ad libitum</i>
B	10	Control	8 weeks	Laboratory Diet and water <i>ad libitum</i>
C	10	Experimental	First 4 weeks and sacrificed	Sodium arsenite 5 mg /kg/day by oral gavage (Fouad <i>et al.</i> , 2012)
D	10	Experimental	8 weeks and sacrificed	Left as such after 4 weeks of sodium arsenite till the end of the experiment (8 weeks) without any further intervention
E	10	Experimental	8 weeks and sacrificed (initial 4 weeks only sodium arsenite and last four weeks sodium arsenite and lagenaria siceraria simultaneously)	Sodium arsenite 5 mg /kg/day by oral gavage (Fouad <i>et al.</i> , 2012) Lagenaria siceraria 100mg / kg body wt. by oral gavage (Deshpande <i>et al.</i> , 2008)

Table-II: Mean values of hepatic lobule diameter of control Group A and experimental group C (Independent t-test).

Parameter	Group A	Group C	p-value
Diameter of hepatic lobule (μm)	1376.3 \pm 2.05	1704 \pm 2.93	<0.001*
Independent Sample T-Test			
Groups	N	Mean	Standard Deviation
A	10	1376.30	2.05
C	10	1705.00	3.16
Sig	0.000	0.000	0.000

peak level of arsenic is more so in the liver compared to the kidney⁸.

Diversified therapeutic setups acquire the use of herbal therapies for the management and controlling of various ailments. Lagenaria siceraria has been of use in folklore prescriptions for the cure of many disorders in humans⁹. Excessive material, knowledge and benefits of herbal drugs is present in state of the art literature of Ayurvedic and Unani medicine.

preparations. Due to this test centers across the globe are working on plants for their organic makeup and therapeutic prospective¹¹. The outmoded remedial system states herbal preparations to be good for the cure of quite a range of diseases. The ayurveda has given a lot of importance to food in the treatment of diseases¹².

Contemporary practitioners have even understood the worth of food stuffs, in having nutraceutical features, for the management of

long standing illnesses. *Lagenaria siceraria* is known as Bottle gourd, an exceptional vegetable possessing all the vital elements that are obligatory for steady and virtuous well-being of human beings¹³. *Lagenaria siceraria* is conventionally utilized for its cardioprotective, cardiostimulant, all purpose tonic properties and is also used as purgative and diuretic⁹. Protective effect on liver was studied by investigating the impact of the ethanolic extract of *Lagenaria siceraria* extracts against CCl₄ hepatotoxicity^{9,14}.

inflammatory, antioxidant and hepatoprotective capabilities¹⁷.

MATERIAL AND METHODS

This randomised control trial study was approved by Ethical Committee, of the Army Medical College, Rawalpindi, to be conducted in the Department of Anatomy with National Institute of Health (NIH), Islamabad (20th March, 2017 to 14th May, 2017). Sodium arsenite was purchased from Sigma Aldrich (Product

Table-III: Mean values of hepatic lobule diameter of control Group B and experimental group C, D and E (One way ANOVA followed by Post Hoc Tukey’s test).

Parameter	Group B	Group D	Group E	p-value	
Diameter of hepatic lobule (µm)	1379.2 ± 2.82	1672 ± 1.39	1356.1 ± 1.97	<0.001*	
Post Hoc Tukey’s Results					
Groups	N	Subsets			
		1	2	3	4
E	10	1356.1			
B	10		1379.2		
D	10			1673.2	
C	10				1705.0
Sig	1.000	1.000	1.000	1.000	1.000

N: Sample size, p-value ≤ 0.05 is statistically significant, * = highly significant

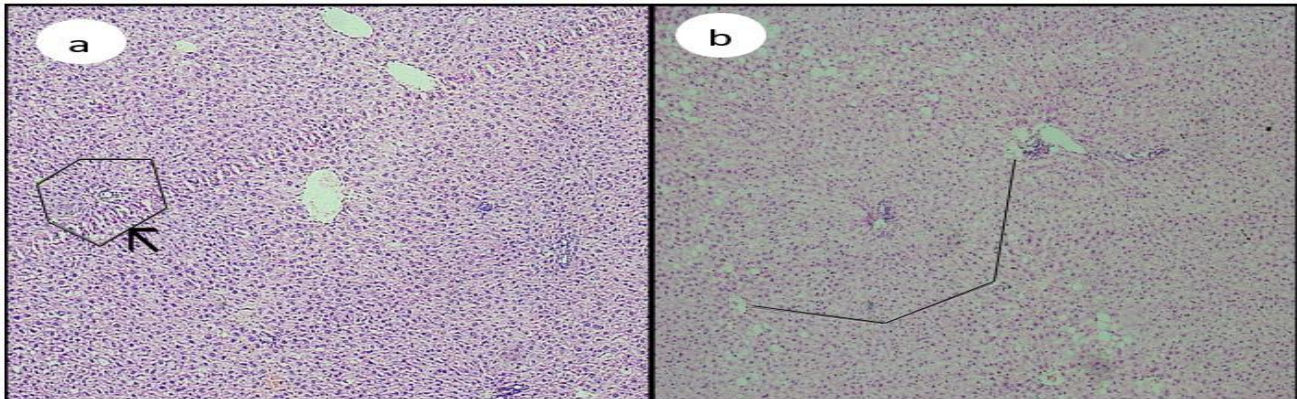


Figure-1: Histological section of hepatic lobule showing.

Normal architecture and hepatic lobular diameter with H & E stain (black Arrow), Disrupted hepatic lobule with increased hepatic lobular diameter with H & E stain (Black Arrow)

Medicinal plants are believed to have immunomodulatory capacity of boosting the immune system of the host¹⁵. This allows the host to fight back against different attacking antigens¹⁶. Recent, investigations have led the researchers to understand the role of this fruit in human health as it is able to provide a range of functions including anthelmintic, antibacterial, antifungal, immunomodulatory, antiallergic, analgesic, anti-

no.133027-500G). *Lagenaria siceraria* was purchased from local market, it was shade dried and ground to powder form then the calculated dose was given to the animals by mixing it with saline via oral gavage needle. Fifty adult male and female Sprague Dawley rats, 9-11 weeks of age and weighing 250-380gm were taken for this randomised control trial study which were divided by using probability sampling technique

into five groups (control & experimental), each having 10 animals (male and females caged separately) by lottery method. They were kept in a well-ventilated room, with temperature range of 20-26°C and 12h dark-light sleep cycle throughout the duration of experiment¹⁸. Rats were fed with standard laboratory diet provided by NIH. Water was provided ad libitum. Study plan and dosage is given in table-I.

intervention for another four weeks. Group E animals during this period of 4 weeks were given sodium arsenite 5mg/kg/day and Lagenaria siceraria 100mg/kg/day (powder obtained after grinding the shade dried fruit mixed with calculated dose of normal saline)²⁰. At the end of these 4 weeks, the animals of groups B, D and E were sacrificed, liver specimens were collected. Haematoxylin and eosin (H&E) stained sections

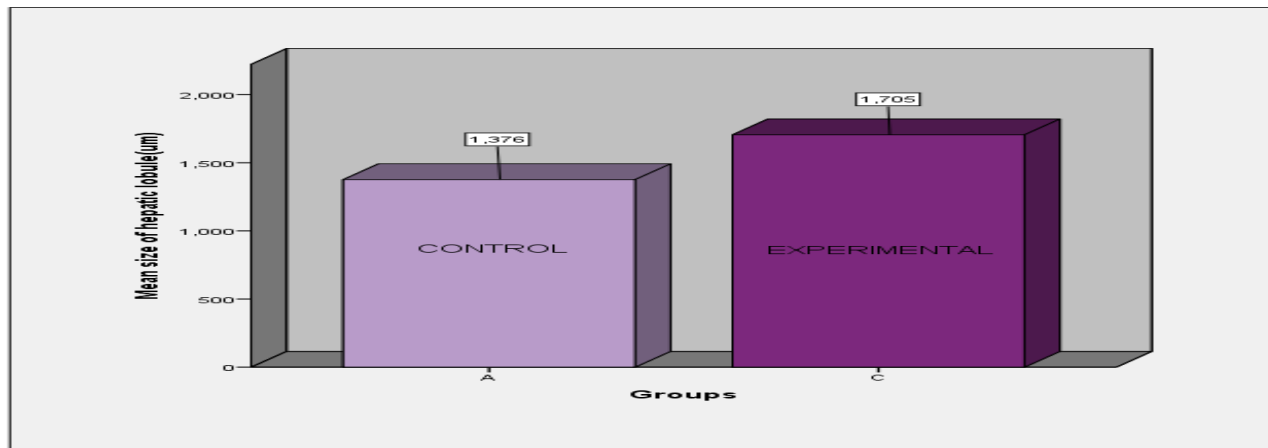


Figure-2: Bar chart showing intergroup comparison of diameter among control group A and experimental group C (Independent sample t-test).

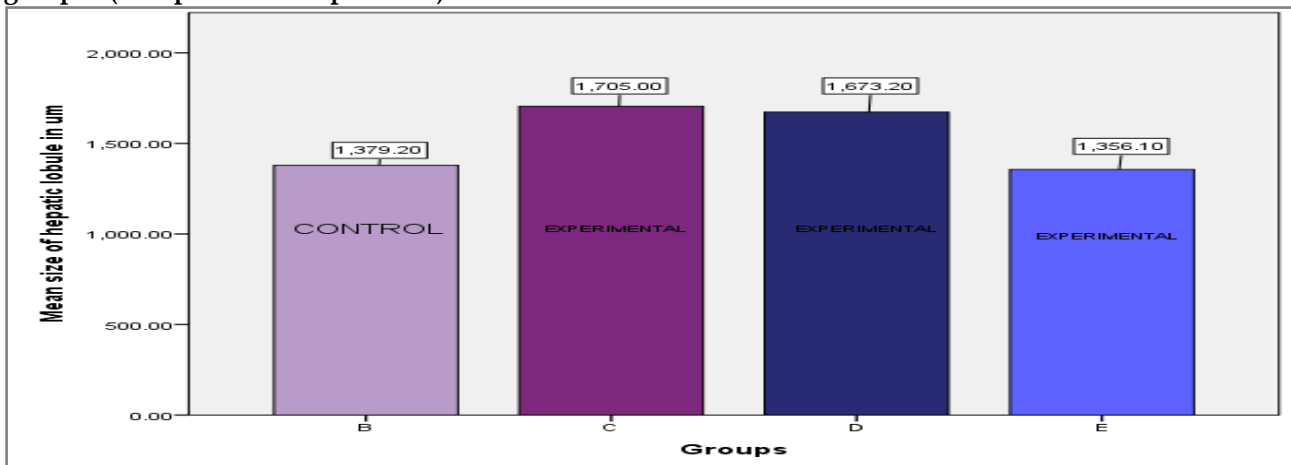


Figure-3: Cluster bar chart showing intergroup comparison of diameter among control group B and experimental groups C, D and E (One way A-Nova followed by Post Hoc Tuckey test).

Rats in groups A and B were untreated controls. Group C, D and E were given sodium arsenite 5mg/kg/day initially for a period of 4 weeks¹⁹. Animals of group A and C were sacrificed after 4 weeks and histopathological studies on liver were carried out. Within the next 4 weeks group D animals were kept without any

of liver were prepared for routine histological study. Each specimen was evaluated for size of hepatic lobule. Hepatic lobular diameter was measured under low power in ten low-power fields (10X). In each field, three lobules were selected randomly from periphery to the center of slide. Images were taken from each field with the

help of Olympus digital camera (12-mega pixel). The images were then transferred to the laptop. Each image was opened in Image J v1.48²¹. A scale was set at 10X to measure the diameter in micrometre. Measurement tool 'Straight' was selected and the diameter to be measured was calculated by drawing a straight line. The measurements were then analysed and recorded. Results were expressed as mean for each specimen in micrometres and taken as the final reading for that specimen. Data was analysed using statistical package for social sciences version 22. Variables were expressed as mean \pm standard deviation and the significant difference was determined using one-way analysis of variance (ANOVA) followed by post Hoc Tukey's test for groups B, C, D and E. Independent sample t-test was used to find the statistical significance between the groups A and C. A p -value ≤ 0.05 was considered significant. Mean \pm standard deviation and p -value is given in table-II & III.

RESULTS

Fifty adult male and female Sprague Dawley rats, 9-11 weeks of age, with an average weight of 284 ± 2.58 gm were used in the experiment. Histologically, control groups A and B showed normal hepatic architecture with chains of hepatocytes around the central vein. The radiating cords were limited by connective tissue forming hepatic lobule 22 (fig-1a). In control group A and B, the mean diameter with SD of hepatic lobule was 1376.3 ± 2.05 μ m and 1379 ± 2.82 μ m. Group C showed moderate degree of disruption in hepatic architecture, characterized by the destruction of a number of liver cells and fatty change in the hepatic parenchyma leading to increase in hepatic lobular diameter²³ (fig-1b). Group D had mild disruption of hepatic architecture much less as compared to group C. None of group E specimens showed disruption of the architecture. The mean diameter and SD of experimental group C increased significantly to 1704 ± 2.93 μ m. In experimental group D, the diameter was 1672 ± 1.39 μ m. In experimental group

E, the mean diameter and SD was measured to be 1356.1 ± 1.97 μ m. While comparing the size of hepatic lobule the maximum increase was seen in group C which reduced in group D and reverted back to nearly normal size in group E specimens. Bar charts were also plotted for the values of mean hepatic lobular diameter between group A and C, groups B, C, D and E (fig-2 & 3). On inter-group comparison of control groups, A and B with the experimental groups C, D and E, the results were statistically highly significant (p -value < 0.001).

DISCUSSION

Exposure to sodium arsenite through various routes has adverse effects on various tissues and organs, leading to morbidity²⁴. Accordingly, this study was designed to investigate the effect of sodium arsenite on the liver of adult rats and whether subsequent administration of *Lagenaria siceraria* can alter the effects. In present study, acute exposure to mild doses of sodium arsenite altered the liver architecture with fatty change in the lobules affecting their size. In control group A and B the architecture was normal with no fatty change and disruption of architecture and the size of lobule was in the normal limits. Group C showed severe degrees of disruption of architecture culminating in increase in dimensions of hepatic lobule²⁵. Group D showed mild increase in size of hepatic lobule. Group E showed a picture like that of the control group A & B. Histological changes were highly significant when inter group comparison was done between A, B, C, D and E. These results were also studied on bar graphs showing comparison of size of hepatic lobule in group A and C (fig-2), and between B, C, D and E (fig-3). These results were in accordance with the previous works^{26,27}. Oxidative stress, apoptosis, and upregulation of transcription factors such as AP-1, ATF-2, and Elk-1 are the prospective target sites for arsenite-induced nephrotoxicity and hepatotoxicity. *Lagenaria siceraria* when chemically studied, it was found to be composed of flavonoids. Flavonoid containing plants have influence on arachidonic acid metabolism and are supposed to

have anti-inflammatory, cardio protective and anti-allergic effect. Heavy metals can lead to oxidative stress and lead to hepatotoxicity. *Lagenaria siceraria* has marked oxidative potential and able to revert this oxidative stress and is able to reduce the fatty infiltration in the interstitium and periportal areas. In the current study also when *lagenaria siceraria* was given to the animals after exposure to heavy metal toxicity the disruption of lobules of liver and the increase in their size was reduced (table-II & III). Bar charts were also plotted to study the intergroup comparison. Mechanism behind the hepatic toxicity is that most absorbable component eventually go to the liver for breakdown. This puts up the liver to severe deadliness²⁸. Enzymes like aspartate aminotransferase and alanine aminotransferase are found chiefly in liver tissue and cellular injury as a result of arsenic exposure releases these enzymes into the blood stream and the plasma levels of these enzymes specify hepatotoxicity²⁹. Epidemiological studies have obviously showed an association between chronic arsenic exposure and abnormal liver function, hepatomegaly, hepatoportal sclerosis, ascites, liver fibrosis and cirrhosis from exposure to arsenic in the drinking water.

CONCLUSION

Our study suggests that sodium arsenite caused disruption of hepatic architecture with fatty change leading to increase in size of hepatic lobule in adult rats while collateral intervention with *Lagenaria siceraria* had protective effect on the hepatic architecture and subsequently on the size of hepatic lobule.

ACKNOWLEDGEMENT

We are grateful to our colleagues for their persistent sustenance and all the people in Anatomy Department, Army Medical College, Rawalpindi for their valuable input.

Author's Contribution

Saima Qureshi conceived the idea, created the manuscript, Umbreen Noor and Ayesha Baqar analysed the data. Dr Khadija Qamar did the critical analysis and revised the manuscript.

CONFLICT OF INTEREST

The authors of this study reported no conflict of interest among their idea.

REFERENCES

1. Das R, Das A, Roy A, Kumari U, Bhattacharya S, Halder PK. β -Carotene ameliorates arsenic-induced toxicity in albino mice. *Biol Trace Elem Res* 2015; 164(2): 226-33.
2. Mehta M, Hundal S. Biochemical and histological alterations in liver following sub chronic exposure of arsenic. *Al Ameen J Med Sci* 2015; 8(3): 219-24.
3. Kazi TG, Shah AQ, Afridi HI, Shah NA, Arain MB. Hazardous impact of organic arsenical compounds in chicken feed on different tissues of broiler chicken and manure. *Ecotoxicology and environmental safety* 2013; 87: 120-3.
4. Garbarino J, Bednar A, Rutherford D, Beyer R, Wershaw R. Environmental fate of roxarsone in poultry litter. I. Degradation of roxarsone during composting. *Environ Sci Technol* 2003; 37(8): 1509-14.
5. Katzung BG, Masters SB, Trevor AJ. *Basic & clinical pharmacology*. 12 ed: McGraw-Hill Medical 2016: 1017-9.
6. Gora RH, Baxla SL, Kerketta P, Patnaik S, Roy BK. Hepatoprotective activity of *Tephrosia purpurea* against arsenic induced toxicity in rats. *Indian J Pharmacol* 2014; 46(2): 197.
7. Sharma V, Chaudhary U. Antihepatotoxic efficacy of *Achyranthes aspera* roots on sodium arsenate induced hepatic damages in Swiss albino mice. *World J Pharm Pharm Sci* 2016; 5: 1360-74.
8. Flora SJ, Mehta A, Gupta R. Prevention of arsenic-induced hepatic apoptosis by concomitant administration of garlic extracts in mice. *Chem Biol Interact* 2009; 177(3): 227-33.
9. Kubde MS, Khadabadi S, Farooqui I, Deore S. *Lagenaria siceraria*: Phytochemistry, pharmacognosy and pharmacological studies. *Rep Opin* 2010; 2(3): 91-8.
10. Hossain MS, Urbi Z, Evamoni FZ, Zohora FT, Rahman KH. A Secondary Research on Medicinal Plants Mentioned in the Holy Qur'an. *J Med Plant Res* 2016; 3(59): 81-97.
11. Funde SK, Jaju JB, Dharmadhikari SC, Pawar GR. Effect of *Lagenaria siceraria* fruit extract (Bottle gourd) on hepatotoxicity induced by antitubercular drugs in albino rats. *Int J Basic Clin Pharmacol* 2017; 2(6): 728-34.
12. Tirumalasetti J, Patel M, Shaikh U, Pokala N, Harini K. Protective Effect of Aqueous Extract of *Lagenaria Siceraria* (Molina) Against Maximal Electroshock (MES)-Induced Convulsions in Albino Rats. *Kathmandu Univ Med J* 2017; 58(2): 117-20.
13. Barot A, Pinto S, Balakrishnan S, Prajapati J. Composition, functional properties and application of bottle gourd in food products. *Research & Reviews: J Dairy Sci* 2018; 4(1): 15-27.
14. Upaganlawar A. *Lagenaria siceraria* (Bottle Gourd) in various cardiovascular complications. *Cardiovascular Diseases* 2017; 1: 44.
15. Saha P, Mazumder U, Halder P, Gupta M, Sen SK, Islam A. Antioxidant and hepatoprotective activity of *Lagenaria siceraria* aerial parts. *Phcog J* 2011; 3(23): 67-74.
16. Govind P. Medicinal plants against liver diseases. *IJPR* 2011; 2: 115-21.
17. Singh M, Mohd F, Ayaz A, Ankur S, Jyoti Y. Protective effect of *lagenaria siceraria* against doxorubicin induced cardiotoxicity in wistar rats. *Int J Drug Dev Res* 2012; 4(2): 298-5.
18. Hessler J, Lehner N. *Planning and designing research animal facilities*: Academic Press; 2011.

19. Fouad AA, Al-Mulhim AS, Jresat I. Telmisartan treatment attenuates arsenic-induced hepatotoxicity in mice. *Toxicology* 2012; 300(3): 149-57.
 20. Deshpande J, Choudhari A, Mishra M, Meghre V, Dorle A. Beneficial effects of *Lagenaria siceraria* (Mol.) Standley fruit epicarp in animal models. *Indian J of Exp Bio* 2008; 46(4): 234-42.
 21. Schneider CA, Rasband WS, Eliceiri KW. NIH Image to ImageJ: 25 years of image analysis. *Nat Methods* 2012; 9(7): 671-5.
 22. Frediani J, Naioti E, Vos M, Figueroa J, Marsit C, Welsh J. Arsenic Exposure and Risk of Non-Alcoholic Fatty Liver Disease (NAFLD) Among US. 2017.
 23. Abdelhalim MAK, Jarrar BM. Histological alterations in the liver of rats induced by different gold nanoparticle sizes, doses and exposure duration. *J Nanobiotechnology* 2012; 10(1): 5.
 24. Katzung BG, Masters SB, Trevor AJ. *Basic & clinical pharmacology*: Lange Medical Books/McGraw-Hill New York, NY, USA; 2004.
 25. Lefkowitz JH. *Scheuer's Liver Biopsy Interpretation E-Book*. 9 ed: Elsevier Health Sciences; 2015: 125-30.
 26. Panchal C, Sawale JA, Poul B, Khandelwal K. Hepatoprotective activity of *lagenaria siceraria* (Molina) Standley fruits against paracetamol induced hepatotoxicity in mice. *Int J Pharm Sci Res* 2013; 4(1): 371.
 27. Takawale RV, Mali VR, Kapase CU, Bodhankar SL. Effect of *Lagenaria siceraria* fruit powder on sodium oxalate induced urolithiasis in Wistar rats. *J Ayurveda Integr Med* 2012; 3(2): 75.
 28. Bvenura C, Afolayan AJ. The role of wild vegetables in household food security in South Africa: A review. *Food Res Int* 2015; 76: 1001-11.
 29. Gaim K, Gebru G, Abba S. The effect of arsenic on liver tissue of experimental animals (fishes and mice)-A review article. *Int J Sci Res* 2015; 5(5): 1-9.
-