

PIN TRACT CARE IN LOCALLY MADE EXTERNAL FIXATORS: A NEW TREATMENT PROTOCOL

Ibrahim Farooq Pasha, *Syed Riaz Zaidi, **Muhammad Ahmed, ***Abid Qureshi

CMH Rawalpindi, *CMH Quetta, **CMH Lahore, ***PIMS Islamabad

ABSTRACT

Objective: To calculate the frequency of pin tract infection in locally made external fixator pins using our set protocol.

Design: Descriptive study.

Place and Duration of Study: This study was conducted in Combined Military Hospital Sialkot and Combined Military Hospital Quetta over a period of 3 years and 6 months from May 2003 to November 2006.

Patients and Methods: A total of 451 Pin tracts from 50 external fixator were studied in forty nine patients. Inclusion criteria was all external fixator pins to the limbs excluding the skeletal tractions. Local Shanz screws and Kirschner wires of two different sizes were studied. The protocol was twice a day cleaning of pin tracts with povidone iodine (pyodine), twice a week soap and water bath with soft brushing where main wound was healed. At the time of removal of fixator the pin tracts were curetted and washed with 0.9% normal saline.

Results: Average age of the patients was 32.91 years most of them were young males, 23 (47%) in 3rd and 4th decade. Only 4 (8.1%) were females. Tibia was most commonly involved bone in 38 patients (77.5 %), while femur in 6 patients (12.2%) and foot and upper limb were affected in only a few cases. Road traffic accident was most common etiology in 33 (67.34 %) patients either presenting as open fractures or infected nonunion. Out of 451 pin tracts, 233 (51.66%) were locally made shanz screw half pins and 218 (48.33%) were locally made Kirschner wires full pins. The mean fixator time was about 17 weeks with maximum 48 weeks and minimum 7 weeks. Maximum follow up was 12 months minimum follow up was 3 months after removal of fixator. We had 25 (10.72%) minor pin tract infections of shanz screws, 5 (2.29%) minor pin tract infections of kirschner wires. We had to remove and change 3 (1.28%) Shanz pins. We had no true complication.

Conclusion: Standardizing a set protocol for pin tract care irrespective of wound type has shown excellent results with minimum morbidity. This simple method not requiring any expensive equipment can be tried in any hospital to avoid pin sores.

Keywords: Pin tract care, pin tract infection, external fixator.

INTRODUCTION

Pin tract infections remain one of the most troublesome complication of external fixators, in some cases compromising otherwise successful treatment [1]. Major complication is defined as any untoward occurrence to a patient which required additional surgical procedure and minor complications responded to non operative treatment [2]. Chronic osteomyelitis involving a pin track is a worrisome complication when it follows transcuteaneous insertion of skeletal pins. The infection becomes especially

distressing when it follows external fixation,

Correspondence: Maj Ibrahim Farooq Pasha, Classified Orthopaedic Surgeon, CMH Rawalpindi
Receive 07 Feb, 2007: Accepted 09 Feb 2009

since fixators are commonly applied to prevent osseous sepsis in the first place [3].

The different methods of pin tract care includes weekly dry dressing, daily pin site care with one half normal saline and one half hydrogen peroxide and weekly placement of chlorhexidine-impregnated discs [1]. Saleh

and Scot noted 26.6% [4] and we in our previous study done in services hospital Lahore noted 39% [5] and 42.2% [6] pin tract complications with mean fixator time of 13.1 months. C Sen noted 30% minor, 10% major with mean fixator time 8 months [7]. Aexl et al noted 13% pin problems with mean fixator time of 38 weeks [8]. Holbrook et al noted 21% pin tract complications with mean fixator time of 2.2 months.

The objective of our study was to calculate the frequency of infection in pin tract of locally made stainless-steel pins using our new pin tract care protocol. External fixators are used commonly in orthopedic surgery for various indications. To our knowledge no such study has ever been conducted in local set up. The results of the study will help develop the protocol for pin tract care of locally made stainless-steel pins. This protocol when applied in the local set up will reduce the frequency of pin tract infection.

PATIENTS AND METHODS

The study was conducted at department of orthopedics combined military hospital Sialkot and combined Military Hospital Quetta. We included pin tracts of patients requiring external fixators and excluded pin tracts of skeletal tractions and fixator time less than 4 weeks. Forty nine patients were included in study. The period of study was May 2003 to November 2006. The selection of patients was done by non-probability convenient sampling from orthopedic department. Detailed counseling about the nature, purpose of procedure was done and written consent was obtained in all cases. Then they were asked if they were interested to be included or not.

All patients were operated by a single surgeon. Locally made pins of four sizes 5mm and 3.5 mm Shanz screws and 1.8mm and 1.6 Kirschner wires mm were used. All pins were

inserted without pre-drilling. We inserted Shanz screws without pre drilling through cortical shaft bone and Kirschner wires through cancellous metaphyseal ends. After application of fixator antibiotics were given according to etiology from 3 to 21 days. Closed suction drains were placed for 3 days in clean cases, 10 to 14 days in open fractures and 14 to 21 days for infected cases. We did not routinely perform cultures except in patients requiring change of pins.

Protocol of this Study

1. Twice a day cleaning of pin tracts with povidone-iodine. They were advised to soak clean gauze in povidone-iodine (pyodine), then sling it around pins and clean tracts with to and fro motion all around.
2. Once main wound was healed patients were advised to wash fixator with soap and water using a soft tooth brush and take bath twice a week.
3. At the end of treatment fixator were removed and all pin tracts were curetted and washed with saline.

Pin tract infections were divided into minor (problems) when treated conservatively and major (obstacles) when treated surgically, and true complications (sequelae) which remained unresolved at the end of treatment [7]. Minor pin tract infections were treated with antibiotics, cleaning pin tracts thrice a day and breaking pin-skin adhesion by side to side movements. Major pin tracts infections were dealt with changing pins, curetting tracts and antibiotics. The frequency of minor, major and true complication was calculated.

RESULTS

A total of 451 pins tracts in 49 patients were studied Average age of the patients was 32.91 years. The age range was 2 to 65 years. Twenty three (47%) of them were in third and

fourth decade of life. We had predominantly 45 (92%) male patients, only 4 (8%) were females. Tibia was not commonly involved bone. In 38 (77.7%) patients external fixator was applied to 39 (78%) tibia and fibula, while femur was affected in 6 (12.2%), foot in 3 (6.1%), and one humerus and one ulna was affected. Left side involvement was noted in 28 (67.34%) cases. Road traffic accident was most common etiology in 33 (67%) patients either presenting as open fractures or infected nonunion. Out 451 pin tracts, 208 (46.12%) were 5 mm, 25 (5.54%) were 3.5 mm locally made shanz screw half pins and 194 (43.01%) were 1.8 mm, 24 (5.32%) were 1.6mm locally made Kirschner wires full pins. The mean fixator time was about 17 weeks with maximum 48 weeks and minimum 7 weeks. Maximum follow up was six months and minimum follow up three months after removal of fixator. We had 25 (10.72%) minor in tract infections of shanz screws, 5 (2.29%) minor pin tract infections of kirschner wires (table-1). We had to remove and change 3 (1.28%) Shanz screws. We had no true complication.

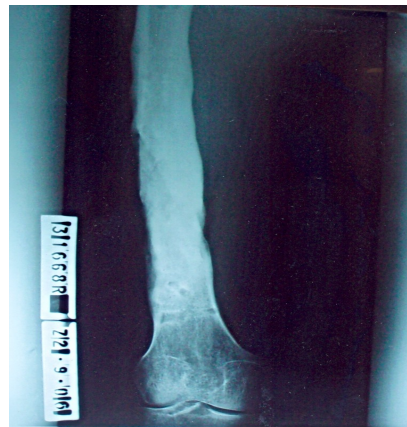

Fig. 4: Osteosynthesis in Infected Femur Nonunion (Bony Union)

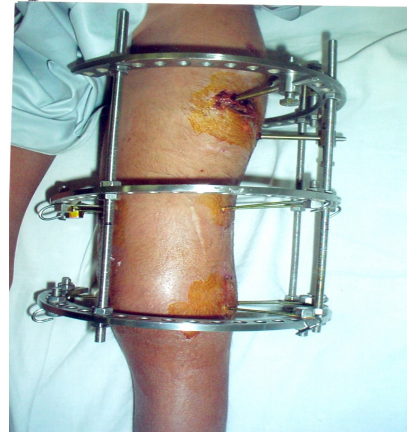


Fig. 5: Major Pin Tract Infection of Femur in Chronic Osteomyelitis




Fig. 6: Epiphyseal Distraction to Restore Leg Length

We had excellent results when fixators were applied to tibia (Fig. 1, 2). In 39 tibial fixators in 38 patients we had 9.24% minor and 0.57%major infections in 173 Shanz screws. While only 2.8% minor pin tract infection was found in 178 K-wires with mean fixator time of 17.97 weeks. Although we had

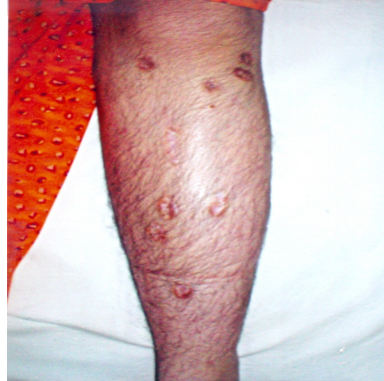


Fig. 1: Healed Pin Tracts in Tibia in Nonunion (Bony Union)

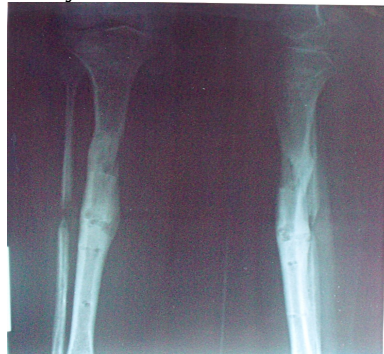


Fig. 2: Distraction Osteogenesis in Post Polio Patient (Leg Lengthening)

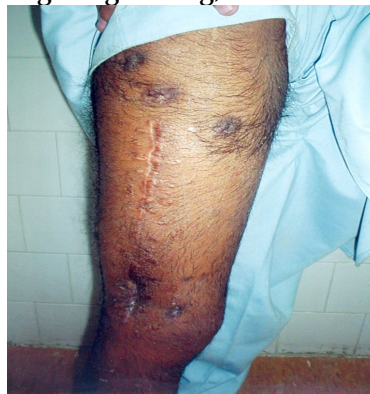

Fig. 3: Healed Pin Tracts in Infected Nonunion (Previous Surgery Scar Lateral Side of Thigh)

good results in femur fixators (Fig. 3, 4). We had 2 (66.6%) major problems when fixators were applied to femur (Fig. 5, 6). In 6 (12.2%) patients requiring femur fixators we had

21.05% minor and 5.26% major pin tract infections in 38 Shanz pins with mean fixator time of 20.6 weeks where in tibia fibula it was

Betadine solution [7]. We in our previous study done in services hospital Lahore noted 42% minor 12.8% major complication with

Table-1: Frequency of Infection in all Pins

Pin Size	Number of Pins	Pin Infection minor	Major	Frequency of in % Minor	Infection Major
5 mm shanz pin	208	19	2	9.1%	.96%
3.5 mm Shanz pin	25	6	1	24%	4.16%
1.8 mm K-wire	194	3	0	1.5%	0
1.6 mm K-wire	24	2	0	8.3%	0

9.2% and 0.6%.

DISCUSSION

The most common complication of external fixator is pin-track infection. Since operative trauma to the soft tissues and blood vessels is minimal with external fixators as compared to internal fixations they are extensively used in open and infected fractures [9]. Pin tract can be cleaned with daily dry dressing, cleaning with one half saline and one half hydrogen peroxide and placement of chlorhexidine-impregnated discs (Biopatch) [1]. Povidone iodine can also be used to clean pin tract [5]. Titanium and hydroxyapatite coated Shanz screws have been used to decrease pin tract infections [9].

Certain factors appear to be predictive of pin-track problems. Infection developed in patients who had pin-skin tension due to improper placement of the pins or failure to release the surrounding soft tissue rapidly. Similarly, pins traversing large quantities of soft tissue, such as those in the proximal part of the thigh or those traversing the posterior muscles, seemed to be more problematic than those in more subcutaneous locations [2]. Pin tract complications appear frequently when fixator time is long. Minimizing fixator time can decrease complications and increase patient acceptance to the procedure [10]. A study conducted by Scan reported 30% minor, 10% major and no true complications with mean fixator time 8 months. They clean pin tracts of international quality pins daily with

mean fixator time 13.12 months after cleaning pin tracts daily with povidone iodine [6]. Saleh and scot noted 26.6% [10] and Aexl et al noted 13% pin problems with mean 38 weeks but they did not describe pin tract care method. Holbrook et al noted 21% pin tract complications with mean 2.2 months fixator time but they did not mention pin tract care method [11]. Our method showed comparable results with hydrogen per oxide cleaning at Mount Sinai School of Medicine New York [12]

In ours present study we observed pin tract complications in 451 pin tract of locally made stain-less steel pin tracts. We had 25 (10.72%) minor pin tract infections of shanz screws, 5(2.29%) minor pin tract infections of kirschner wires. We had to remove and change 3 (1.28%) Shanz screws. We had no true complication with 17 weeks mean fixator time.

We observed more problems in patients requiring prolong treatment and pins used in femur. We had less pin tract infections because of following.

In most of our patients involved bone was tibia where pin tract problems of pins applied to subcutaneous surface are less.

Kirschner wires used at metaphyseal cancellous bone carry decreased infection.

Our fixator time was 17 weeks which is less than other observers [5-7].

Washing during bathing kept fixator clean that decreased the chances for bacteria to colonize in crevices of its components. Cleaning pin tract with pyodine soaked gauze with to and fro motion would break pin-skin interface adhesion.

On removal we curetted the pin tracts in all cases. Removing reactive or infected tissue from pin tracts resulted in no true complication in our study.

CONCLUSION

Standardizing a new and economical set protocol for pin tract care of locally made stainless-steel pins irrespective of wound type has shown excellent results with minimum morbidity as compared to previous published pin tract care methods. The patients requiring fixator treatment for prolong duration and over abundant soft tissue areas require intensive pin tract care. This simple method does not require any expensive equipment and support of hospital. This method can be tried in any hospital where external fixators are used to avoid pin tract complications.

REFERENCES

1. Kenneth AE, Nader P, Steven P, Jeffrey K, Rudi H and Kenneth JK. Treatment of External Fixation Pins About the Wrist: A Prospective, Randomized Trial. *The Journal of Bone and Joint Surgery (American)* 2006; 88: 349-354.
2. Velazquez RJ, Bell DF, Armstrong PF, Babyn, Tibshirani R. Complications of use of Ilizarov technique in the correction of limb deformities in children. *The Journal of Bone and Joint Surgery (American)* 1993; 75: 1148-1156.
3. Green SA, Ripley MJ. Chronic osteomyelitis in pin tracts. *The Journal of Bone and Joint Surgery (American)* 1984; 66: 1092-1098.
4. Saleh M, Scott BW. Pitfalls and complications of leg lengthening, the Sheffield experience. *Seminars in Ortho* 1992; 3: 207-22.
5. Ibrahim FP, Qayyum A, Khalid T, Irfan M, Abubakar S and Aftab A; Segment transport using unilateral fixator (Locally made Naseer Awais fixator). *The Journal of Pakistan Orthopedic Association* 1998; 10: (2): 10-21.
6. Ibrahim FP, Qayyum A, Abubakar S, Nusrat A and Aftab A; Treatment of bone loss nonunions with Ilizarov method. *The Journal of Pakistan Orthopedic Association* 1998; 10; (2): 22-31.
7. C Sen, L Eralp, T Gunes, M Erdem, V.E Ozden and M Kocaoglu; An alternative method for the treatment of non union of the tibia with bone loss. *The Journal of Bone and Joint Surgery (British)* June 2006; 88: 783-9.
8. Axel P, Gert M, Andreas D. Hydroxyapatite-coated schanz pins in external fixators used for distraction osteogenesis; A randomized controlled trial. *The Journal of Bone and Joint Surgery (American)* 2002; 84:1162-6.
9. Siddiqui KA, Mughal KM, Akhtar KM. External fixator in open and infected fractures. *The Journal of Pakistan Orthopedic Association* 1995; 1: 1-9.
10. LJ Prokuski and JL Marsh; Segment bone deficiency after acute trauma. The role of Segment transport. *The Orthopedic Clinics of North America* 1994; 25: 753-63.
11. Holbrook, JL, Swiontkowski, MF, Sanders R. Treatment of open fractures of tibial shaft: Ender nail versus External fixation. A Random, Prospective comparison. *The Journal of Bone and Joint Surgery (American)* 1989; 71: 231-1238.
12. Evans H. Karas, Lon S; Displaced pilon fractures an update. *Orthopedic clinics of north America.* 1994; 25: 651-64.