

## PATTERNS OF NASAL TRAUMA DURING CLOSE COMBAT TRAINING IN MILITARY TRAINING INSTITUTIONS

Saeed Ullah, Zaheer-UI-Hassan\*, Saleem Asif Niazi\*\*

Combined Military Hospital Quetta Pakistan, \*Combined Military Hospital Rawalpindi Pakistan, \*\*Pakistan Navy

### ABSTRACT

**Objective:** To identify the patterns and optimum management of nasal trauma during close combat training in military training institutions.

**Study Design:** Descriptive study.

**Place and Duration of Study:** The study was conducted in ENT department, Combined Military Hospital Abbottabad from August 2007 to July 2010.

**Material and Methods:** All patients who reported with nasal trauma during the training were included in the study. A total of 200 cases were studied. They were all males and their ages were between 16 to 24 years.

**Results:** The most common presentation of nasal trauma was epistaxis (92.5 %) while 7.5 % of cases were having no nasal bleed. Nineteen percent cases had external deviation of nasal axis while only 17% revealed inferior turbinate injury after initial treatment. Septal hematoma was present in 15% and was drained immediately in all cases. Nasal bone fracture was present in 36.5%. Anterior nasal packing was sufficient to stop nasal bleed in 80% cases of epistaxis while 20% cases of nasal bleed required post nasal packing.

**Conclusion:** The close combat techniques in army training institutions have increased the risk of nasal trauma and many different patterns of this trauma have been identified. Addressing the epistaxis, septal hematoma and fracture nasal bone reduces the chances of complications.

**Keywords:** Close combat military training, Epistaxis, External nasal deviation, Nasal trauma, Septal hematoma.

This is an Open Access article distributed under the terms of the Creative Commons Attribution License (<http://creativecommons.org/licenses/by/4.0>), which permits unrestricted use, distribution, and reproduction in any medium, provided the original work is properly cited.

### INTRODUCTION

The incidence of nasal trauma has increased significantly in the training institutions of army since the introduction of close combat training techniques. These techniques include the boxing, judo, karate, self defense mechanisms and training with personal weapons. Facial including nasal trauma has many presenting patterns. The injury may be an isolated nasal injury or a complexed one<sup>1</sup>. Fracture nasal bone, septal hematoma and laceration of the inferior turbinate of the nose may occur separately or in combination. Usually maxillary bone fractures are associated with the nasal injuries<sup>2</sup>. There is epistaxis and edema of the midfacial region and the initial presentation is always frightening. Epistaxis is almost always and must be addressed urgently

to prevent blood loss<sup>3</sup>. Some conditions like septal hematoma and external deformity due to isolated fracture nasal bone must be identity earlier to protect from permanent nasal deformity. There are three basic training institutions and a military training academy in Abbottabad. Training periods are a continuous process round the year and all patients are referred to CMH Abbottabad for specialized care. The rationale of this study was to identify the different patterns of nasal trauma which can occur during the military training. The aim also included the identification of optimum management of these injuries to prevent future complications.

### MATERIAL AND METHODS

This study was carried out in ENT department of Combined Military Hospital (CMH) Abbottabad from August 2007 to July 2010. Recruits who were undergoing military training in the army training centers and gentleman cadets of Pakistan Military Academy (PMA) were included in the study. A total of

**Correspondence:** Dr Zaheer UI Hassan, H.No-CB. 6, St. 6C, Sherzaman Colony Talsa Road Rawalpindi Pakistan (Email: [zaheerent@yahoo.com](mailto:zaheerent@yahoo.com))

Received: 02 Aug 2010; revised received: 04 mar 2015; accepted: 06 Mar 2015

200 cases were included in the study. They were all males and their ages were between 16 to 24 years. They were all actively involved in the military training and learning close combat techniques. All those patients who got nasal trauma due to other reasons were excluded from the study. All patients who sustained

**RESULTS**

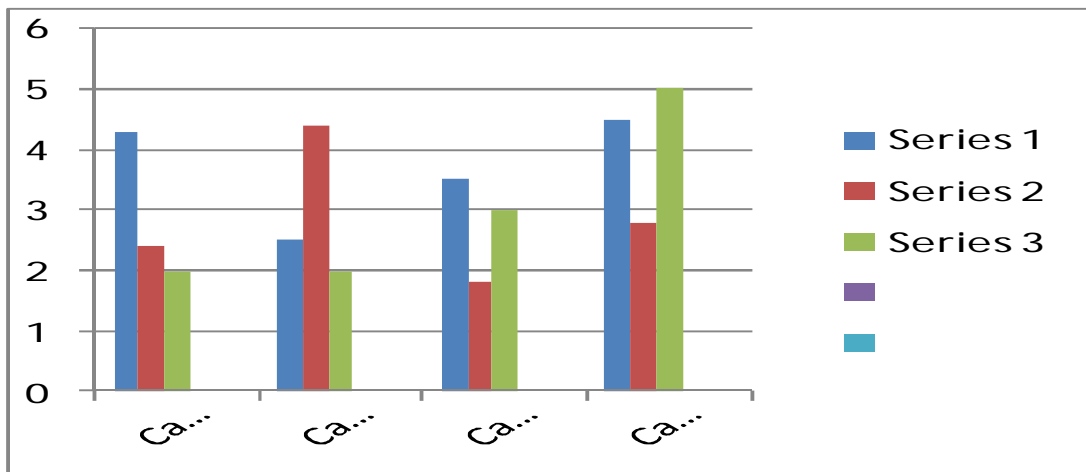
The most common presentation was epistaxis which was present in 92.5% of cases while 7.5% had no epistaxis at the time of presentation. Septal hematoma was present in 15% only. Nasal bone was fractured in 48% of

**Table-1: The type of trauma and treatment given to all the patients.**

S. No	Type of trauma	Treatment given	Number of cases
1.	Epistaxis	Anterior nasal packing	148
2.	Epistaxis	Posteriornasal packing	37
3.	Traumatic DNS	Septoplasty	18
4.	Ext Deviation of nose	Digital correction under L/A	38
5.	Septal heamatoma	Incision and drainage	30

nasal trauma during the training were examined by the attending doctor and then referred to ENT department. A unified approach was adopted for all patients. First they were examined by the ENT specialist and their epistaxis was addressed. Anterior nasal packing with simple vaseline gauze were done in all cases for 24 hours. Posterior nasal packing was reserved for those cases that had profuse bleeding or those not responding to anterior nasal packing. Isolated fracture of nasal bone

cases Graph-1. Among these 48% fractured cases only 38 cases had deviation of external nasal pyramid and significant deformity was present. While 81% presented with no significant deformity and only edema of midfacial region was present. Out of total (48%) cases of fracture nasal bone 36.5% cases were of simple, isolated in nature while 11.5% cases were complicated in nature and required general anesthesia for their management. Fifty two percent cases had no fracture associated



**Figure-1: The incidence of different patterns of nasal trauma in all categories.**

causing deformity was corrected digitally at initial presentation under local anesthesia. Septal hematoma was drained immediately in all cases. Traumatic DNS was corrected by septoplasty in all cases. X-Ray of nasal bones and paranasal sinuses were requested in selected cases.

with the nasal injury and only soft tissues injury was present. Traumatic deviation of nasal septum was present in 9% of cases only which was corrected either with closed reduction or septoplasty was carried out to correct the deviation table-1. In the soft tissues injury laceration of inferior turbinate were present in

34 cases. Anterior nasal packing with vaseline gauze was done in 80% cases of nasal bleed and was sufficient to stop the bleeding. Posterior nasal packing was required in 20% of nasal bleeding cases.

## DISCUSSION

A total of 200 cases of nasal trauma were studied. The most common presentation was epistaxis which was present in 92.5% of cases. Septal hematoma was present in 15% of cases. A similar study was conducted by Amir. et al<sup>5</sup> in Quetta in which 34 male patients were studied who sustained nasal injuries during boxing. The most common presentation in their study was the septal hematoma which was present in 58.33% of cases followed by fracture nasal bone which was present in 52.77% of cases. Our results are different from their study but their study sample was very small (34 cases) compared to our sample of 200 cases.

In our study isolated nasal fracture was present in 36.5% of cases while it was present in 23.2% cases in a study conducted by Eijaz. et al<sup>6</sup> in USA. Although their study was carried out on the general cases of trauma and the presence of associated nasal and facial injuries but it shows the occurrence of nasal fractures as a whole in assault cases and thus confirm our findings in close combat training.

Septal hematoma was present in 15% of cases in our study while its incidence was 30.4% in a study carried out by. Chukuezi and Owerri in Nigeria<sup>7</sup>. The incidence of septal hematoma in their study was traumatic and not specific to assault or close combat training. They studied 46 cases of septal hematoma.

In another study conducted by Zeilnik. et al<sup>8</sup> the incidence of post traumatic septal hematoma was found to be 0.9 %. The study

was carried out in children.

Post traumatic deviation of nasal septum was found in 9% of cases in our study while it was 24% in a study carried out in UK by Daniel and Raghavan<sup>9</sup>. They found that epistaxis was present in 76% of cases and external nasal deformity was present in 51% of the cases while in our study epistaxis was present in 92.5% and external nasal deformity was present in 19 % of the cases respectively.

## CONCLUSION

The introduction of close combat techniques in military training has increased the incidence of nasal and facial trauma. Different patterns of nasal trauma like epistaxis, septal hematoma and fracture nasal bone have been identified. A prompt and effective line of management in the shape of immediate drainage of hematoma, digital correction of deviated nasal bones and nasal packing reduces the likelihood of future complications and morbidity.

## CONFLICT OF INTEREST

The authors of this study reported no conflict of interest.

## REFERENCES

1. Ellis E III, Scott K. Assessment of patients with facial fractures. *Emerg Med Clin North Am*, 2000;18: 411-48
2. Cox AJ III, Nasal fractures – the details. *Facial Plast Surg*. 2000;16: 87-94,
3. Corry AJ III, Timothy C, James P. Management of acute nasal fractures. *Am Fam Physician*. 2004;70 (7): 1315-1320
4. Carvera J, Calderon R, Enrique 5, Bartolome M. Post traumatic hematoma and abscess in nasal septa of children. *Acta otorhinolaryngol Esp*. 2008;59 (3): 139-41
5. Amer SH, Bashir A, A Ashfaq, Amer E. Nasal trauma in amerture boxing. *Pak J Otolaryngol*, 2008; 24 (2): 9-11.
6. Aijaz A, Taylor D, Gregory L, Facial fractures an concomitant injuries in trauma patients *Laryngoscope* 2009;113 (1): 102-103
7. Chukuezi A, B Owerri Nasal septal hematoma in Nigeria. *J of laryngol and otol* 1992;106: 396-398
8. Zielnik J. B Olszeska S Rapiejko Treatment of nasal septal hematoma and abscess in children *Otolaryngol Pol*. 2008;62 (1): 71-5
9. Daniel M, Rhaghavan U, Relationship between epistaxis external nasal deformity and septal deviation following nasal trauma. *Emerg med J* 2000;22 (11): 778-9