

BILATERAL EMPHYSEMATOUS PYELONEPHRITIS

Asma Asghar, *Haroon Sabir Khan, **Sohail Sabir, *Shahid Mehmood Rana, Tassawar Hussain

Military Hospital Rawalpindi, *Armed Forces Institute of Urology, **Combined Military Hospital Multan

INTRODUCTION

Kelly and MacCullum reported the first case of pneumaturia from a gas-forming renal infection in 1898 [1]. Since then, several terms have been used to describe the condition, such as renal emphysema, pneumonephritis, and emphysematous pyelonephritis. Emphysematous pyelonephritis (EPN) is a rare, life-threatening condition, usually occurring in diabetic patients [1]. The most likely cause is glucose fermentation by Enterobacteriaceae, facilitated by poor glycaemic control. Impaired host defences caused by local factors such as obstruction and systemic factors such as diabetes, allows organisms with gas forming capability to produce carbon dioxide by fermentation of substrates such as necrotic material [1]. The overall mortality is 43%. In 1889, Muller first identified nitrogen, hydrogen, and carbon dioxide in a patient with pneumaturia [2,3]. Schainuck et al [1] proposed that fermentation products from tissue necrosis produced carbon dioxide. Three investigators analyzed the gas content, and all 3 demonstrated that the major components of the gas in EPN are nitrogen (60%), hydrogen (15%), carbon dioxide (5%), and oxygen (8%) [4]. Huang et al concluded that mixed acid fermentation is the mechanism of gas production based on the presence of hydrogen. Yang and Shen [5] indicated that gas-forming infections depend on rapid tissue catabolism and impaired transport of the end products at the inflammatory site. Although the bacteria release carbon dioxide, the final tissue equilibrium achieved by tissues and gas bubbles determines the final carbon dioxide content. Diabetic microangiopathy may also

contribute to the slow transport of catabolic products and lead to accumulation of gas. We describe the case in our institution.

CASE REPORT

A 63 year old male, known diabetic for 10 years and a known case of Ischemic Heart Disease for almost same duration, on regular treatment presented in a peripheral hospital with 4 days history of jerky movement of left half of body, fever, cough and urinary incontinence. Examination revealed bibasal crackles in chest; tenderness in right lumber region and upper motor neuron type weakness in left half of body. Investigations revealed Hb 15.1, TLC 17.8, platelet count of 28,000, numerous RBCs and Pus cells in urine. LFTs were normal. There was no ketonuria and DIC screen was negative. Serum urea and creatinine done on alternate days showed a rising trend with max serum urea 34.8 mmol/L and serum creatinine 1138 μ mol/L five days following admission. Hepatitis serology was negative. Culture of urine showed growth of Escherichia coli as well as candida species. CT scan Brain revealed right Parietal lobe infarct. USG Abdomen (fig.1) revealed air lucencies in subcapsular and cortical region of both kidneys suggesting bilateral emphysematous pyelonephritis. CT scan abdomen (fig.2) confirmed bilateral emphysematous pyelonephritis (R>L) with extension of air lucencies in perinephric spaces and prominence of Gerota's fascia bilaterally. Right kidney was at the verge of bursting.

Case was discussed with Urologist and Anesthetist but patient was unfit for surgery because of existing comorbid conditions. Aggressive conservative management was started including antibiotics (intravenous Tazocin) based on urine c/s and intravenous

Correspondence: Col Shahid Mehmood Rana, Classified Urologist/Commandant, Armed Forces Institute of Urology Rawalpindi.

Fluconazole alongwith alternate haemodialysis. He was also treated concomitantly for CVA and IHD. With these efforts patient started to respond, his renal functions started improving and he became dialysis independent after three weeks of his admission. Patient had made a remarkable recovery confirmed by an essentially normal USG abdomen and was discharged one month after the onset of symptoms.

DISCUSSION

Emphysematous pyelonephritis (EPN) is a rare parenchymal infection restricted exclusively to diabetics especially those with stasis of urine and incomplete bladder emptying. Raised serum and urine glucose levels with element of microangiopathy reducing renal perfusion and supply of antibiotics to kidneys making them more prone to infection by gas forming organisms. Diabetic neuropathy leading to an atonic bladder contributes to incomplete bladder emptying.

Patients with emphysematous pyelonephritis are typically very ill with circulatory/liver failure caused by sepsis. Patients often present with a clinical picture suggestive of severe acute pyelonephritis [6]. Symptoms most frequently include chills and fever (56%), flank pain (48%), lethargy and confusion (24%), toxic encephalopathy with shock or coma (16%), nausea and vomiting (16%), and abdominal pain with weakness and dysuria (7%). Occasionally, fever of unknown origin (18%) is the only presenting sign. When infection extends outside the perirenal space, crepitus may be palpated in tissues overlying the kidney [6]. Laboratory studies often reveal hyperglycemia, leukocytosis, and/or azotemia. Cultures demonstrate *Escherichia coli* in 68% to 70% [7,8,9] of all cases. *Klebsiella sp.* (9% to 15%), *Aerobacter aerogenes* (10%), *Proteus sp.* (5%), and *Pseudomonas sp.* have also been isolated from patients with emphysematous pyelonephritis, as have *Candida albicans* [10] and *Candida tropicalis* in rare cases. This

diagnosis is based on the presence of gas seen within the interstitium of the renal parenchyma. In most cases, a normal native kidney is involved unilaterally; involvement on left being more common than on the right [11], but in 10% of cases, the condition is bilateral [12]. The case being discussed is a diabetic patient with bilateral renal involvement, who presented with low-grade fever, cough, urinary incontinence and weakness of left half of body of upper motor neuron type, which is quite contrary to the typical presentations of the condition.

Radiological classification has been done by different workers

In 1984, Michaeli et al [13] suggested 3 stages of EPN.

Stage-I: Gas within the renal parenchyma or the perinephric tissue.

Stage-II: Presence of gas in the kidney and its surroundings.

Stage-III: Extension of gas through Gerota fascia or bilateral EPN.

In 1996, Wan et al [14] described 2 distinct types of EPN.

Type-I: (33% of patients) Characterized by parenchymal destruction with streaky or mottled parenchymal gas with an absence of fluid collection, which has a fulminant course and high mortality (66%).

Type-II: (66% of patients) characterized by renal or perirenal fluid collection with bubbly gas collection in the perinephric space or in the collecting system and a mortality rate of 18%. (According to Wan et al, the compromised immune state of the host leads to fulminant and dry-type EPN, which is fatal.)

Wan et al [14] have shown that serum creatinine levels are the most reliable predictors of the outcome in patients with EPN. By calculating likelihood ratios, patients with creatinine levels greater than 1.4 mg/dL and platelet counts of 60,000/mm³ or less are

at high risk. The posttest probability of death increases from 69% to 92% in type I EPN and 18% to 53% in type II EPN. Patients with creatinine levels of 1.4 mg/dL or less and platelet counts greater than 60,000/mm³ are at much lower risk. The posttest mortality risk in these patients decreases from 69% to 27% and from 18% to 4% for type I EPN and type II EPN, respectively.

In 2000, Huang et al [15] modified the staging proposed by Michaeli et al.

Class-I: Gas confined to the collecting system.

Class-II: Gas confined to the renal parenchyma alone.

Class-III(a): Perinephric extension of gas or abscess.

Class-III(b): Extension of gas beyond the Gerota fascia.

Class-IV: Bilateral EPN or EPN in solitary kidney.

However, these classifications are not comparable.

Diagnosis in our patient was confirmed both by the ultrasound and CT scan of abdomen placing disease in radiological class 4 of Huang et al and stage III of Michaeli et al. Cultures of urine demonstrated *Escherichia coli* which is found in 68 to 70 % [7,8,9] of all cases. Platelet count of less than 60,000 and serum creatinine level of more than 1.4 mg/dL are considered to be poor prognostic indicators and our patient had both. Therefore patient is a high-risk case from both radiological and clinicopathological criteria.

Management of this condition has traditionally been aggressive and surgery has been considered mandatory. Many of the earlier series have stressed the very high mortality rate (75%) and the need for urgent nephrectomy [16]. However, this is itself a hazardous intervention in a septic patient with unstable circulatory or liver failure. In the case of bilateral renal disease, the patient requires long-term dialysis. With the advent

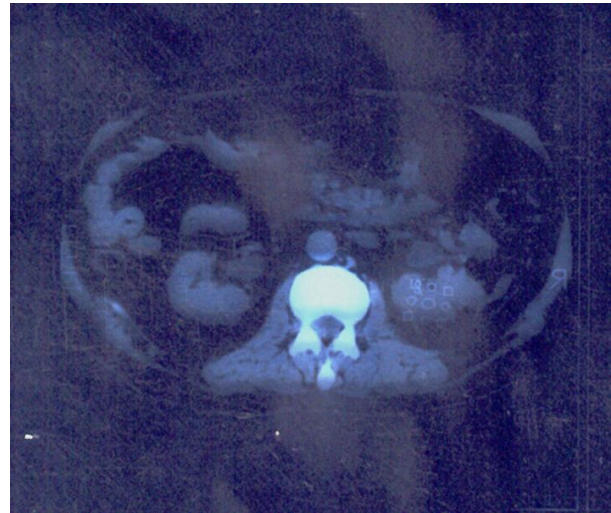


Fig. 1: CT scan brain revealed right parietal lobe infarct.

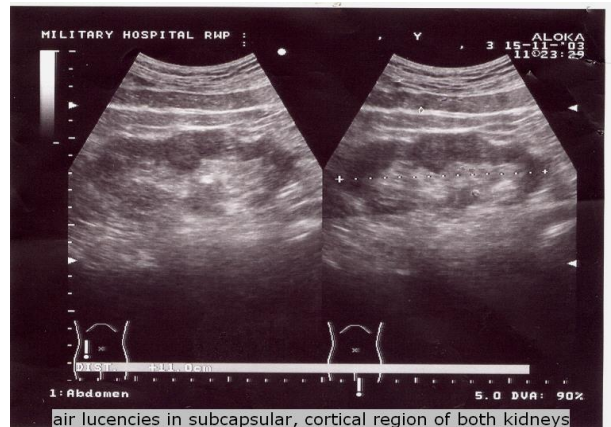


Fig. 2: Air Lucencies in subcapsular, cortical region of both kidneys.

of CT scanning, more powerful antibiotics, and better access to life support, an alternative medical approach to radical surgery has emerged in the form of intravenous antibiotics, and percutaneous drainage. Immediate nephrectomy is mandatory in patients with poorly controlled sepsis.

Although Ideal management of these patients worldwide is a combination of surgery in the form of nephrectomy and aggressive antibiotic therapy, our patient was declared unfit for surgery because of comorbid conditions and it was decided to continue the conservative management in the form of broad spectrum antibiotics keeping in view the report of culture and sensitivity of

urine and frequent sessions of haemodialysis, to which the patient responded and soon recovered completely evident by the follow up ultrasound and reports of renal and hematological profile.

CONCLUSION

This case is a classical example of a rare complication of diabetes treated successfully by medical treatment alone. This condition can be life threatening in the absence of prompt diagnosis and an early start of treatment with a mortality rate as high as 78 % universally [16]. Availability of modern imaging modalities like ultrasound and CT scan, lab facilities made it possible to diagnose the condition at a stage where it was still amenable to conservative management. Presence of advanced facilities of hemodialysis at our Nephrology unit made it a success story.

REFERENCES

1. Kelly HA, MacCullum WG: Pneumaturia. *JAMA* 1998; 31: 375-81.
2. Muller F: Berlin Klin. *Wchnschr* 1889; 26: 889. Cited by Kwong [6].
3. Alexander JC: Pneumonephrosis in diabetes mellitus: case report. *J Urol* 1941; 45: 570.
4. Huang JJ, Chen KW, Ruaan MK: Mixed acid fermentation of glucose as a mechanism of emphysematous urinary tract infection. *J Urol* 1991; 146(1): 148-51.
5. Yang WH, Shen NC: Gas-forming infection of the urinary tract: an investigation of fermentation as a mechanism. *J Urol* 1990; 143(5): 960-4.
6. Kwong T, Chiu G, Smith RBW. Emphysematous pyelonephritis: case report. *N Z Med J* 1990; 103: 242-3.
7. Bohlman ME, Sweren BS, Khazan R, et al. Emphysematous pyelitis and emphysematous pyelonephritis characterized by computed tomography. *South Med J* 1991; 84: 1438-43.
8. Klein FA, Vernon-Smith MJ, Vick CW III, Schneider V. Emphysematous pyelonephritis: diagnosis and treatment. *South Med J* 1986; 79: 41-46.
9. Shokeir AA, El-Azab M, Mohsen T, El-Diasty T: Emphysematous pyelonephritis: a 15-year experience with 20 cases. *Urol* 1997; 49(3): 343-6.
10. Sultana SR, McNeill SA, Phillips G, Bryne DJ: Candida pneumaturia. *J R Coll Surg Edinb* 1998; 43: 198-9.
11. Tang HJ, Li CM, Yen MY, et al: Clinical characteristics of emphysematous pyelonephritis. *J Microbiol Immunol Infect* 2001; 34(2): 125-30.
12. Zabbo A, Montie JL, Popowniak KL et al: Bilateral emphysematous pyelonephritis. *Urol* 1985; 25: 293-6.
13. Michaeli J, Mogle P, Perlberg S et al: Emphysematous pyelonephritis. *J Urol* 1984; 131(2): 203-8.
14. Wan YL, Lo SK, Bullard MJ et al: Predictors of outcome in emphysematous pyelonephritis. *J Urol* 1998; 159(2): 369-73.
15. Huang JJ, Tseng CC: Emphysematous pyelonephritis: clinicoradiological classification, management, prognosis, and pathogenesis. *Arch Intern Med* 2000; 160(6): 797-805.
16. Ahlering TC, Boyd SD, Hamilton CL et al. Emphysematous pyelonephritis: a five year experience with 13 patients. *J Urol* 1985; 134: 1086-8.